

professional skills 1  
3rd year  
semester 6  
radiography

# HYSTEOSALPINGOGRAPHY

Uz. Rehab musa

Tel. 0123179794

# HYSTEOSALPINGOGRAPHY :

Is radiological contrast examination of uterus and fallopian tubes .

A hysterosalpingogram is used to evaluate infertility. ►

**Contrast** is injected via a catheter or cannula into the uterus to outline the uterine cavity and to delineate the fallopian tubes.

A normal study will show contrast spilling out of the tubes into the pelvis. ►

## PREPARATION :

The test must be performed within ten days of the onset of menstruation to ensure there is no chance of pregnancy. ►

## TECHNIQUE : ►

Plain film is taken . ►

The patient is placed in a standard gynae position ( frog ► position : supine with flexed hips and knees ) on the edge of the screening table. The entrance to the vagina is cleansed with an antibacterial solution. A vaginal **speculum** is inserted to obtain a view of the cervix.

A small gauge rubber catheter or a **cannula** is inserted ►  
into the cervical canal.

After repositioning, ensure that no air bubble injected ►  
which can mimic filling defect in the cavity ( e.g. fibroid)  
**contrast is injected** and several **films** obtained.

Following the procedure some discharge and minimal ►  
bleeding may occur. Although uncommon, increasing  
discharge, pain or fever could indicate a developing  
infection requiring treatment with antibiotics.

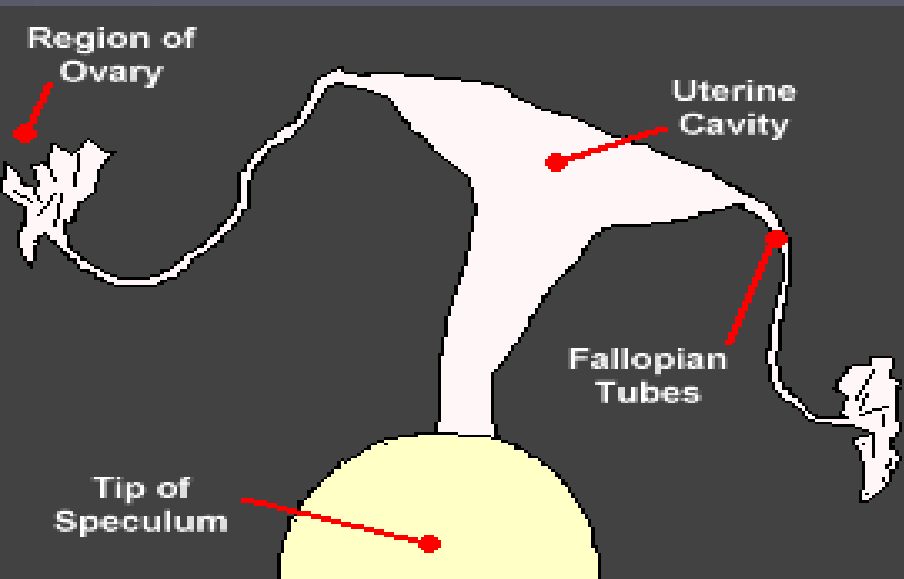
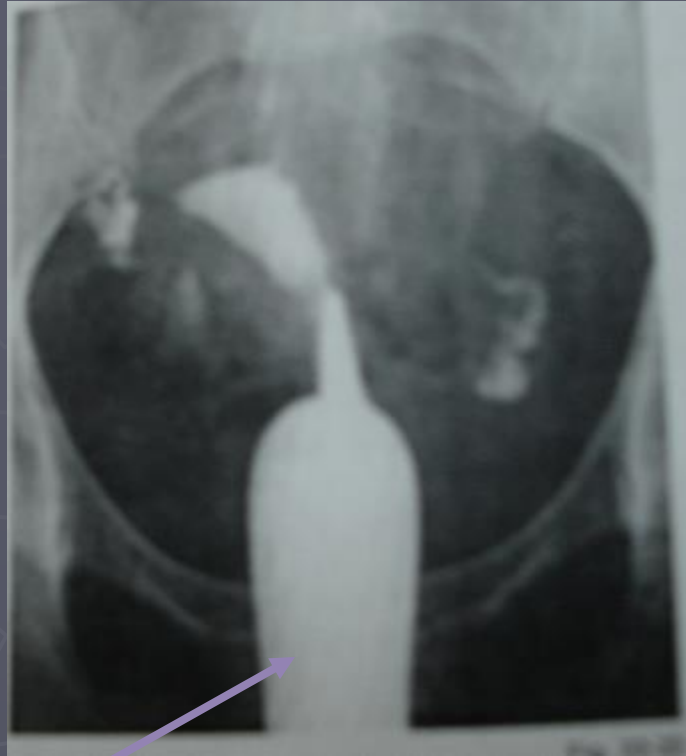

Diagram illustrate female reproductive system seen in HSG

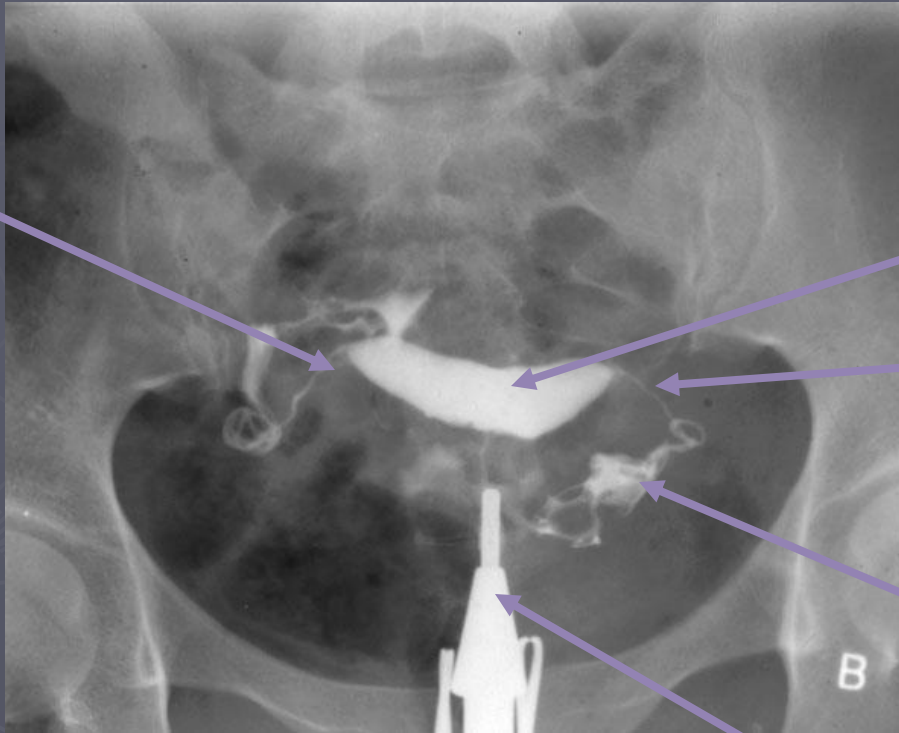


speculum



•hysterosalpingogram

Rt fallopian tube

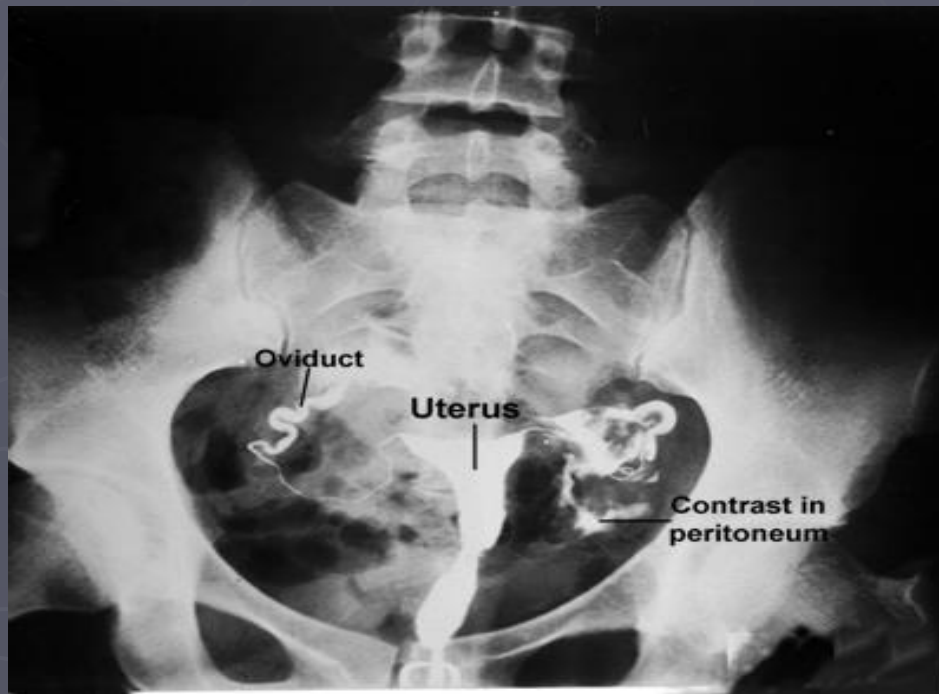


uterine cavity

Lt fallopian tube

Contrast spilling to  
The peritoneum

cannula



Oviduct :other name for fallopian tube



