

NATIONAL UNIVERSITY, SUDAN [NUSU]
FACULTY OF MEDICINE AND SURGERY [FOMS]



Department of Pathology

Practical Pathology Manual and Atlas

First edition 2022

INTRODUCTION

This manual is prepared to help undergraduate students to acquire essential practical knowledge in diagnostic pathology. Divided into ten chapters, this useful manual discusses general pathology i.e. principles of disease II, Haematology and systemic pathology.

This manual offers updated images for topics of current clinical significance including surgical pathology, acute and chronic haematological malignancies and benign haematological diseases. These images will help students in quick review and self-assessment of the pathology subject and succinctly supplementing pathology text books. It will provide a helpful study material for students and help them review the subject for examinations.

Mai Abass

Head of the pathology department

Chapters:

chapter	Title	Code	Semester	Page No
1.	Principles of disease-II	ME-DIS-212 B	3	5
2.	Blood and lymph	ME-HEM-316	3	25
3.	Cardiovascular system	ME-CVS-214	3	39
4.	Respiratory system	ME-RES-213	3	45
5.	Musculoskeletal system	ME-MSK-223	4	57
6.	Gastrointestinal system	ME-GIT-225	4	62
7.	Urinary system	ME-URO-313	5	86
8.	Endocrine system	ME-ENDO-315	5	94
9.	Reproductive system	ME-REP-314	5	101
10.	Nervous system and special senses	ME-CNS-323	6	118

Contents:

- 1- The light microscopic changes seen in necrosis with relevant clinical examples**
- 2- Granuloma as part of chronic inflammation**
- 3- The morphologic types of inflammation (serous, fibrinous and ulcer)**
- 4- Abscess**
- 5- Calcification**
- 6- Types of blood cell**
- 7- The haematopoiesis**
- 8- Types of anaemias**
- 9- Aplastic anaemia and laboratory finding**
- 10- Haematological malignancies**
- 11- Coagulation disorders**
- 12- Neoplastic and non-neoplastic pathologies of male and female reproductive organs and the breast.**
- 13- Diseases of urinary system**
- 14- Common disease of nervous system and the pathological changes**
- 15- Pathology of muscle, joint and bone**

Abbreviations:

AFP: Alpha fetoprotein

ALL: Acute lymphoblastic leukemia

AML: Acute myeloid leukemia

ANCA: Antineutrophil cytoplasmic antibody

CML: Chronic myeloid leukemia

CMV: Cytomegalovirus

DNA: Deoxyribonucleic acid

EBV: Epstein-Barr virus

ELISA: Enzyme-linked immunosorbent assay

FISH: Fluorescence in situ hybridization

G/A: Gross appearance

GBM: Glomerular basement membrane

GIT: Gastro intestinal tract.

GN: Glomerulonephritis

H₂O₂: Hydrogen peroxide

hCG: Human chorionic gonadotropin

HHV 8: Human herpesvirus 8

HIV: Human immunodeficiency virus

HLA: Human leukocyte antigen

HPV: Human papillomavirus

M/E: Microscopic Examination.

MPGN — Membranoproliferative glomerulonephritis

PCR — Polymerase chain reaction

RA — Rheumatoid arthritis

RBC — Red blood cells

RNA — Ribonucleic acid

SLE — Systemic lupus erythematosus

TGF — Transforming growth factor

TNF — Tumor necrosis factor

TSH — Thyroid stimulating hormone

Chapter One

Principal of diseases

Learning Outcomes Principle of disease:

- The gross and light microscopic seen in tissue adaptive responses to injury.
- The light microscopic changes seen in necrosis with relevant clinical examples.
- Granuloma as part of chronic inflammation
- The morphologic types of inflammation (serous, fibrinous and ulcer)
- Abscess: lung abscess
- Calcification

Materials:

- Images of gross pathological changes seen in different organs.

Cellular adaption to injury:

Homeostasis:

When a cell is able to handle the normal physiologic demands, maintaining a steady state it is said to be in homeostasis.

Cellular adaptation to injury:

Excessive physiologic stress or pathologic stimuli results in reversible functional and morphologic changes, leading a normal cell into an altered, but steady state called cellular adaptation.

Adaptive response may be in the form of:

1. Hypertrophy
2. Hyperplasia
3. Atrophy
4. Metaplasia

Hypertrophy:

Increase in the size of the tissue or organ due to increase in the size of cells.

Causes: Increased functional demand/workload.

Physiological hypertrophy:

- Hypertrophy of skeletal muscle in athletes.
- Hypertrophy of smooth muscle: uterus during pregnancy from estrogenic stimulation.

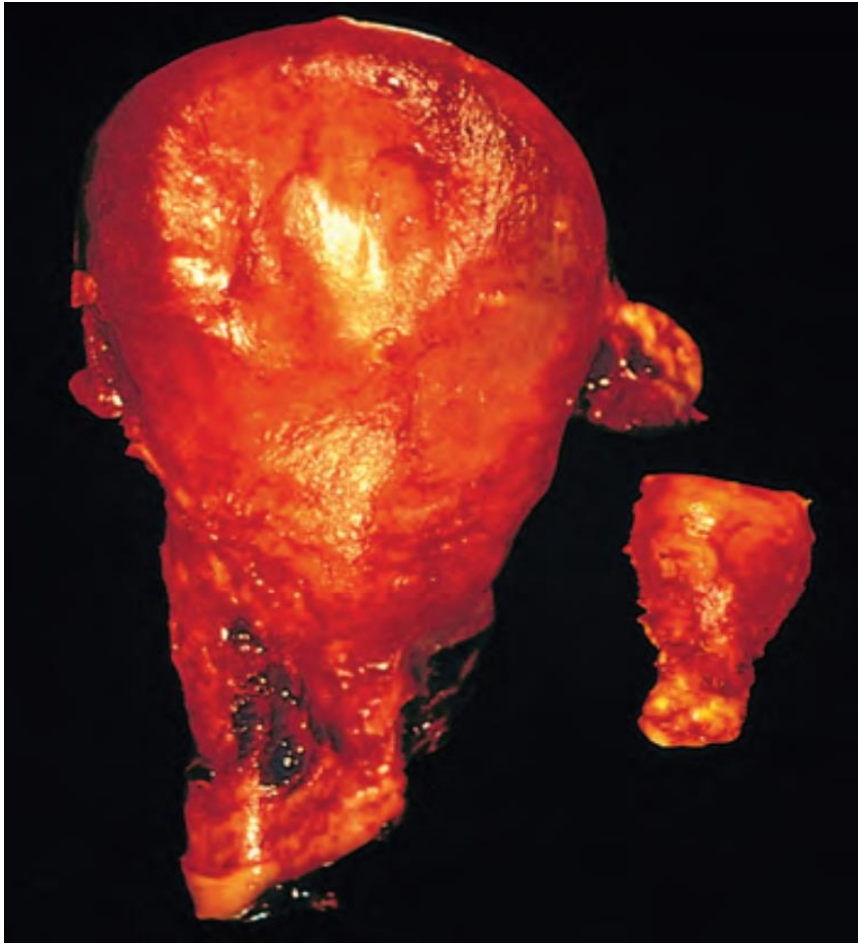


Figure1.1: G/A physiological hypertrophy of uterus: Normal uterus (Right) and uterus of pregnant lady (Left).

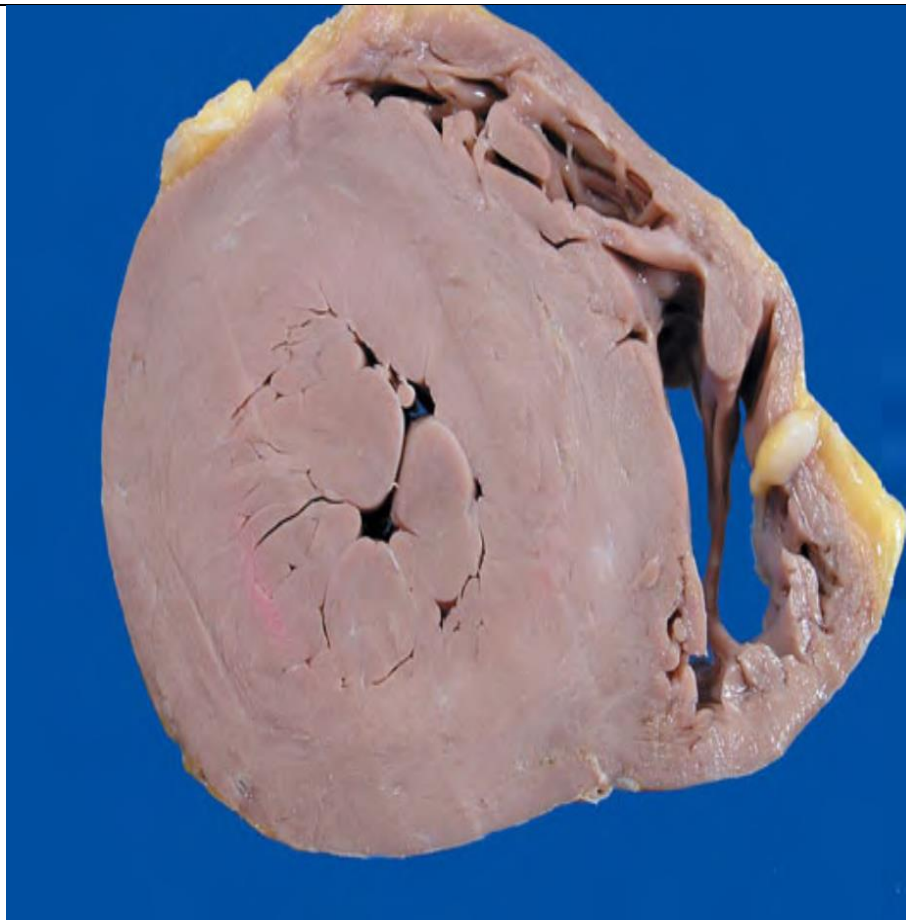


Figure 1.2. G/A pathological hypertrophy of left ventricle in patient with hypertension

Hyperplasia:

- Is the increase in the number of cells in an organ or tissue, resulting in increased size/mass of the organ or tissue?

A. Physiological hyperplasia: Hormonal stimulation or as compensatory process.

— Hyperplasia due to hormones: hyperplasia of the uterus during pregnancy.

— Compensatory hyperplasia: in liver following partial hepatectomy.

B. Pathological hyperplasia: e.g. excess endocrine stimulation or chronic injury/irritation.

Excessive hormonal stimulation: endometrial hyperplasia (due to estrogen) and benign prostatic hyperplasia (due to androgens).

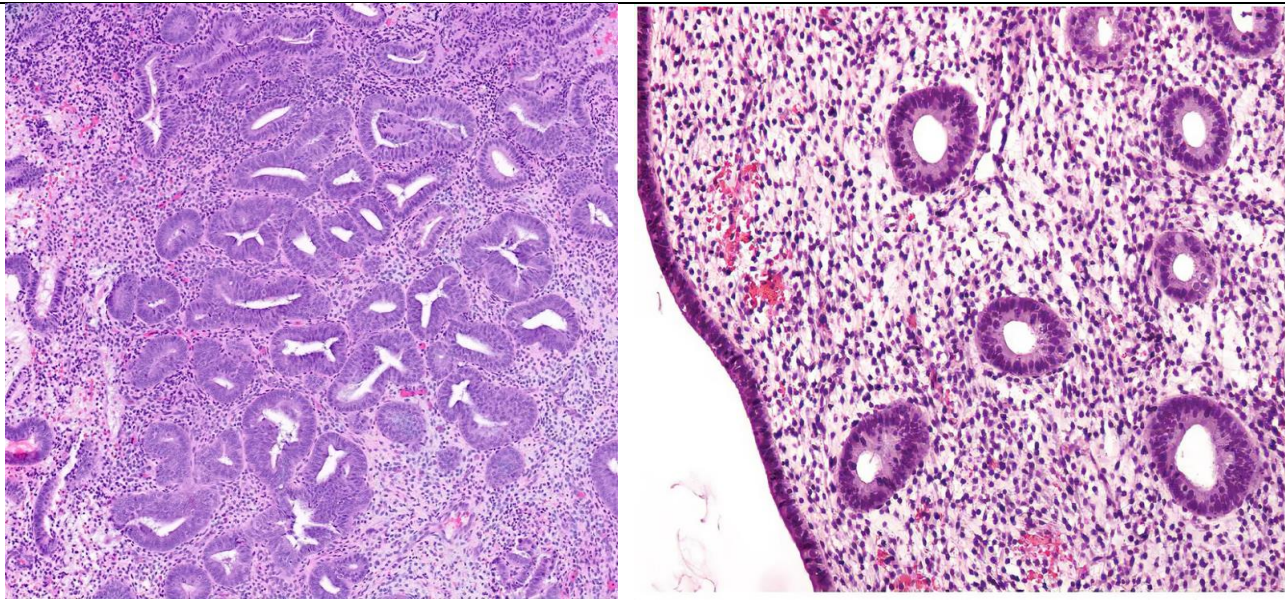


Figure 1.4. Endometrial hyperplasia: Normal endometrium (left)endometrial hyperplasia (right)

Metaplasia:

Metaplasia is a reversible change in which one adult cell type is replaced by another adult cell type.

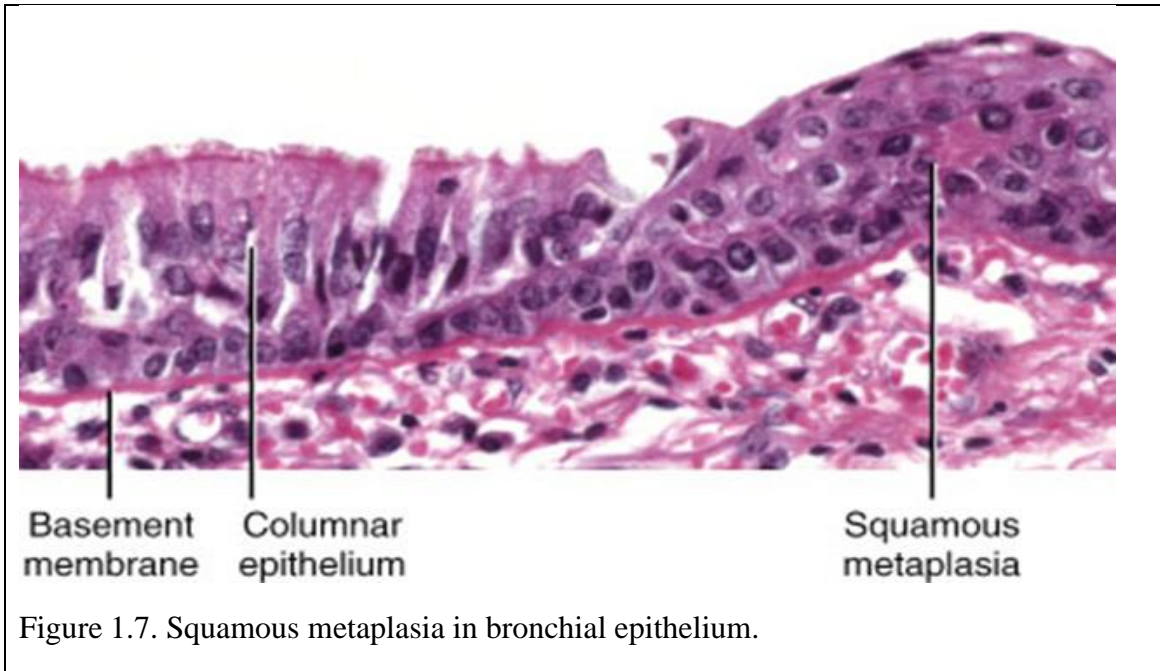


Figure 1.7. Squamous metaplasia in bronchial epithelium.

Cellular Response to Injury:

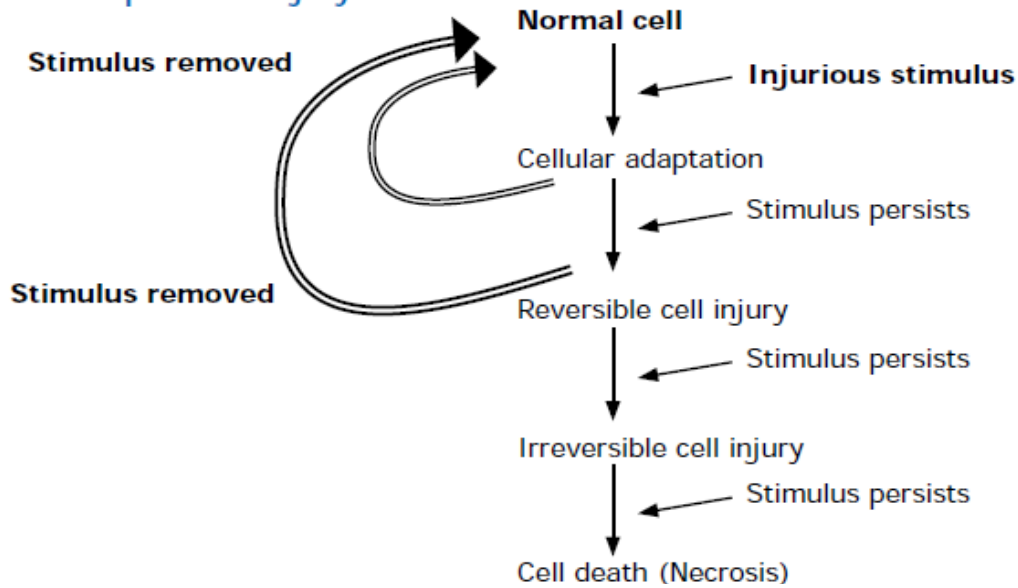


Figure 1-8:

Necrosis:

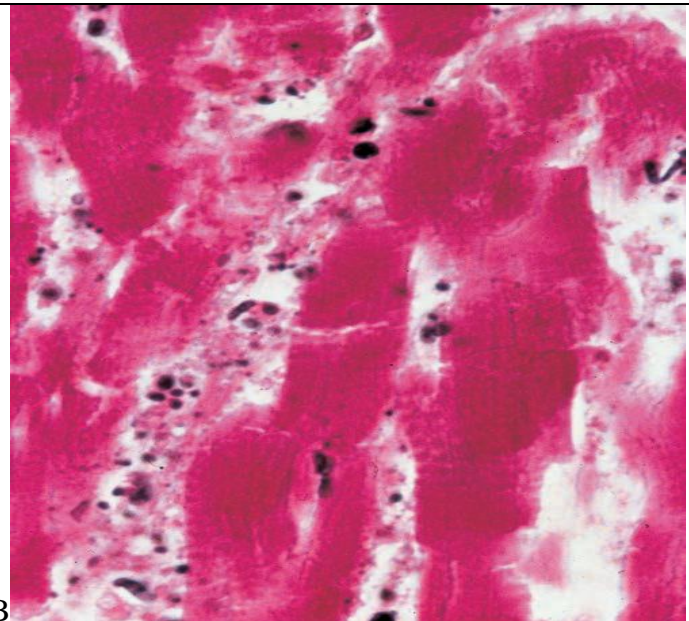
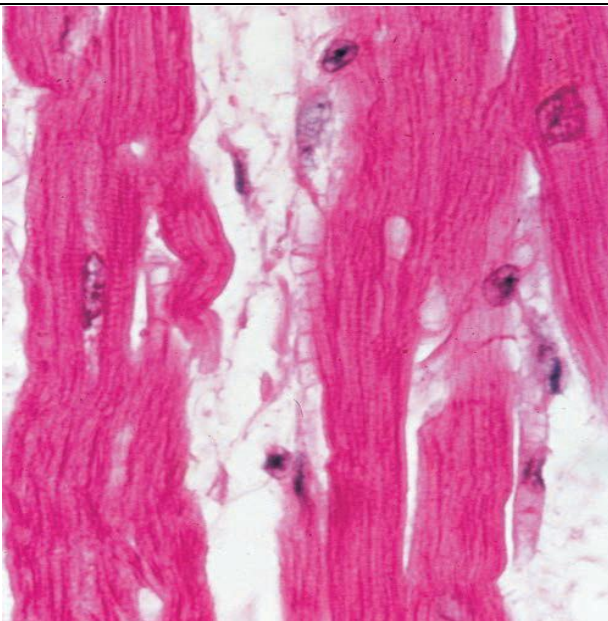
Morphological changes indicative of cell death in a living tissue following harmful injury.

Types of necrosis:

- 1- Coagulative necrosis:** most common type of necrosis caused by irreversible cell injury, most often from sudden cessation of blood supply or ischemia (infarction). Coagulative necrosis are seen in infarcts of the kidney, heart and spleen.

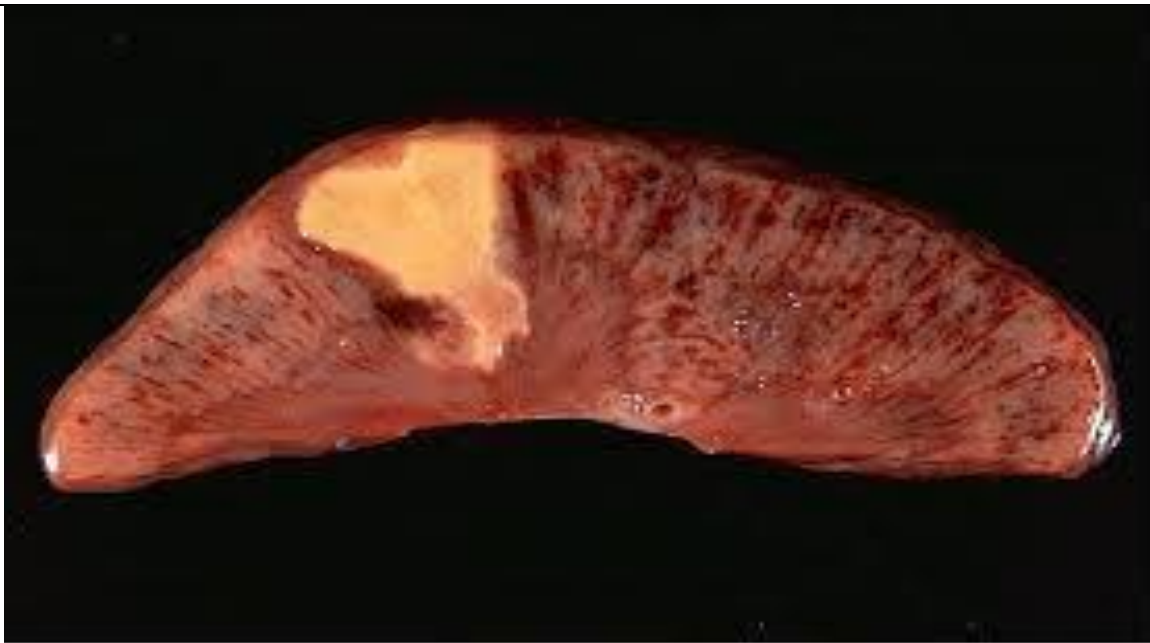

Figure-1-9 G.A: Renal infarcts, they are pale or and wedge-shaped with base resting under the capsule and apex pointing towards the medulla. The cut surface of renal infarct in the initial 2 to 3 days is red and congested but by 4th day the center becomes pale yellow. At the end of one week, the infarct is anemic and depressed below the surface of the kidney



A

B

Figure 1-9. M/E: Comparison of normal cardiac muscle fibers A, with necrotic fibers. B,

The hallmark of coagulative necrosis is that architectural outlines of tissue may be preserved though all cellular details are lost.

Note the fragmentation of fibers, the loss of nuclear staining, and the fragmented bits of nuclear debris

2- **Liquefactive necrosis** results commonly due to bacterial infections which constitute powerful stimuli for release of hydrolytic enzymes causing liquefaction. The common example is infarct of the brain

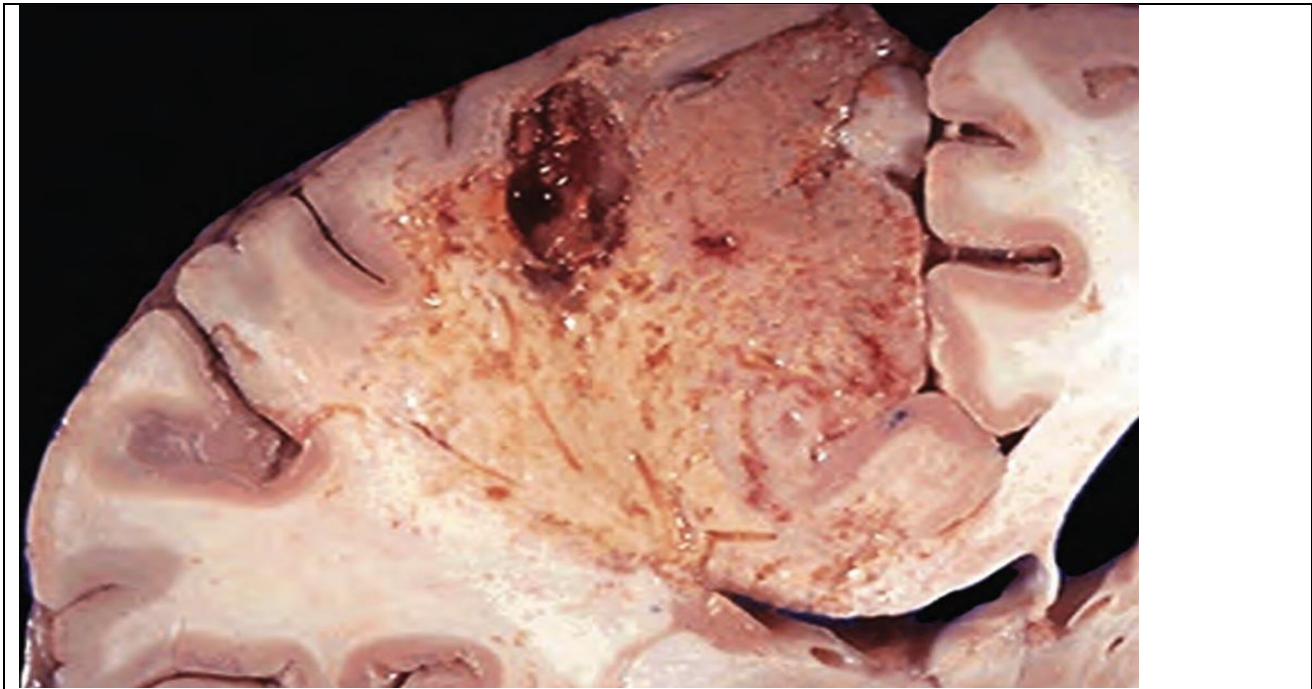

Figure1-10- G/a: Affected area of the brain is soft with liquefied center containing necrotic debris.

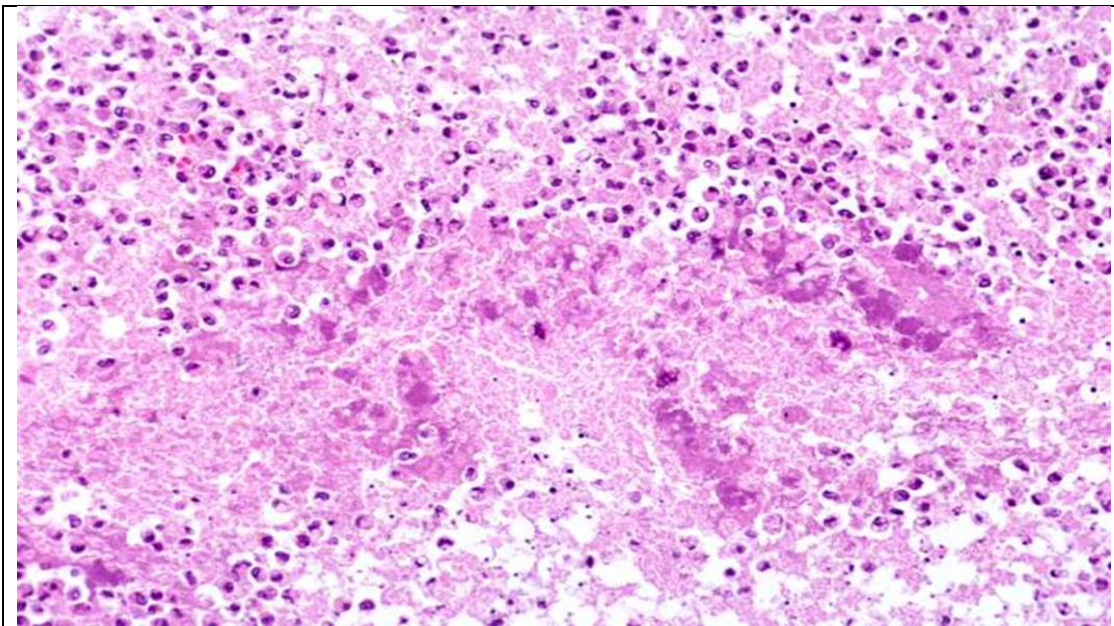


Figure 1-11- M/E: Liquefactive necrosis: abscess contains necrotic cell debris and neutrophils

3- **Caseous necrosis:** is a distinctive form of necrosis encountered in the foci of tuberculous infections. It combines the features of both coagulative and liquefactive necrosis. Tuberculous lymphadenitis is a common example of caseous necrosis.

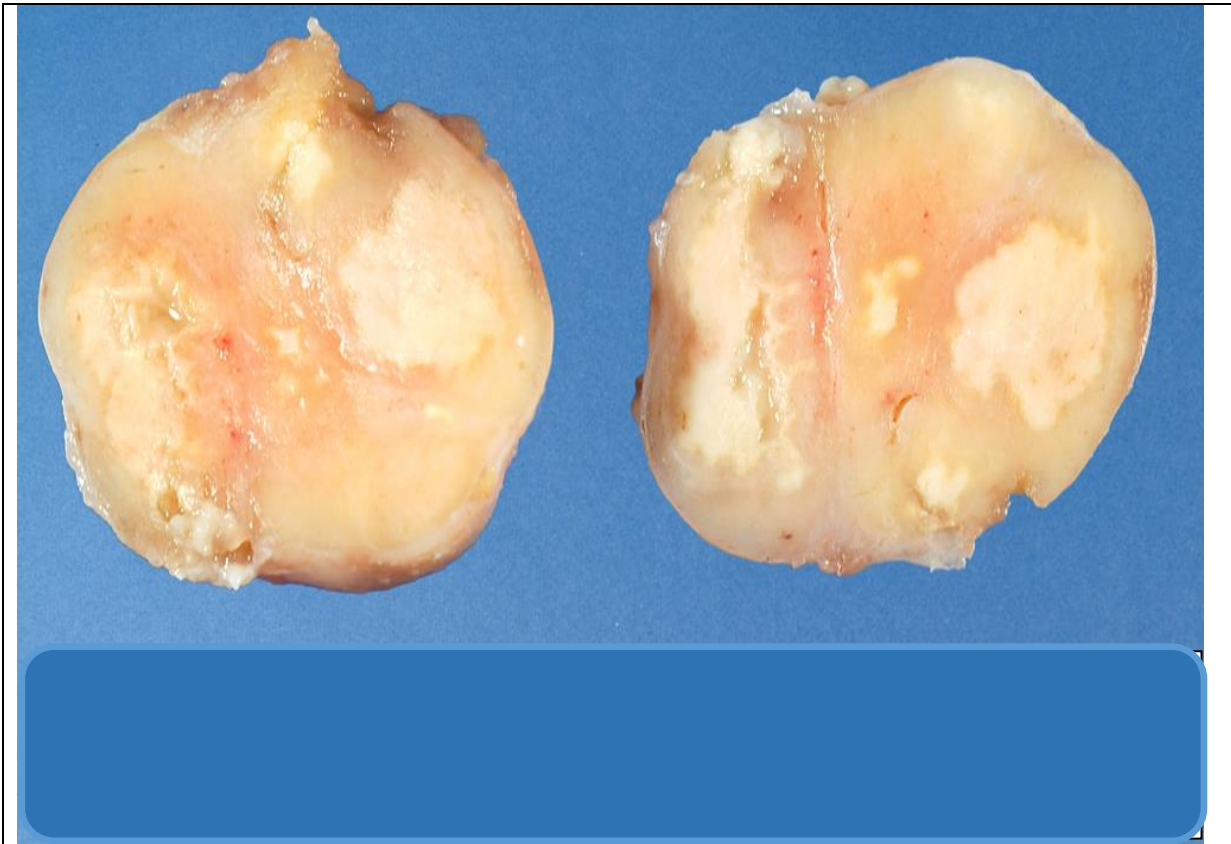


Figure 1-12- G/A: The cut surface of lymph node shows characteristic map-like areas of whitish granular, soft necrotic material resembling dry cheese

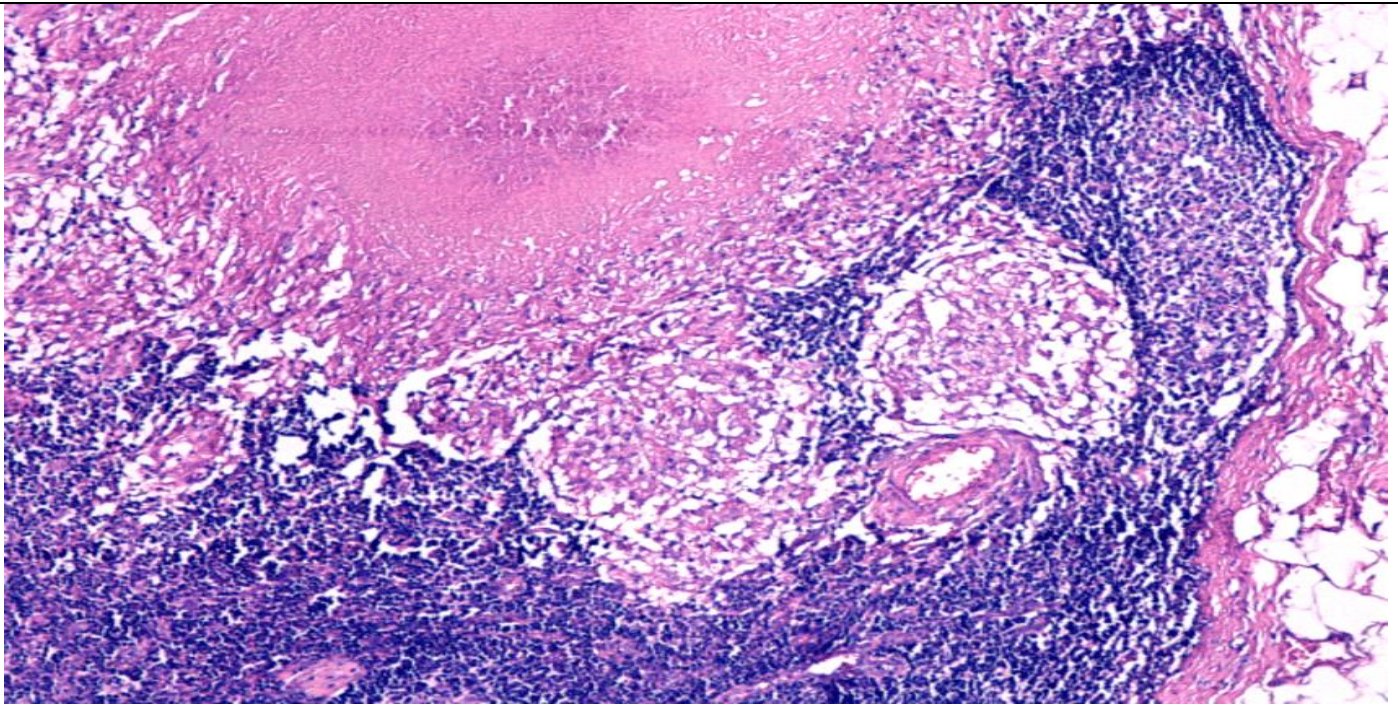


Figure 1-13- M/E: Tuberculous lymphadenitis. Necrotic foci composed of eosinophilic, granular debris, surrounded by granulomatous inflammatory reaction consisting of epithelioid cells with giant cells of langhans' type and peripheral caught of lymphocytes.

4- **Enzymatic fat** necrosis is the term used for focal areas of destruction of fat.

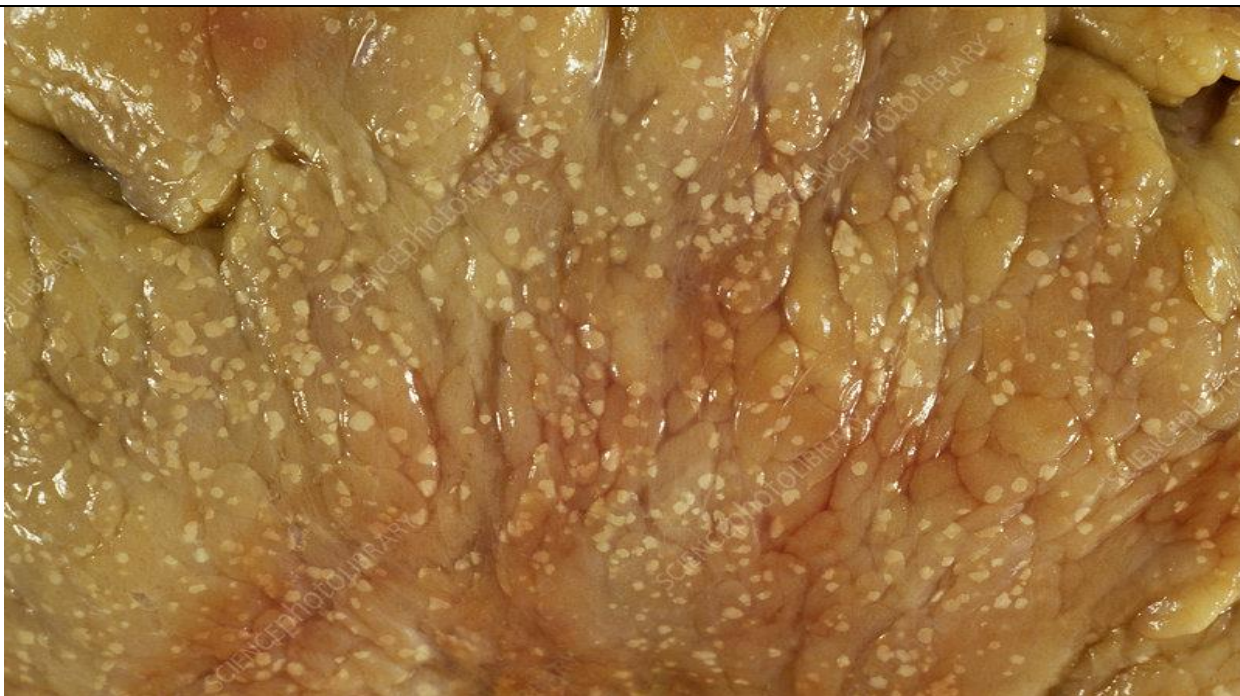


Figure 1-14 G/a: fat necrosis appears as yellowish-white firm deposits. Formation of calcium soaps imparts the necrosed foci firmer and chalky-white appearance

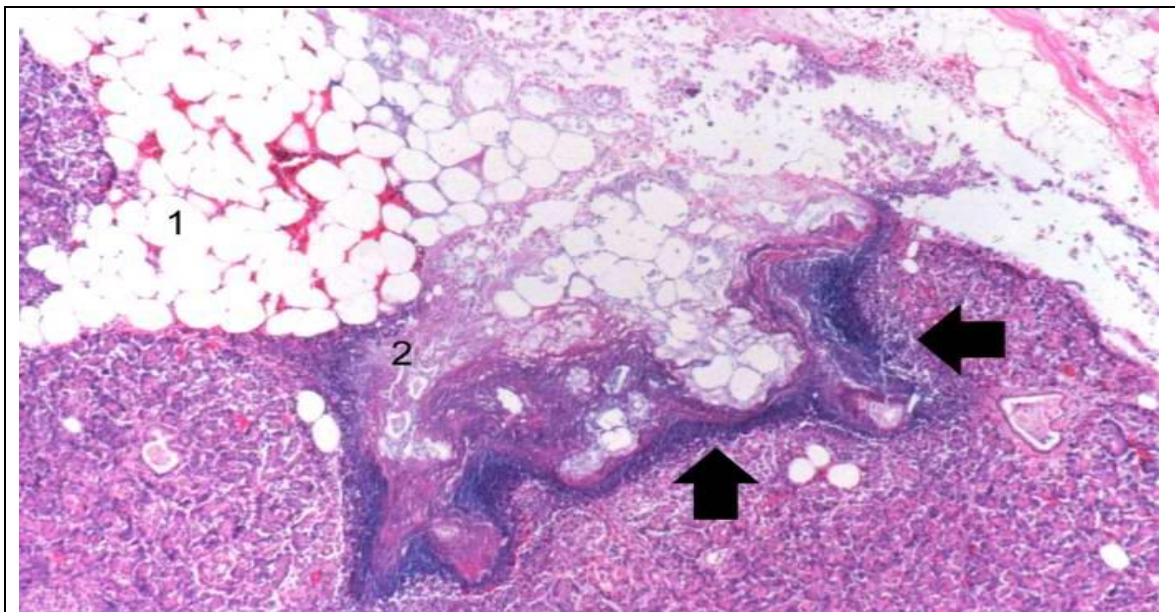


Figure 1- 15- M/E: Necrotic fat cells have cloudy shadowy appearance. There are foci of calcium soaps identified in the tissue sections as amorphous, granular and basophilic material. (arrows) There is surrounding zone of inflammatory reaction.

Fibrinoid necrosis:

- Seen in hypertension and in immune reactions involving blood vessels, Fibrin leaked out of vessels, characterise by bright pink amorphous appearance- Fibrinoid (fibrin like).

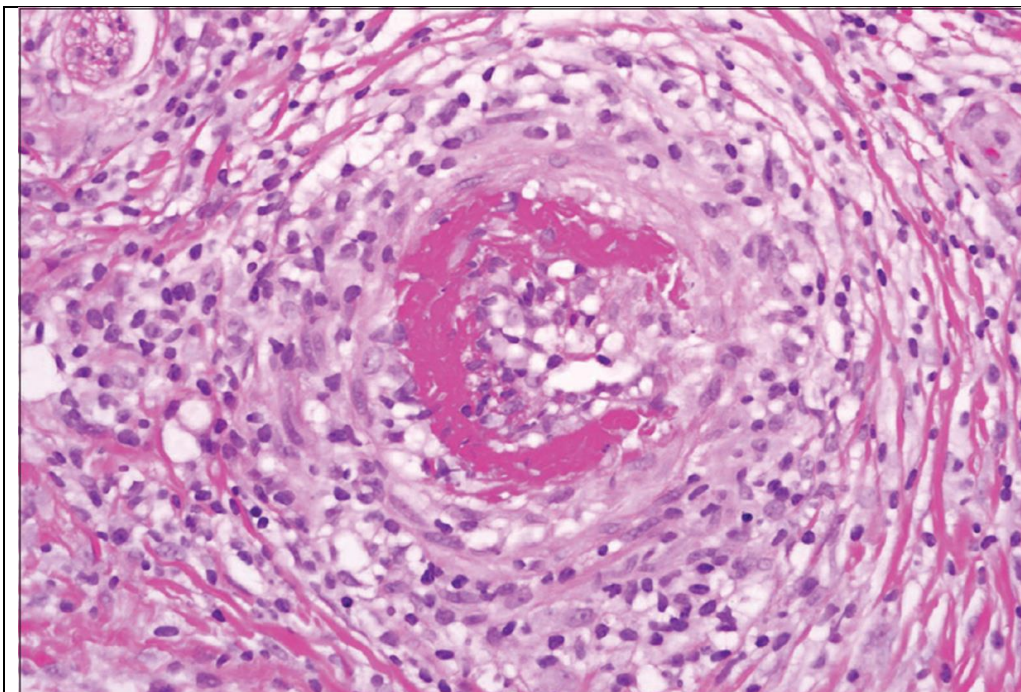


Figure 1.16. M/E: Fibrinoid necrosis of blood vessels.

Inflammation:

- Nonspecific response of vascularized connective tissue to injury.
- Fundamentally protective response, may be potentially harmful.

Types of inflammation:

Acute:

- Rapid onset (sec. – min) short duration: lasts for min → hrs. → day.
- Features exudation of fluid & PP (oedema) extravasation of leukocytes (Neutrophils).

Chronic:

- Longer duration.
- Associated with presence of lymphocytes & macrophages.
- Proliferation of fibrosis, tissue necrosis.

The morphology of inflammatory response (serous, fibrinous, suppurative and ulcer)

Serous inflammation;

Marked by the exudation of transudate (cell poor fluid), in to spaces created by cellular injury or body cavities.

- **Effusion:** accumulation of fluids derived from the plasma (as a result of increased vascular permeability) or mesothelial cells secretions as a result of local irritation.
- **Skin blister:** accumulation of serous fluid beneath the damaged epidermis of the skin resulting from a burn or viral infection.

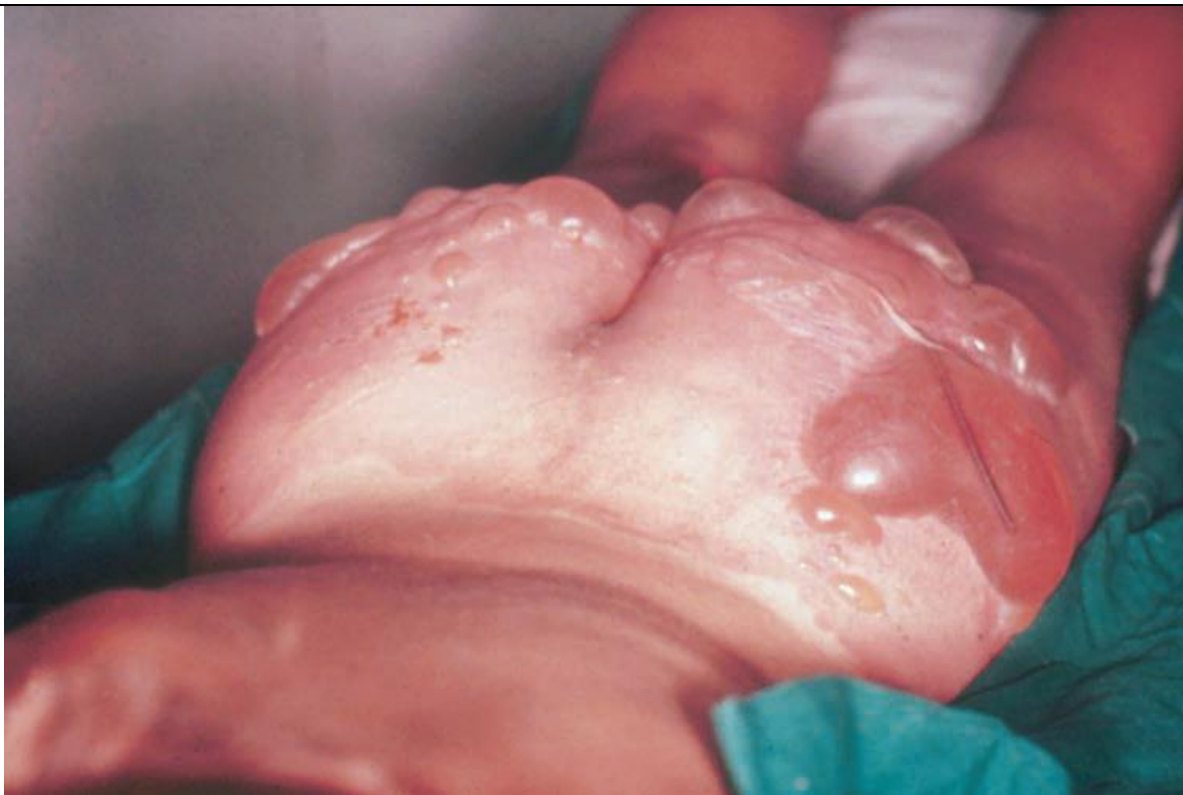

Figure 1-17- serous inflammation: Extensive burns in a patient leading to formation of large skin blisters

Suppurative (purulent) inflammation:

- Type of inflammation characterized by the production of pus, an exudate consisting of neutrophils, the liquefied debris of necrotic cells, and edema fluid.
- The most common cause of purulent inflammation is infection with bacteria that cause liquefactive tissue necrosis, such as staphylococci; these pathogens are referred to as pyogenic (pus-producing) bacteria.
- A common example of an acute suppurative inflammation is acute appendicitis.

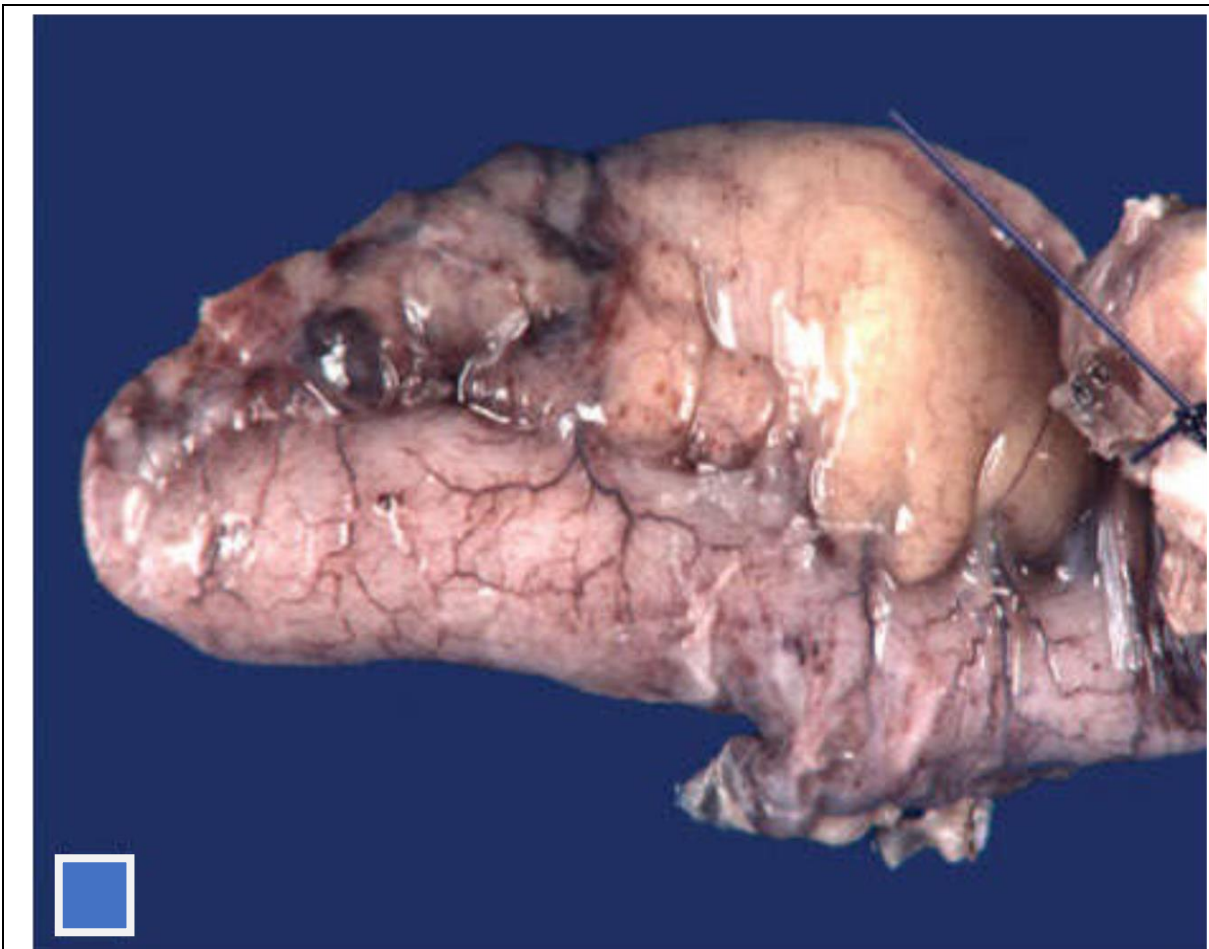


Figure: 1-18 Acute Appendicitis G/a: the appendix is swollen and serosa is hyperemic and coated with fibrinopurulent exudate. The mucosa is ulcerated and sloughed.

Fibrinous inflammation:

- Occurs when the exudated fluid is rich in a blood protein called fibrinogen, which coagulates and forms fibrin, producing a sticky film on the surface of the inflamed tissue.
- E.g. rheumatic heart disease.

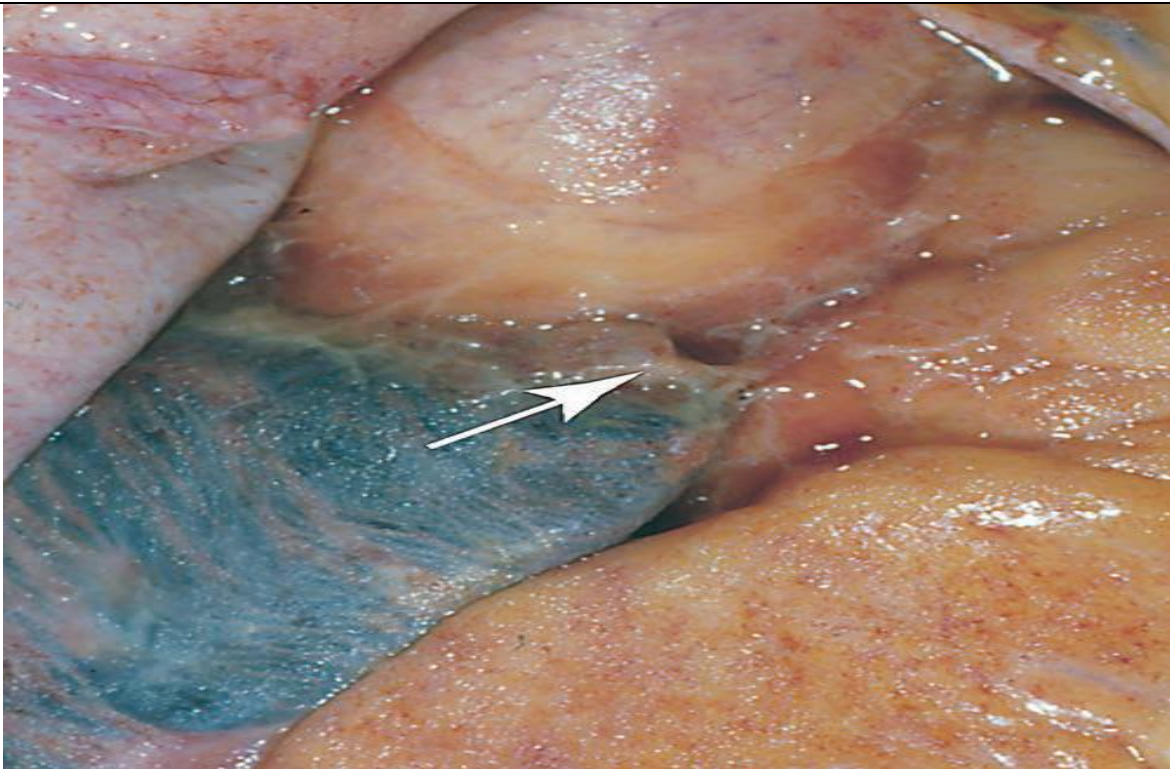


Figure 1- 19- Fibrinous inflammation involving the surface of the heart (epicardium) and pericardium.

Ulcer: An ulcer is a local defect, or excavation, of the surface of an organ or tissue that is produced by the sloughing (shedding) of inflamed necrotic tissue

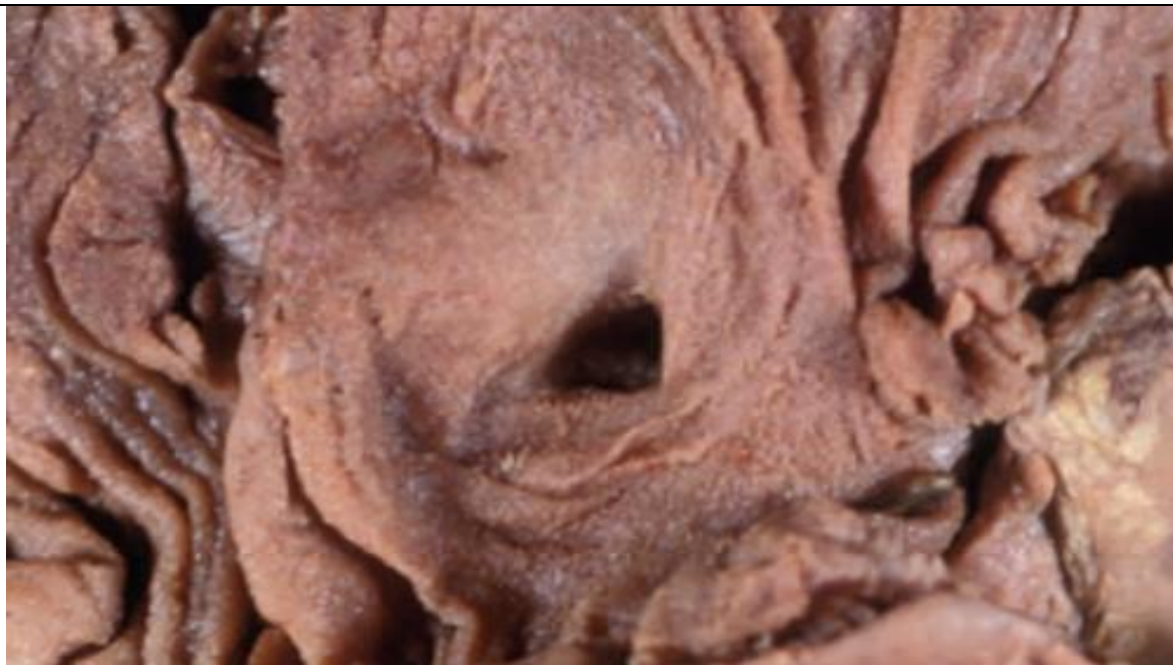

Figure 1-19 G /A: The morphology of duodenal ulcer.

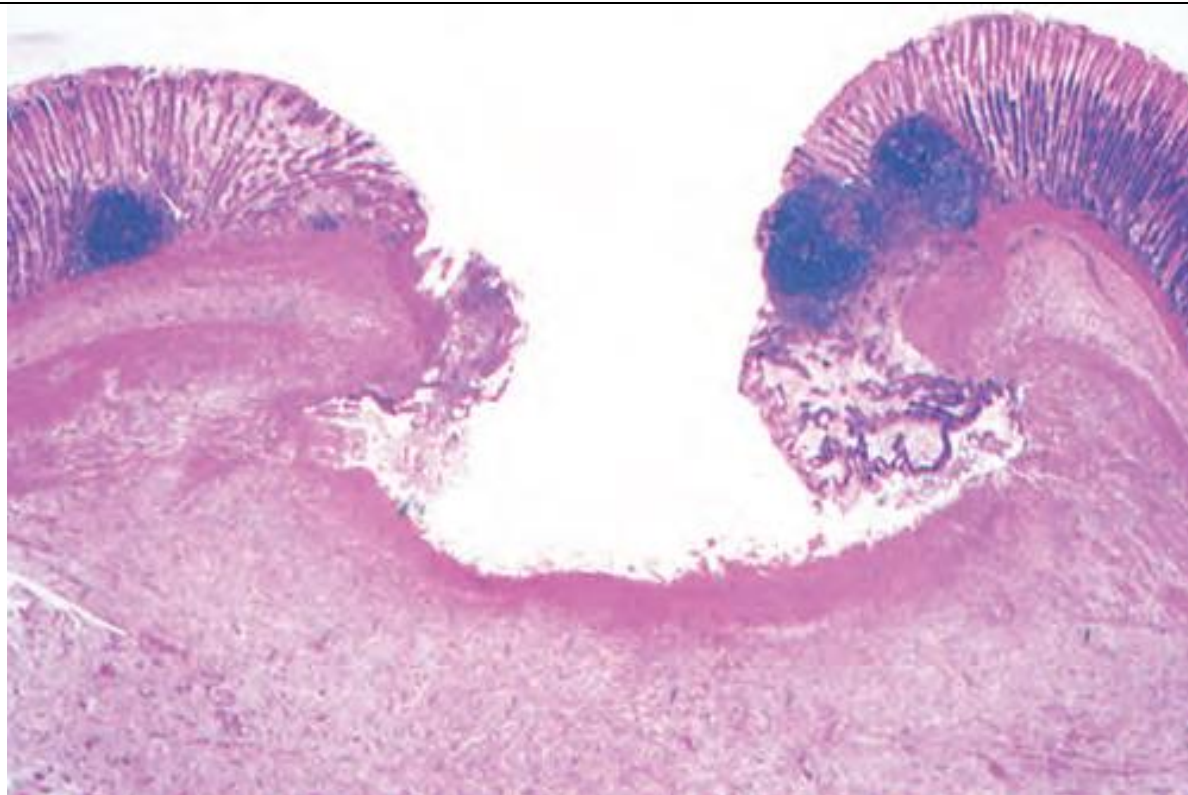

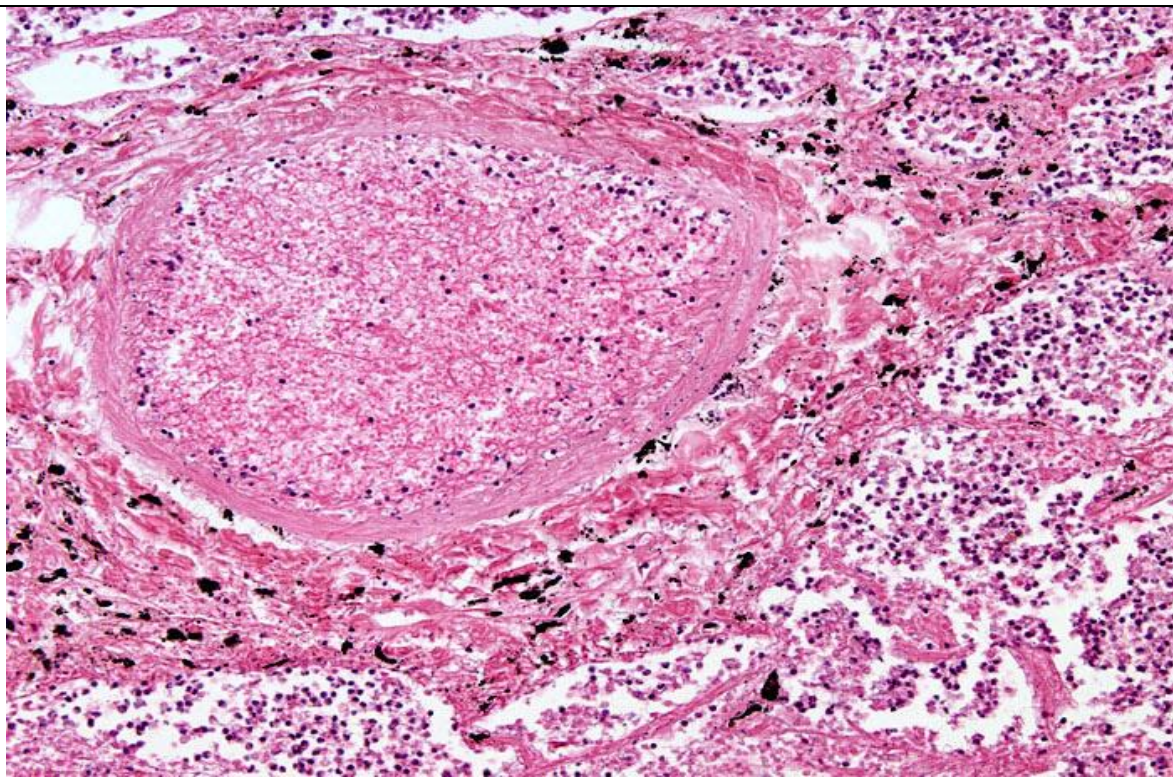
Figure 1-20- M/E Cross-section view of a duodenal ulcer crater with an acute inflammatory exudate in the base.

Abscess:

is the formation of cavity as a result of extensive tissue necrosis following pyogenic bacterial infection accompanied by intense neutrophilic infiltration. Abscess of the lung may occur due to inhalation, embolic phenomena, and pneumonia.

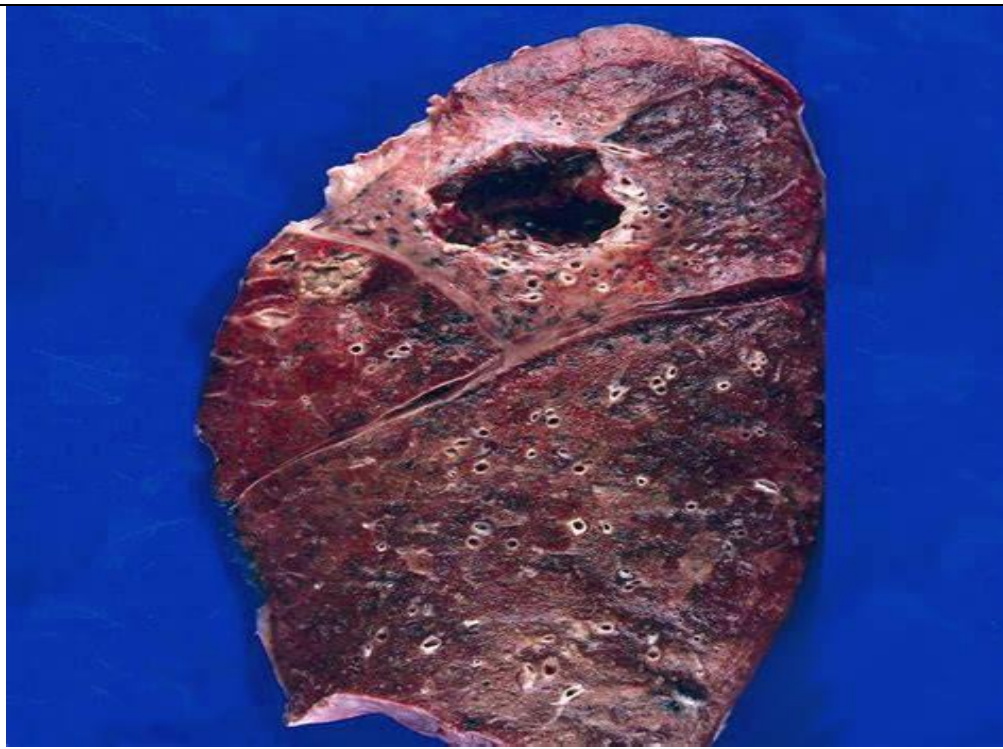

Figure 1- 21 G/a: abscess is more common in the right lung and may occur in upper or lower lobe. Size of the cavity may vary from small to fairly large. The wall is ragged and necrotic but advanced lesions may show fibrous and smooth wall. The inhalation abscess may communicate with the bronchus.



Figure

1-22 - M/e: i. the wall of the abscess shows dense infiltration by polymorph nuclear leucocytes and varying number of macrophages. More chronic cases show fibroblasts at the periphery. Lumen of the abscess contains pus consisting of purulent exudate, some red cells, fragments of tissue debris and fibrin

Calcification

Medial calcific sclerosis is dystrophic calcification in the degenerated media of large and medium-sized muscular arteries, especially of extremities and of the genital tract in the elderly (e.g. in uterine myometrium).

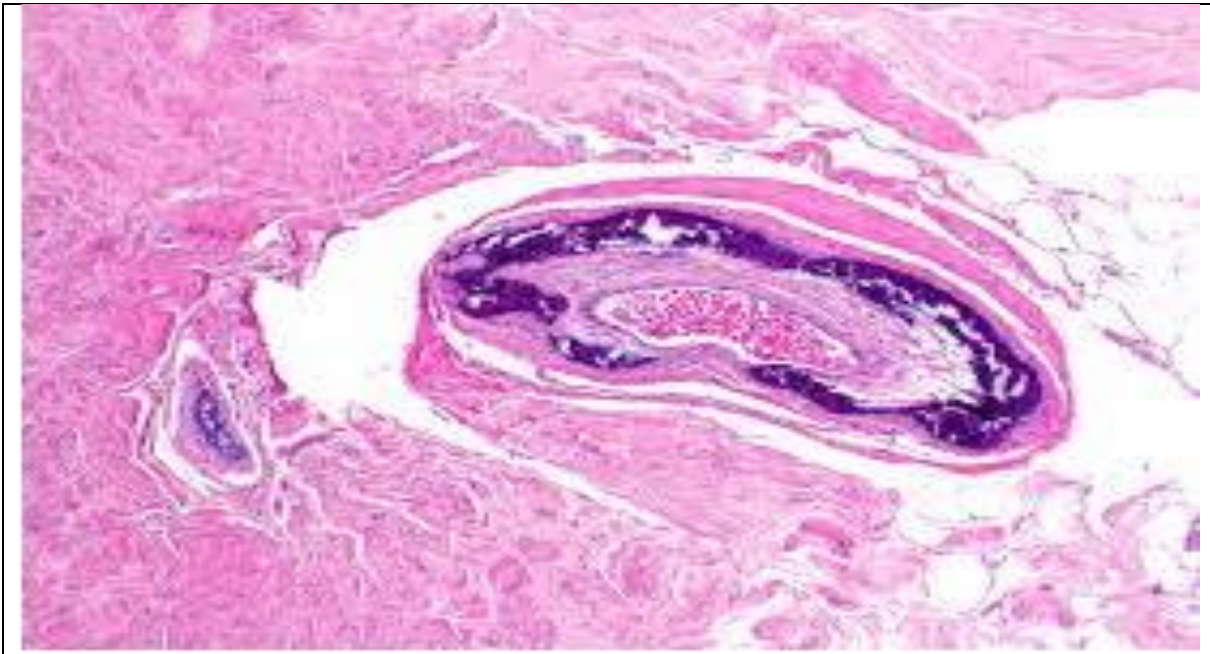


Figure 1-23/ M/e i. smooth muscle of media is replaced by acellular hyalinised fibrous tissue.

ii. Foci of dystrophic calcification are seen in the media as basophilic coarse granules.

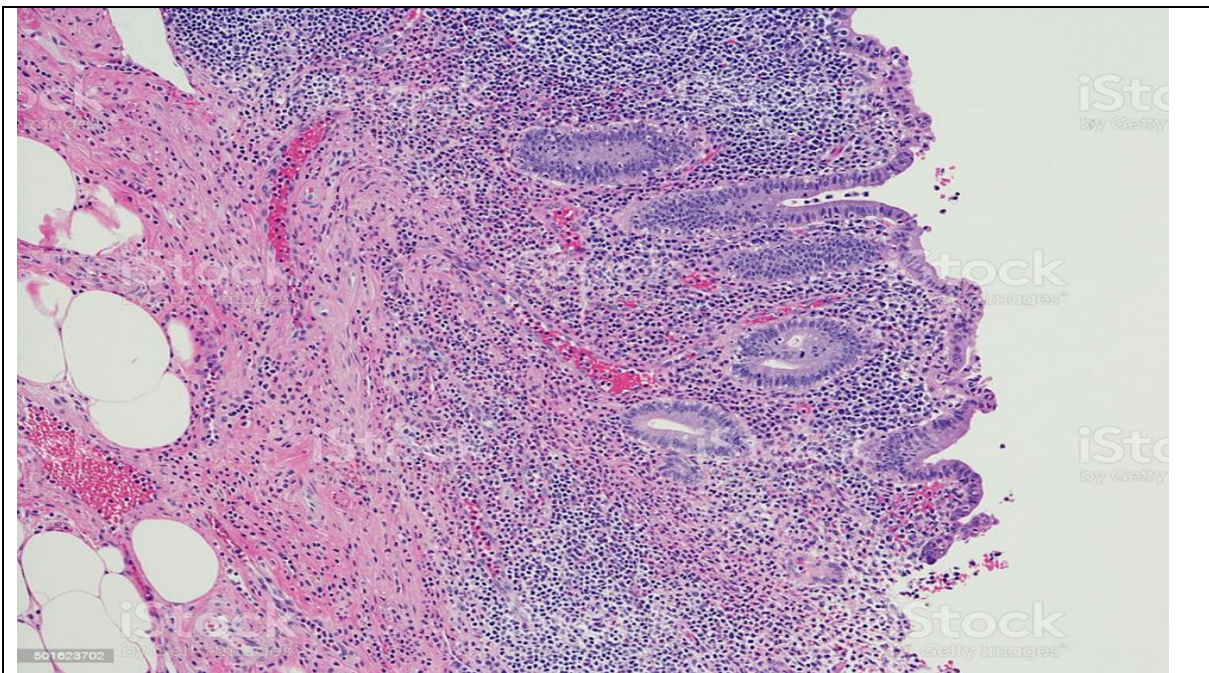


Figure 1-24 M/e: i. most important diagnostic feature is neutrophilic infiltration of the muscularis propria.

ii. Mucosa is sloughed and blood vessels in the wall are thrombosed.

Chapter two

Blood & Lymph:

- **Learning Outcomes of haematology course:**
- **The normal peripheral blood picture.**
- **Anaemias.**
- **Hodgkin and non-Hodgkin lymphomas.**

- **Materials:**
- **Images of blood films and bone marrow.**
- **Practical haematology laboratory**

- Identify types of blood cells:

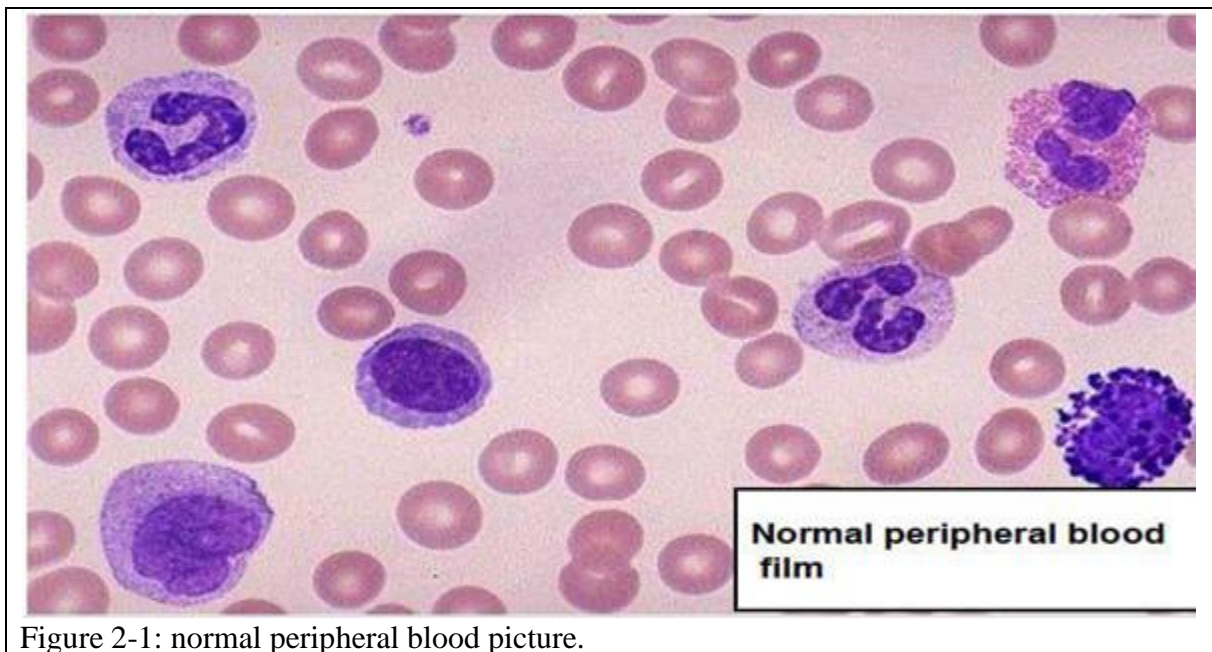


Figure 2-1: normal peripheral blood picture.

- Normal haematopoiesis

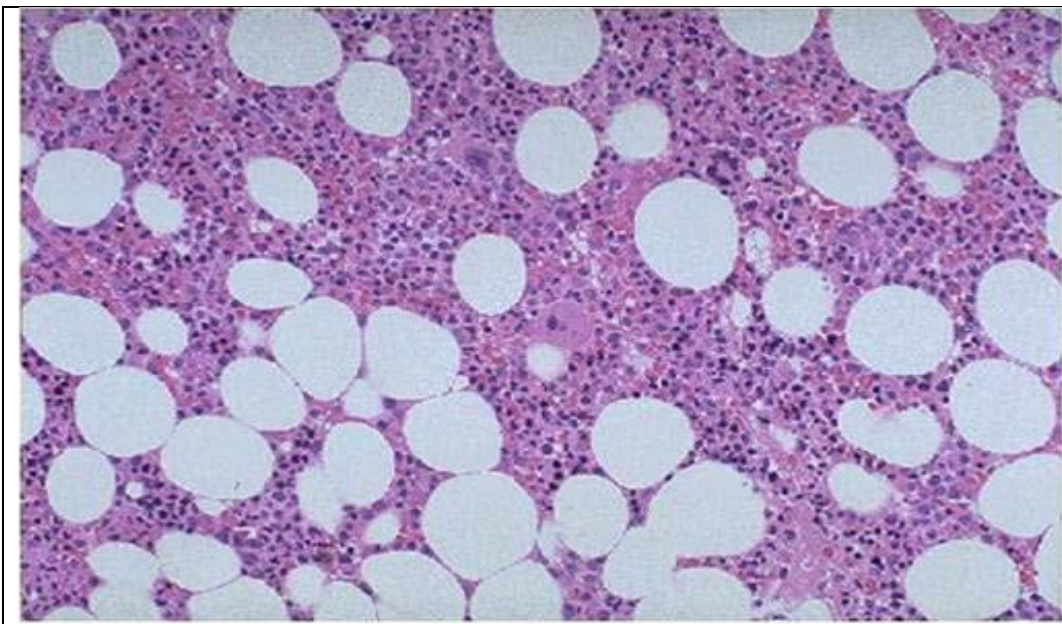


Figure 2-2 Normal bone marrow

- Identify types of anaemia's

Type of anemia microcytic hypochromic normocytic normochromic and macrocytic.

Microcytic hypochromic anemia

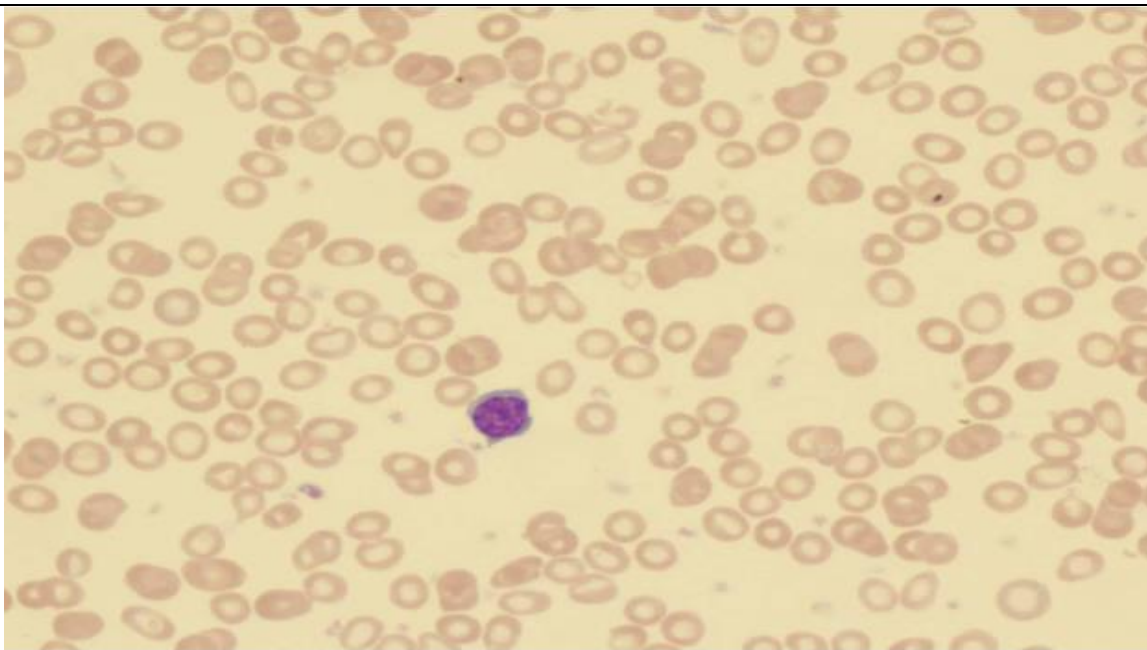


Figure 2-3 PBF in microcytic hypochromic anaemia.

Megaloblastic anemia

Megaloblastic anemias are characterized by defective/impaired DNA synthesis and distinct megaloblasts in the bone marrow.

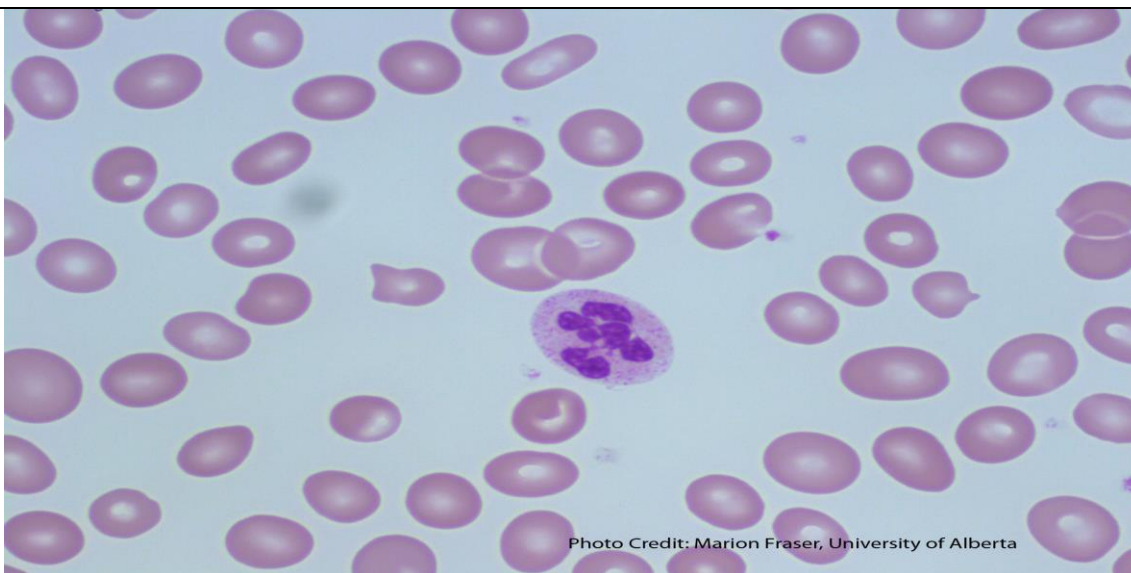

Figure 2-5 megaloblastic anaemia, note the large RBCs

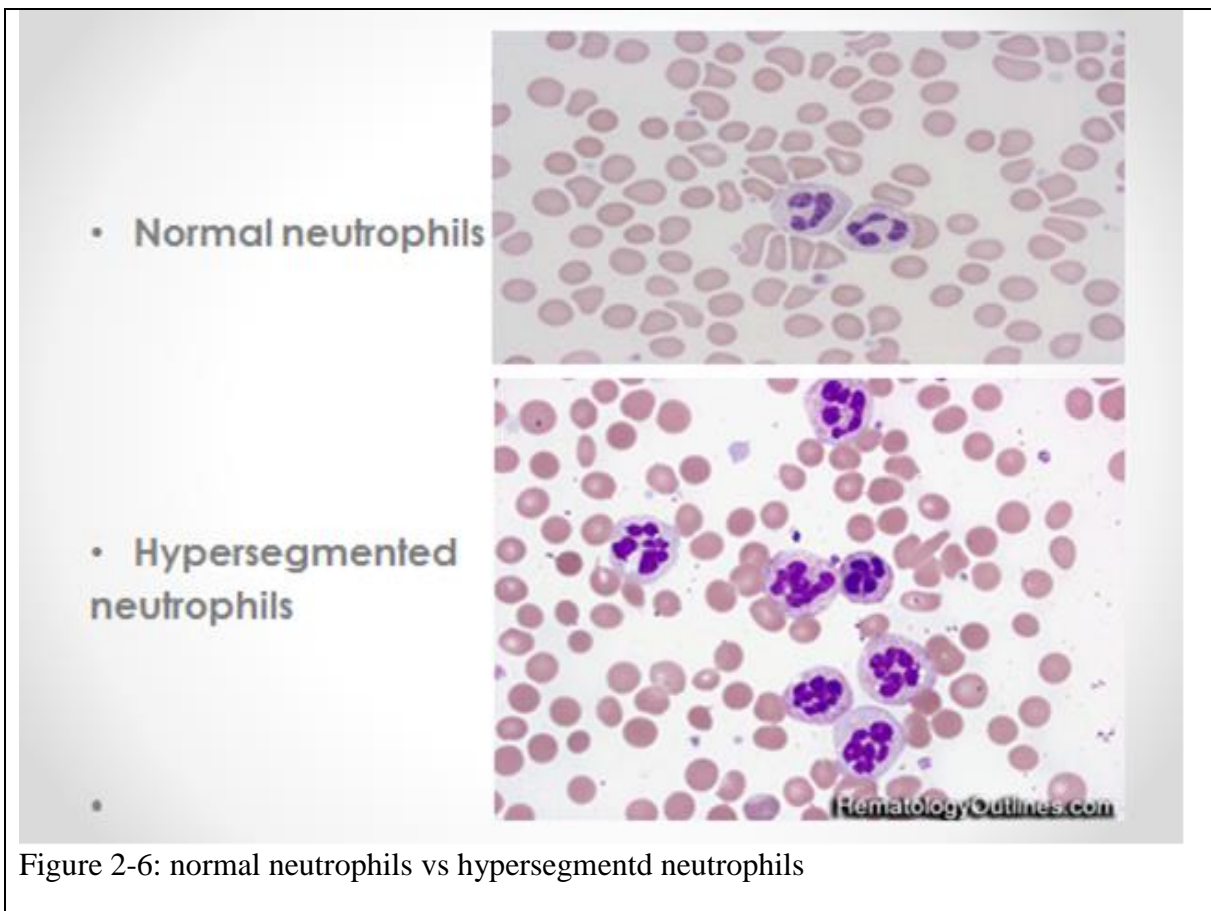


Figure 2-6: normal neutrophils vs hypersegmented neutrophils

Sickle cell disease

Sickle cell diseases are hemoglobinopathies characterized by qualitative defect in hemoglobin synthesis.

Definition: sickle cell disease (SCD) is a group of hereditary disorders of hemoglobin characterized by production of defective hemoglobin called sickle hemoglobin (Hb_s).

Sickle cell anemia: autosomal recessive disorder with extravascular hemolysis.

Characteristic features:

- _ Autosomal recessive disorder manifests early in life.
- _ Homozygous state (ss) caused by a mutation in the β -globin gene.
- _ Hb_s constitutes more than 70% of hemoglobin in their RBCs with no Hb A.

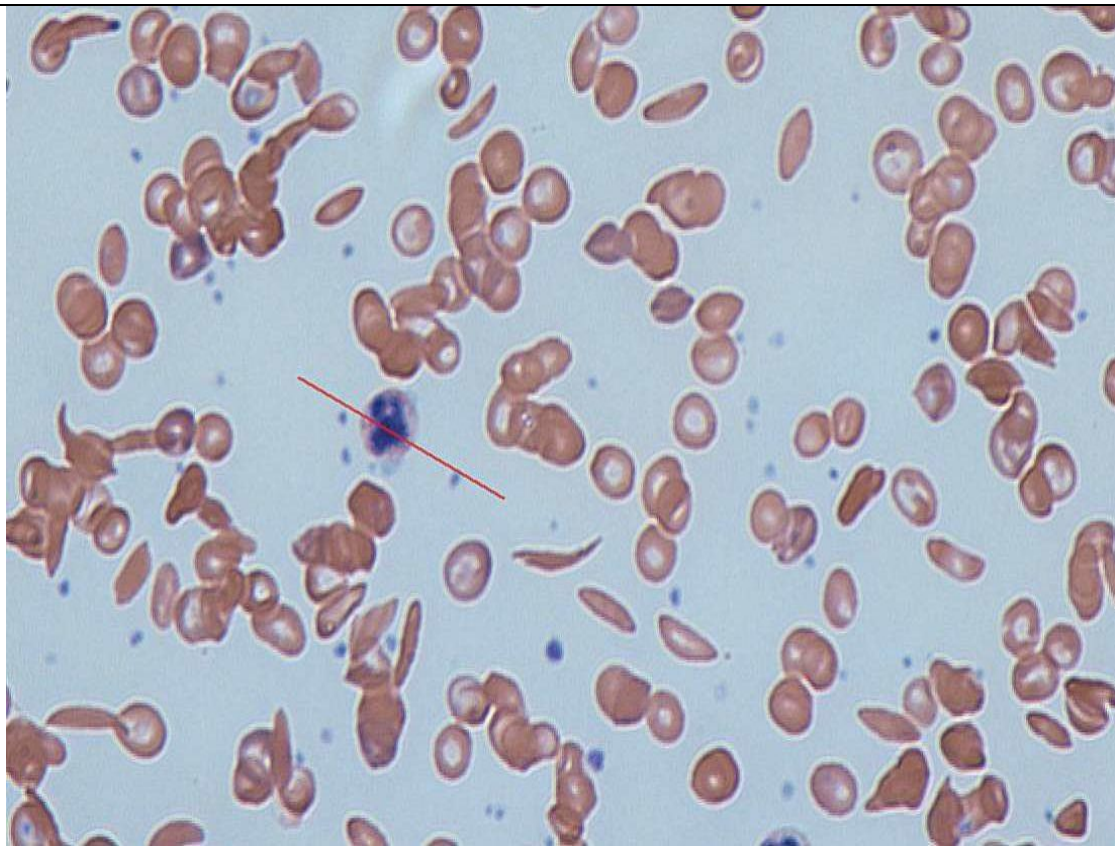


Figure: 2-10 M/E Peripheral blood smear with sickle cells

Thalassemia

The thalassemias are a diverse group of hereditary disorders in which there is reduced rate of synthesis of one or more of the globin polypeptide chains. Thalassemias, unlike other hemoglobinopathies which are qualitative disorders of hemoglobin, are quantitative abnormalities of polypeptide globin chain synthesis.

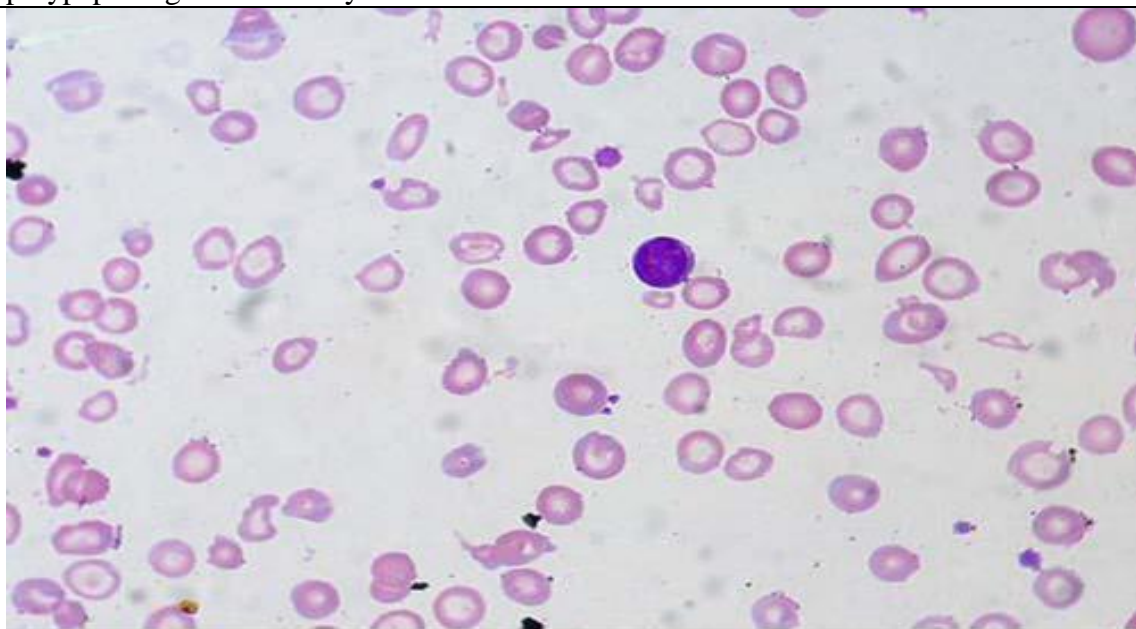


Figure 2-11 Peripheral blood smear in β -thalassemia showing target cells

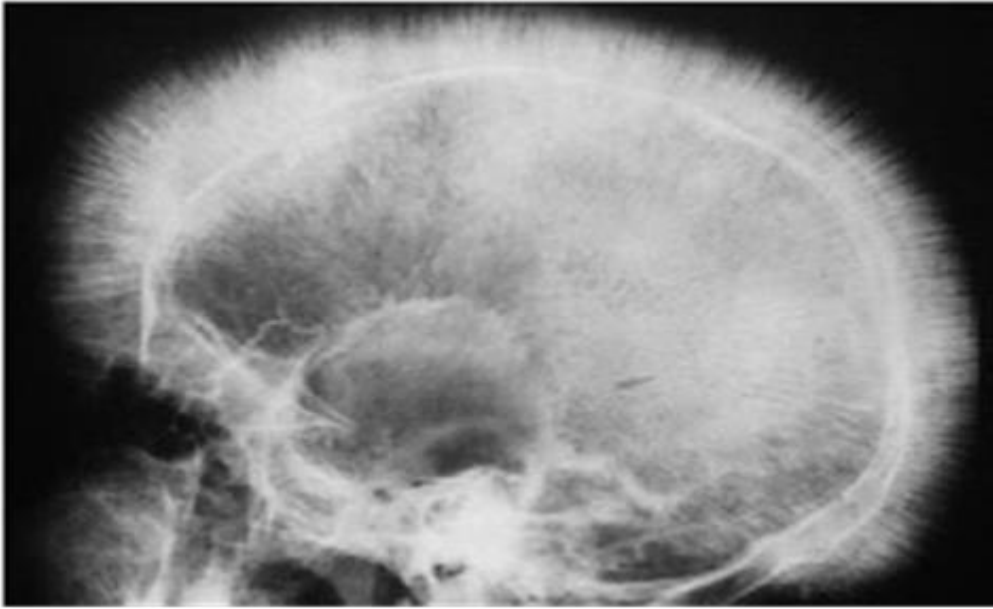


Figure 2-13 x ray of skull hair on end appearance due to bone marrow expansion in beta thalassemia major

Hereditary spherocytosis: it is a rare inherited hemolytic anemia resulting from the defect in the red cell membrane.

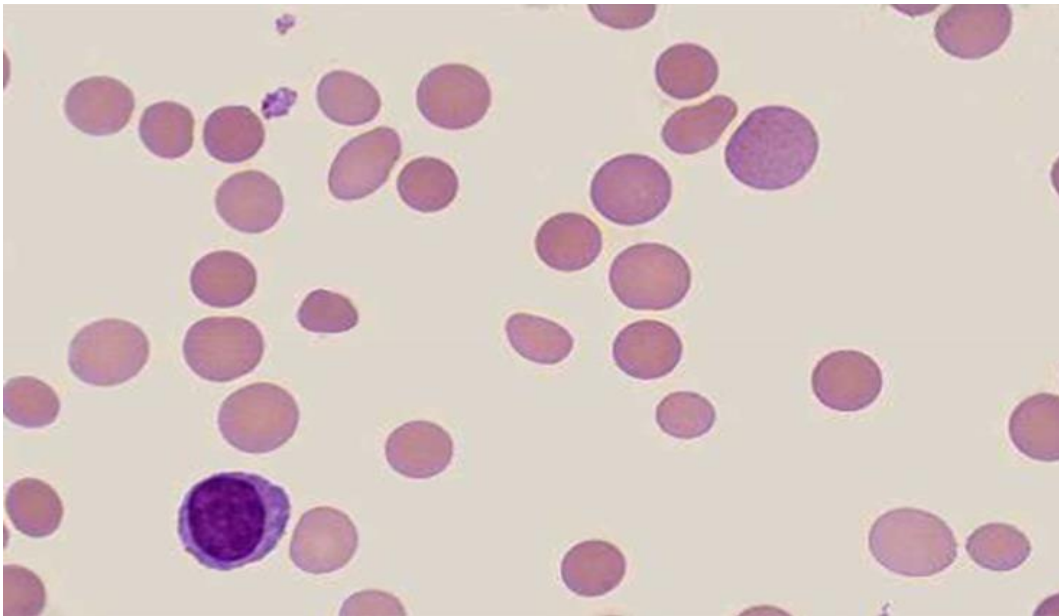


Figure 2-14 M/E Large cells in hereditary spherocytosis,

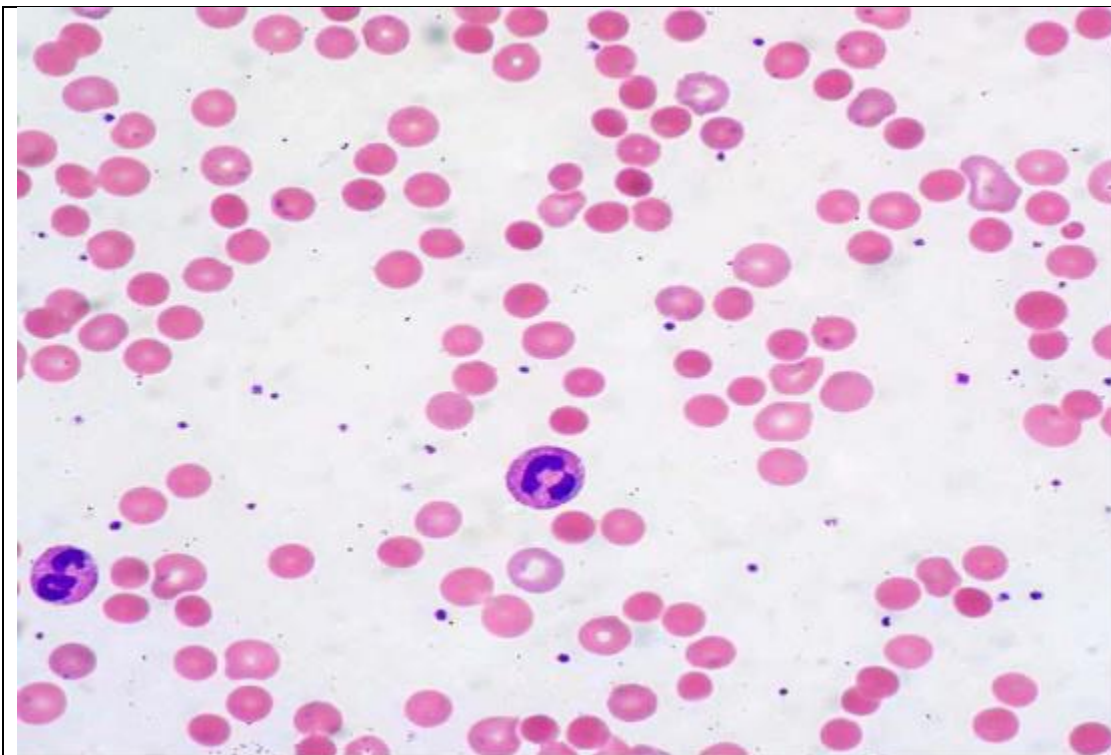


Figure 2-15 Glucose-6-phosphate dehydrogenase deficiency.

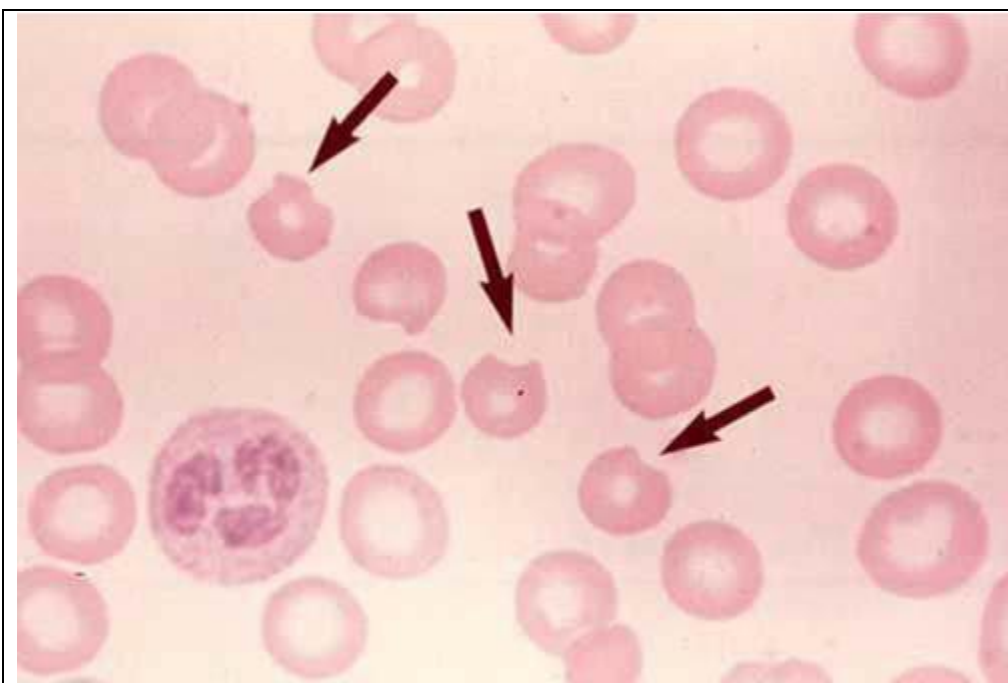


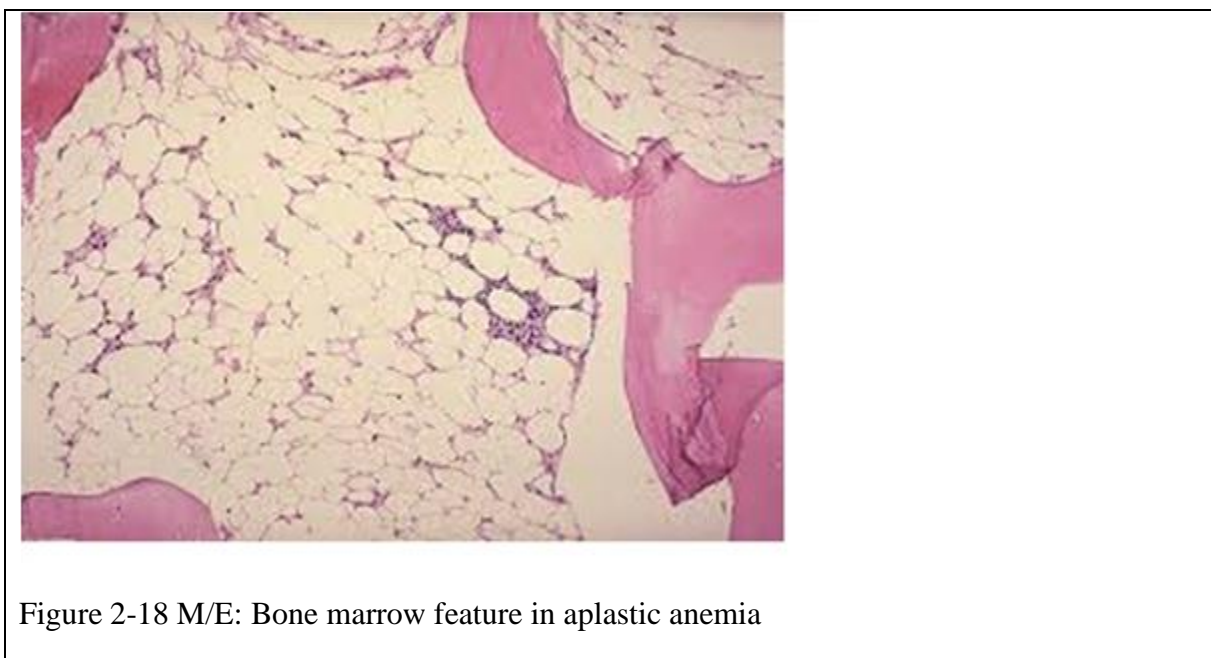
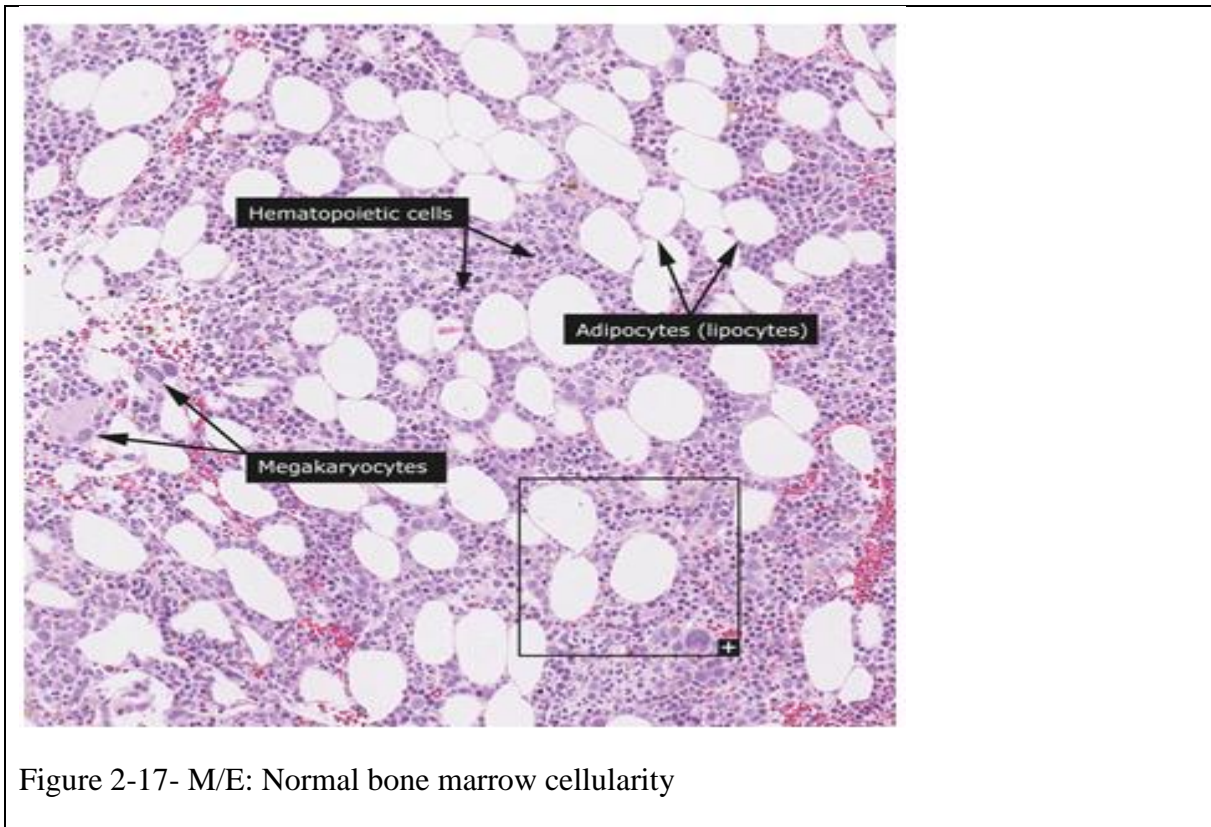
Figure 2-16 M/E: Peripheral blood smear in G6PD deficiency with “bite cells” (arrows). Inset shows Heinz bodies (supravital stain)

Aplastic anaemia and laboratory finding

Aplastic anemia

Chronic primary hematopoietic stem cell disorder characterized by:

_ Pancytopenia (anemia, neutropenia and thrombocytopenia). Markedly hypocellular bone marrow



Haematological malignancies:

- Neoplastic proliferations of white blood cells includes leukaemias and lymphomas, Leukaemias are characterized by proliferation resulting in accumulation of immature myeloblasts in the marrow.

Historically, leukaemias have been classified to:

- Acute myeloblastic leukaemia (AML)
- Acute lymphoblastic leukaemia (ALL)
- Chronic myeloid leukaemia (CML)
- Chronic lymphocytic leukaemias (CLL).

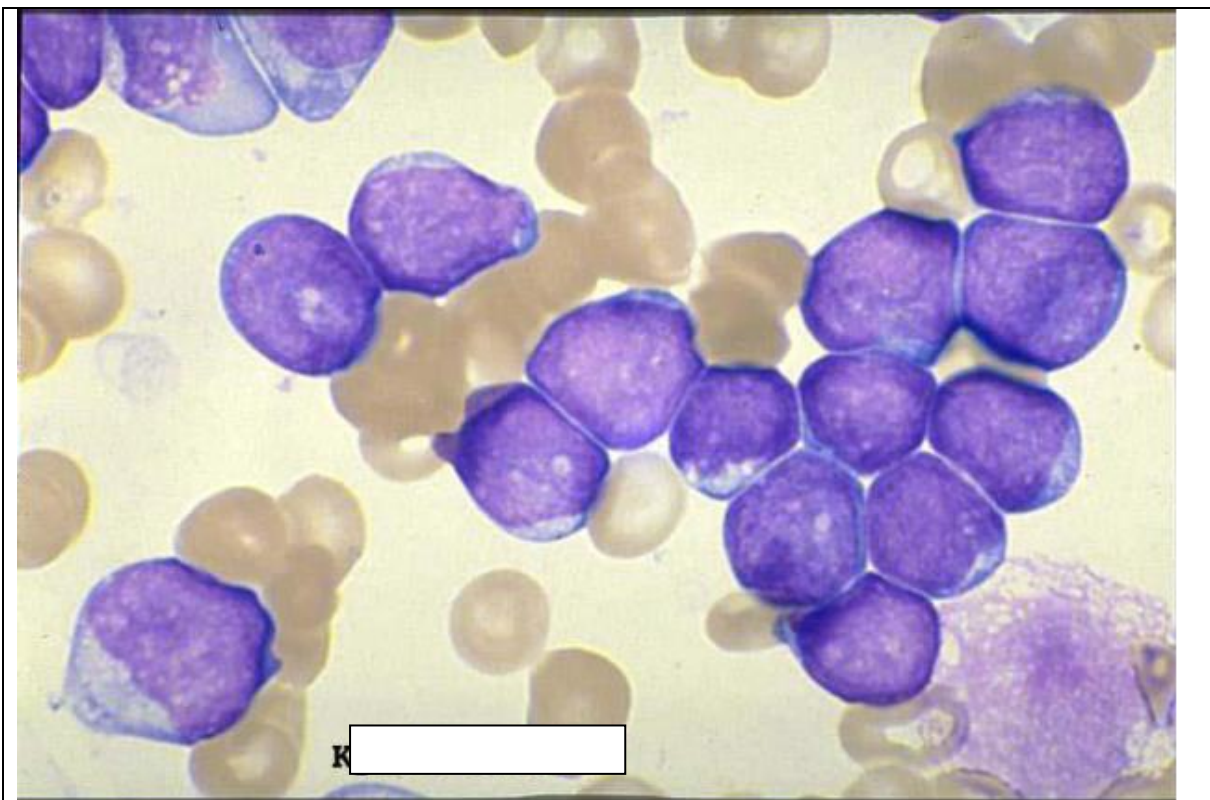


Figure 2-19 M/E: Peripheral smear in AML with myeloblasts.

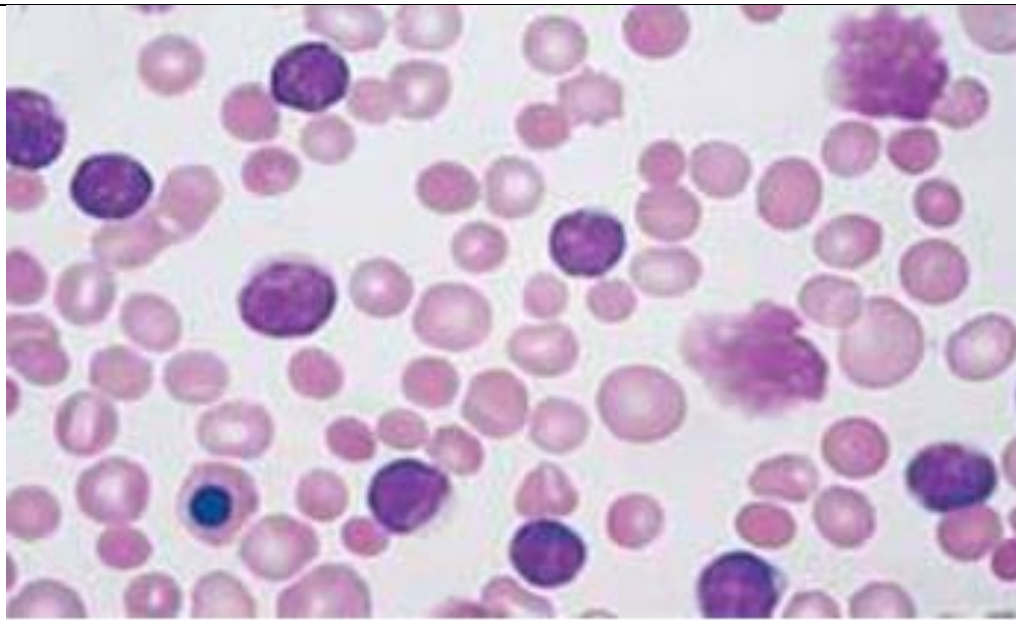


Figure 2-20: M/E: Peripheral blood smear in chronic lymphocytic leukemia showing numerous small

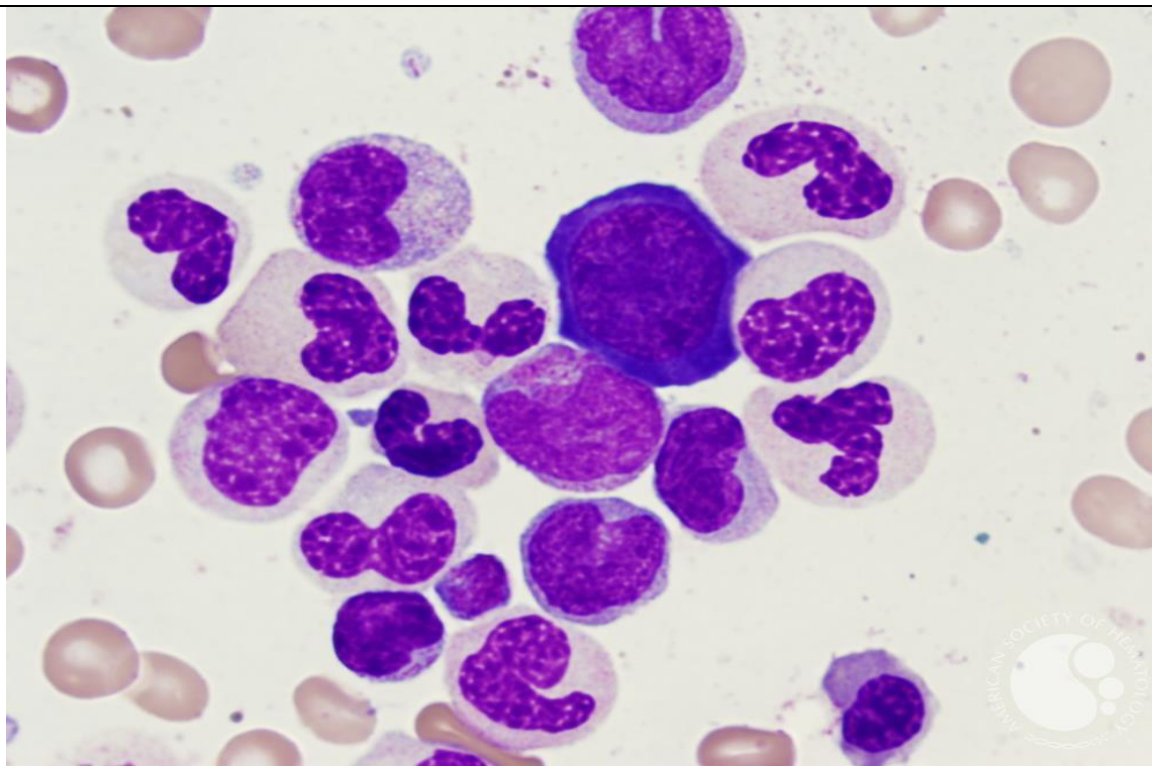


Figure 2-21 PBF findings in chronic myeloid leukaemia. There is rise in leucocyte count consisting of immature myeloid precursor cells of various stages.

Multiple myeloma (MM) is a multifocal malignant tumor of plasma cell and arises in the bone marrow.

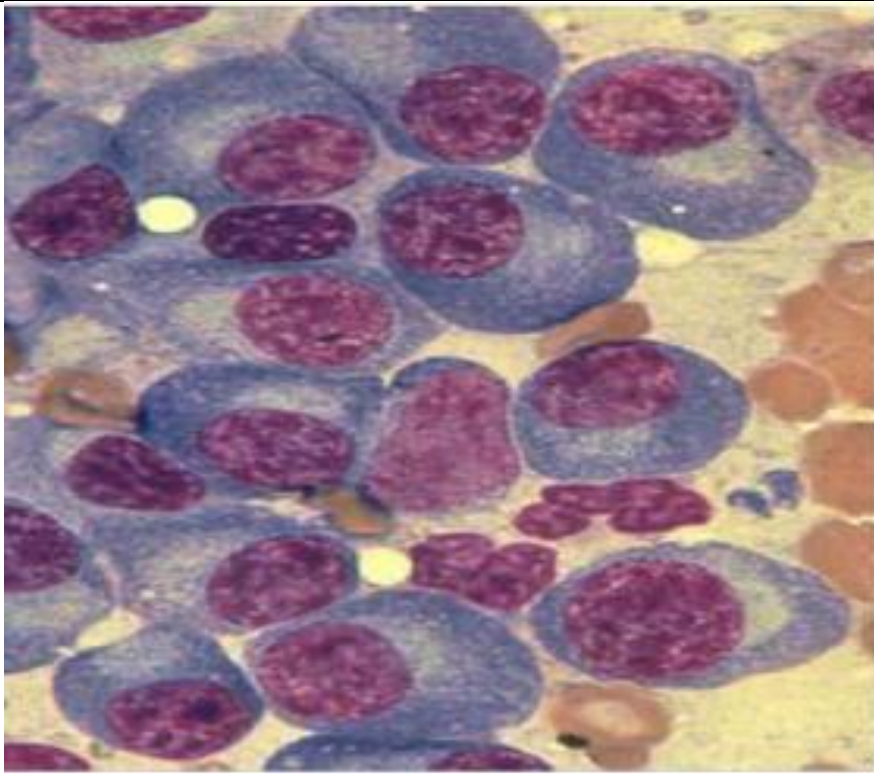


Figure 2-22: Bone marrow aspirate in multiple myeloma. Note numerous myeloma plasma cells.

Lymphoid neoplasms:

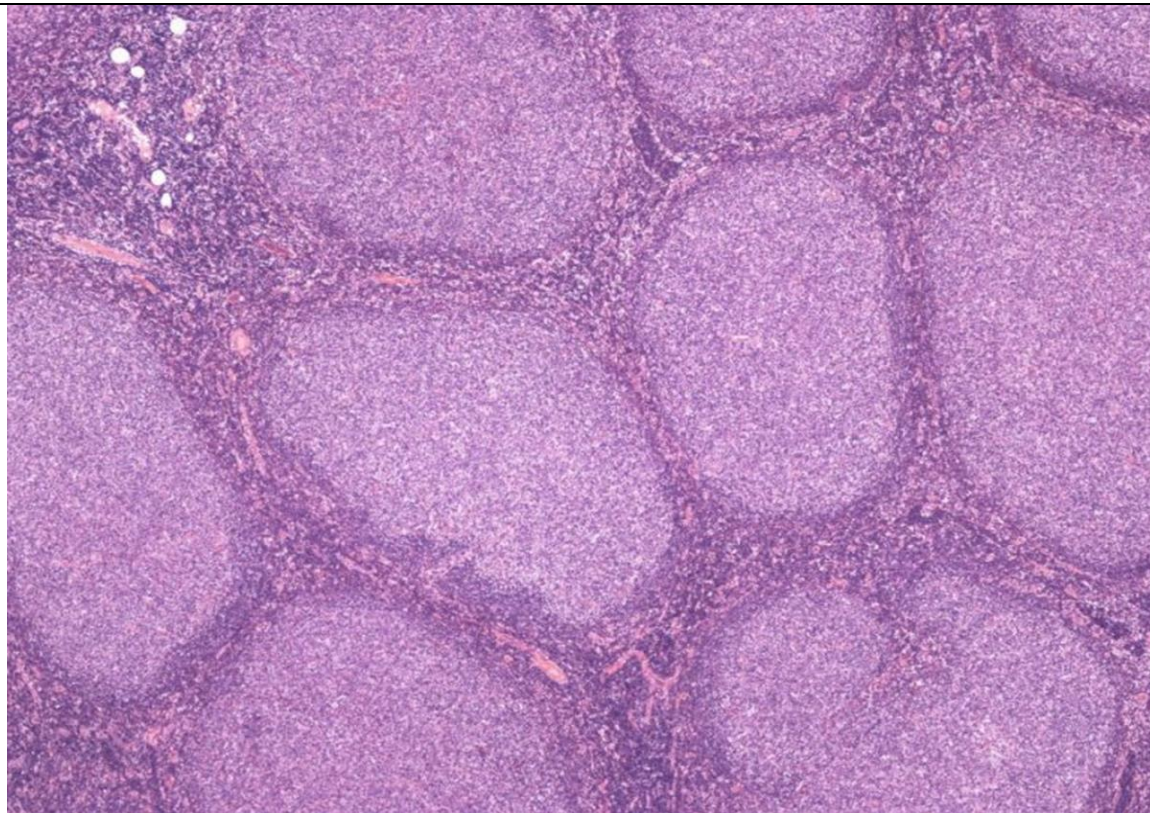


Figure 2-23: Follicular lymphoma shows nodular aggregates of malignant lymphoid cells

Burkitt lymphoma:

- Highly aggressive B cell neoplasm.

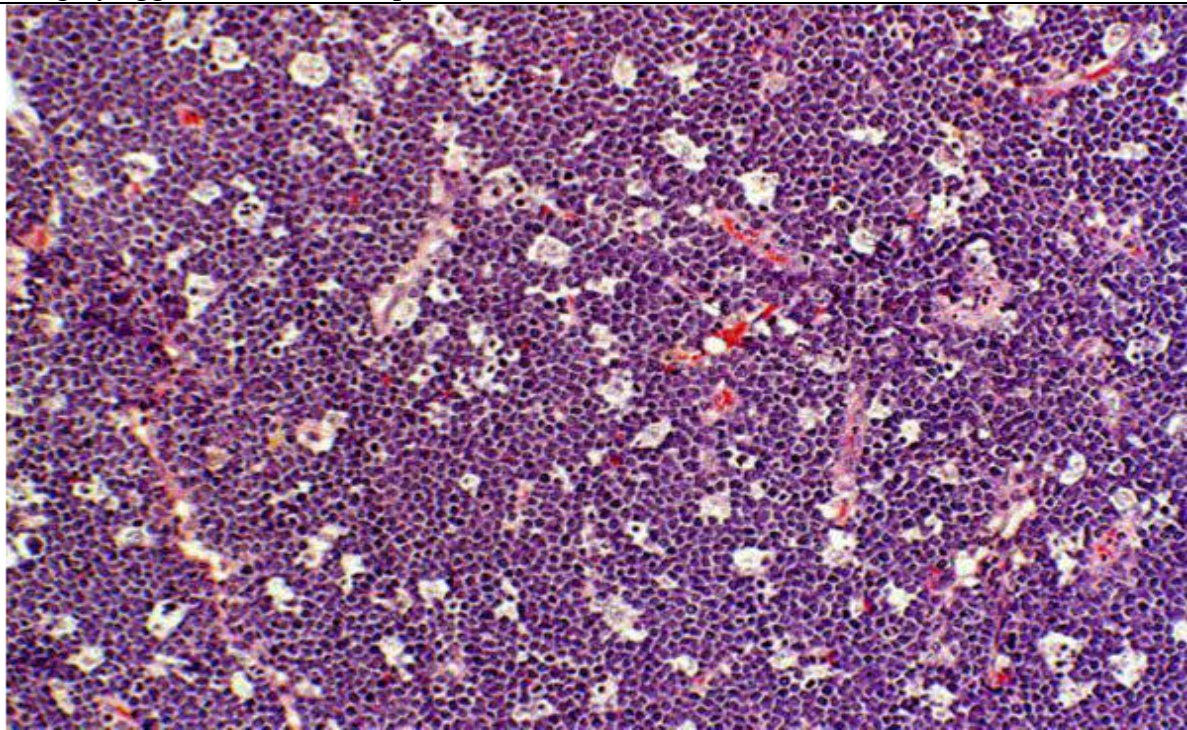


Figure 2:24 Star sky appearance in burkitt lymphoma

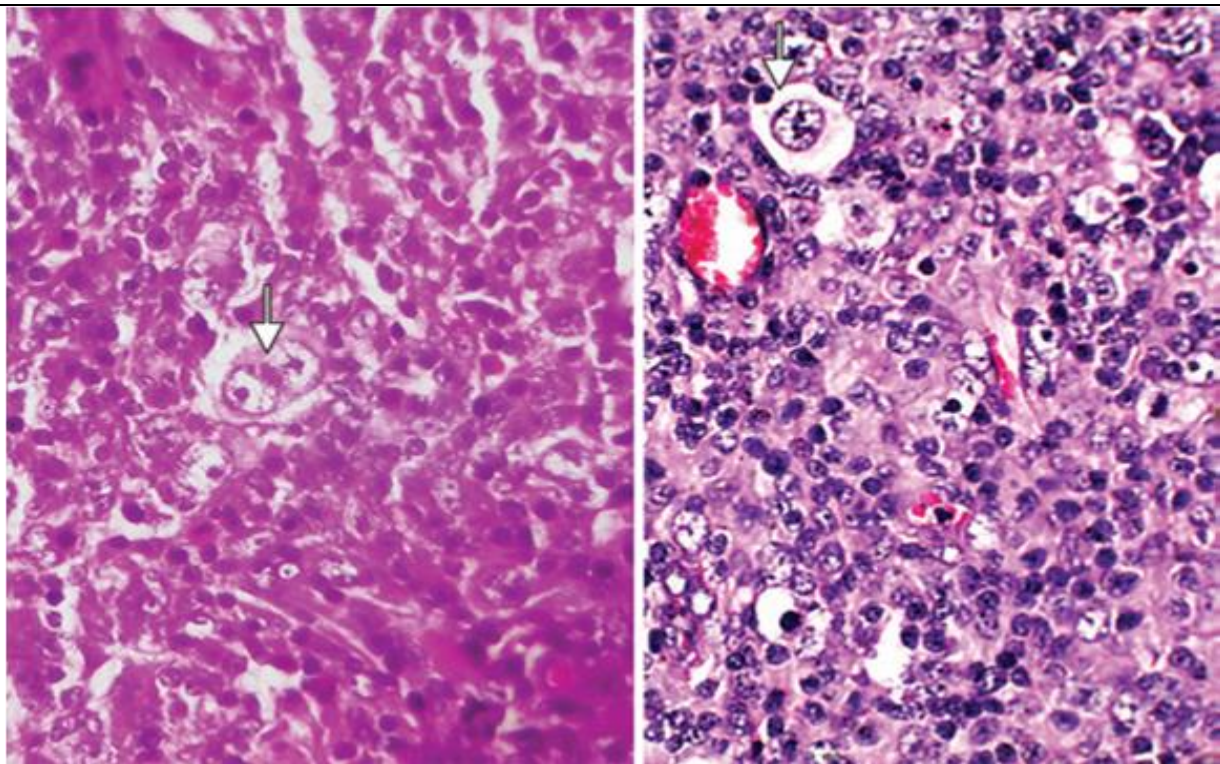


Figure 2-25 M/E: Hodgkin lymphoma showing RS cells (short arrow and inset) and Hodgkin cells (long arrow) within the background of mixed population of reactive cells

- **Coagulation disorders:**

Hemophilia A (factor viii deficiency)

- common hereditary x-linked recessive disease.
- about 30% of hemophiliacs may be due to acquired mutations.
- reduced amount or activity of factor viii is associated with life-threatening bleeding
- bleeding is due to both inadequate coagulation and inappropriate clot removal

Chapter Three

Cardiovascular System (ME-CVS-214)

Learning Outcomes:

- Definition and differentiation between the terms “atherosclerosis” and “arteriosclerosis.
- Description of the macroscopic and microscopic pictures of atherosclerotic arteries.
- Differentiate between true, false, and dissecting aneurysms
- Explain the pathogenesis of rheumatic heart disease (RHD) and morphological changes in the involved cardiac structures.

Arteriosclerosis vs atherosclerosis:

- Sclerosis is the thickening or hardening of a body part.
- Arteriosclerosis is "hardening" of the arteries” it is the thickening of arteries with loss of elasticity.

There are three types of arteriosclerosis:

1. **Medial Calcification (Monckeberg Medial Sclerosis):** Dystrophic calcification of muscular arteries.
2. **Arteriolosclerosis: The two types of this disease are:**
 - a. Hyaline arteriolosclerosis: occurs in patients with diabetes mellitus.
 - b. Hyperplastic arteriolosclerosis: occurs in patients with severe hypertension.
3. **Atherosclerosis;**
 - It is a progressive disease of intima involving large and medium-sized elastic and muscular arteries.
 - It is characterized by focal lipid-rich intimal lesions called atheromas (atheromatous or atherosclerotic plaques).

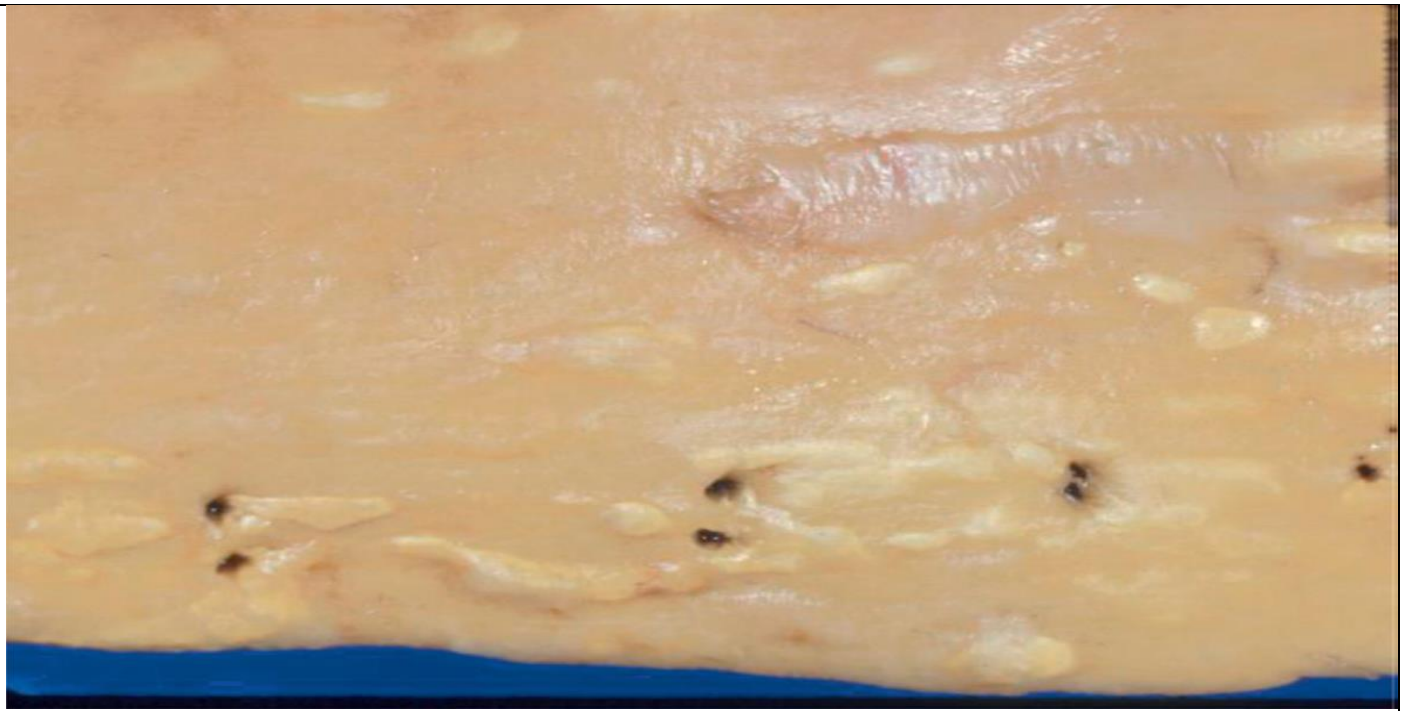

Figure 3-1 Atherosclerosis: G/a of an irregular shaped raised yellow/white atherosclerotic plaques. And Non elevated lesions fatty streaks

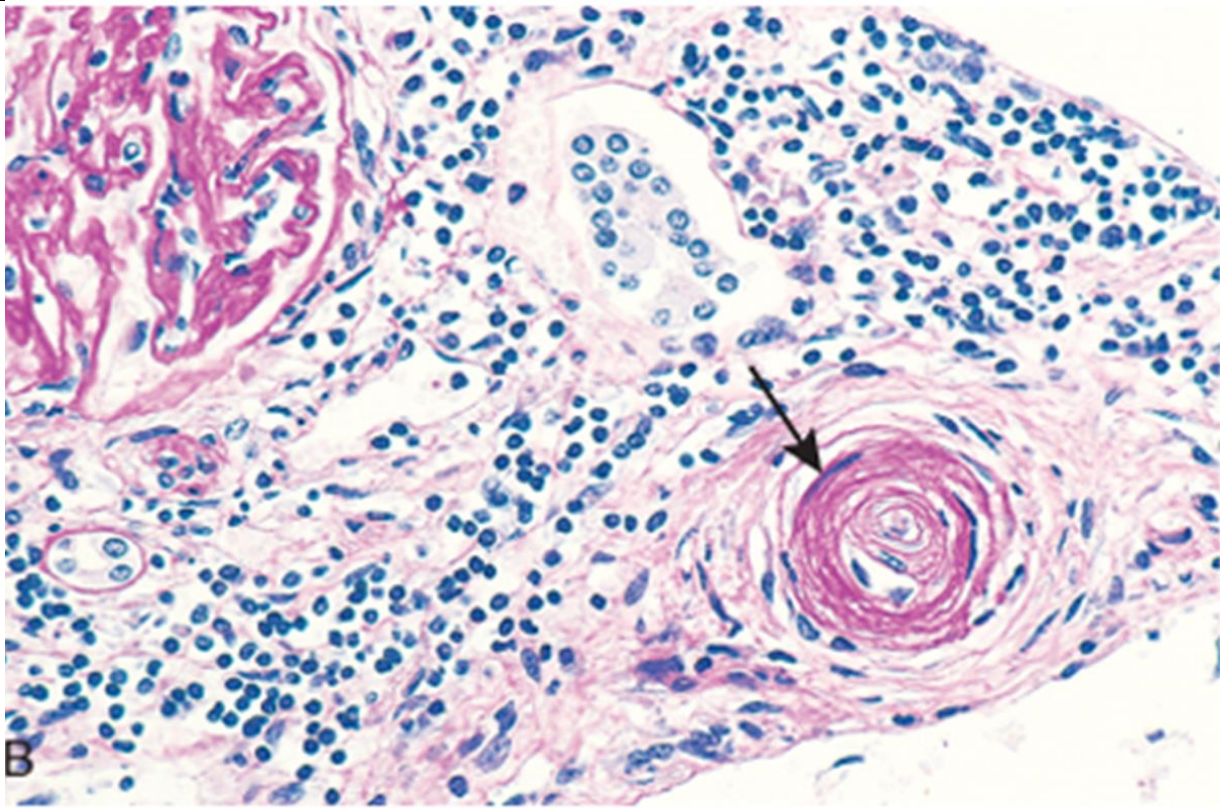


Figure: 3-2 Hyperplastic arteriosclerosis, patient with severe hypertension. Onion skin appearance of blood vessel. (arrow)

Rheumatic heart diseases:

Pathogenesis of RHD:

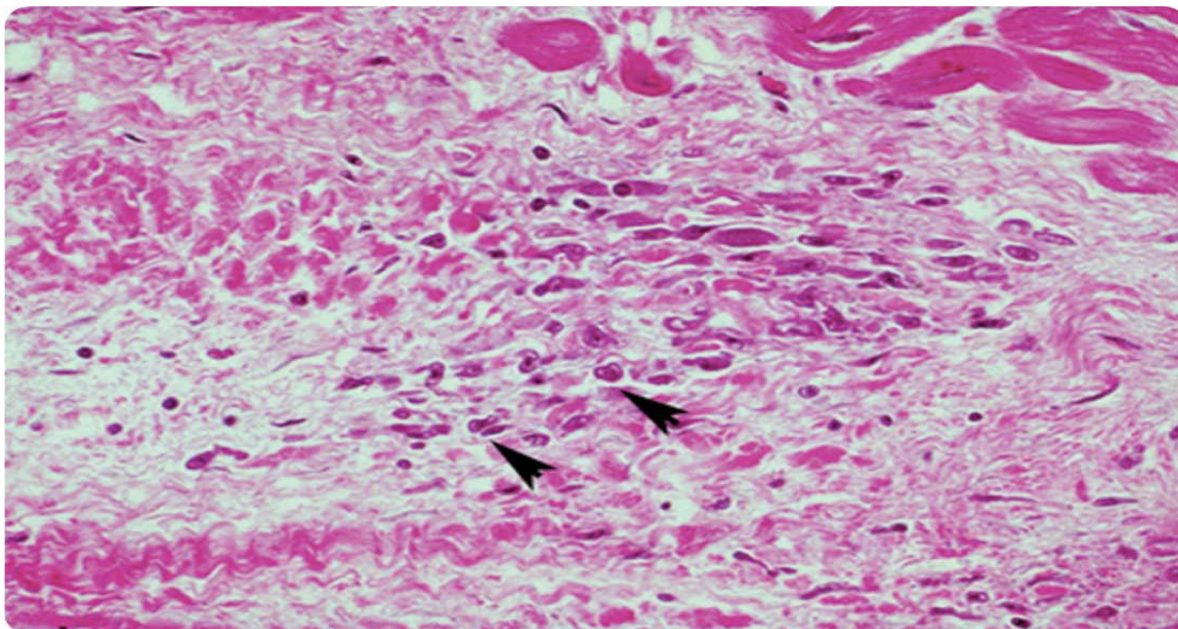
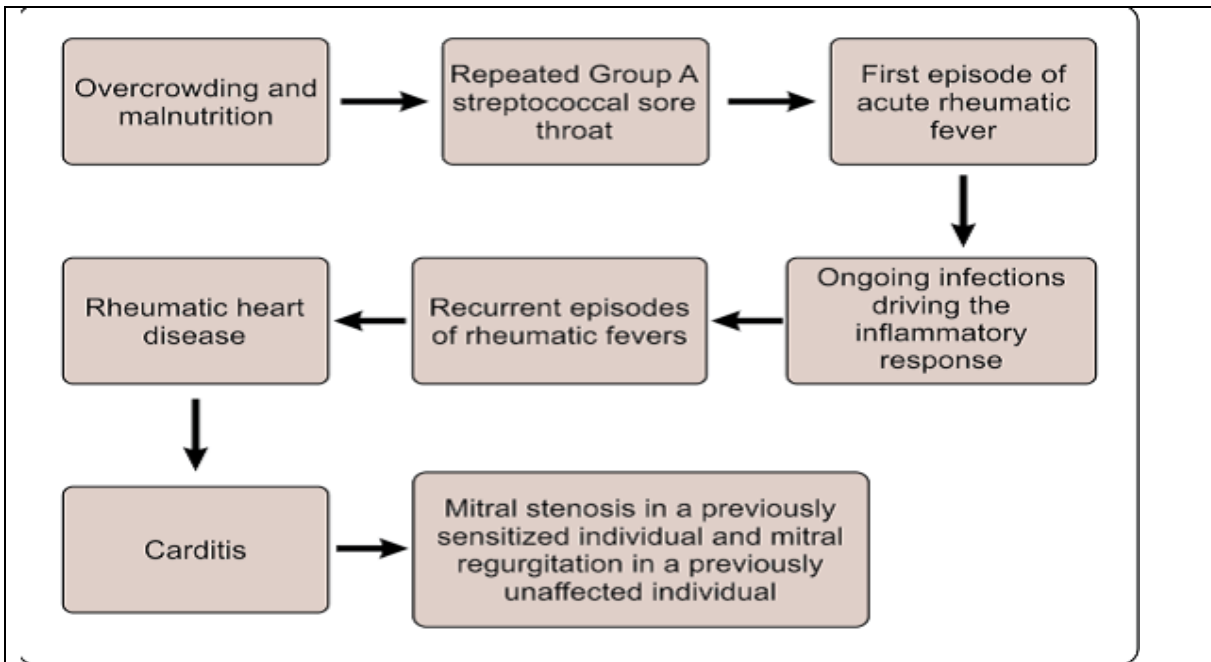


Figure 3.3. Aschoff bodies in rheumatic heart disease (Arrow).

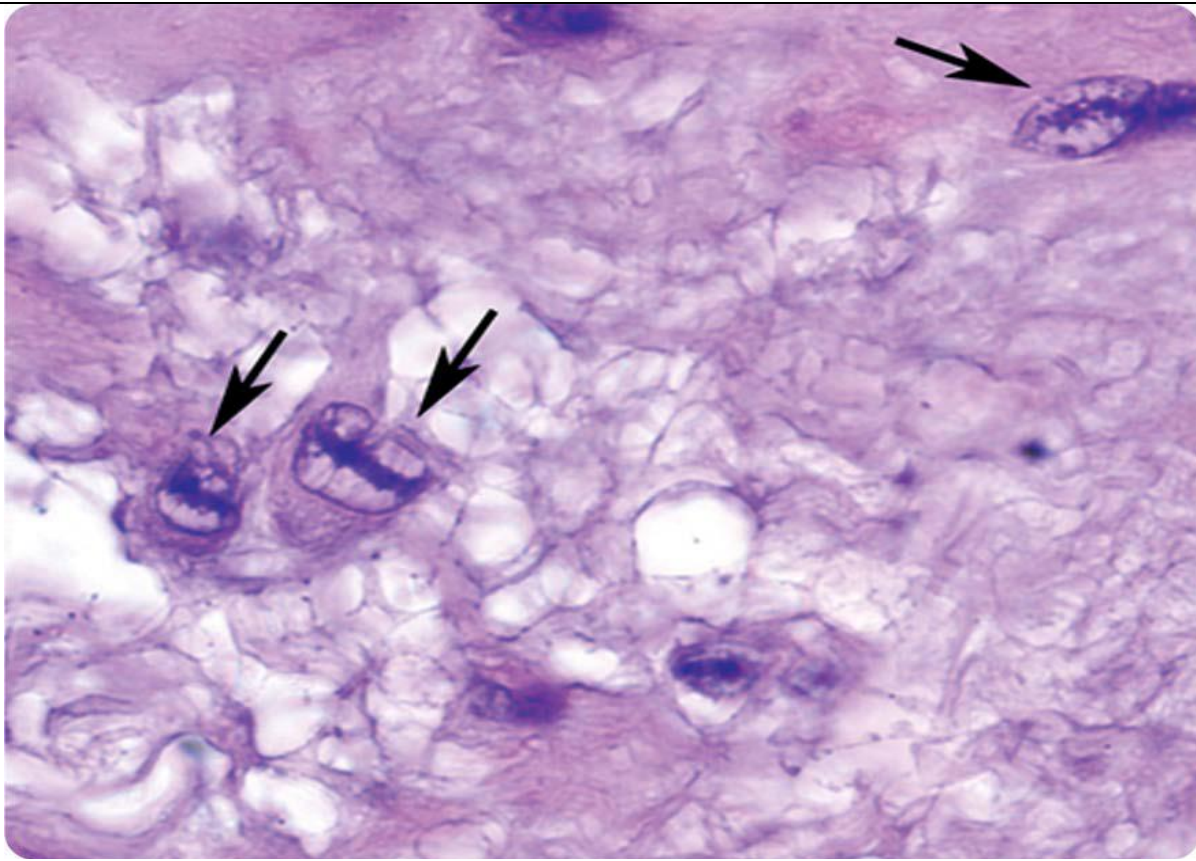


Figure 3.4. M/E: Anitschkow cells/Caterpillar cells (arrows), Present in the center of Aschoff bodies and identified by the presence of linear condensation of nuclear chromatin.

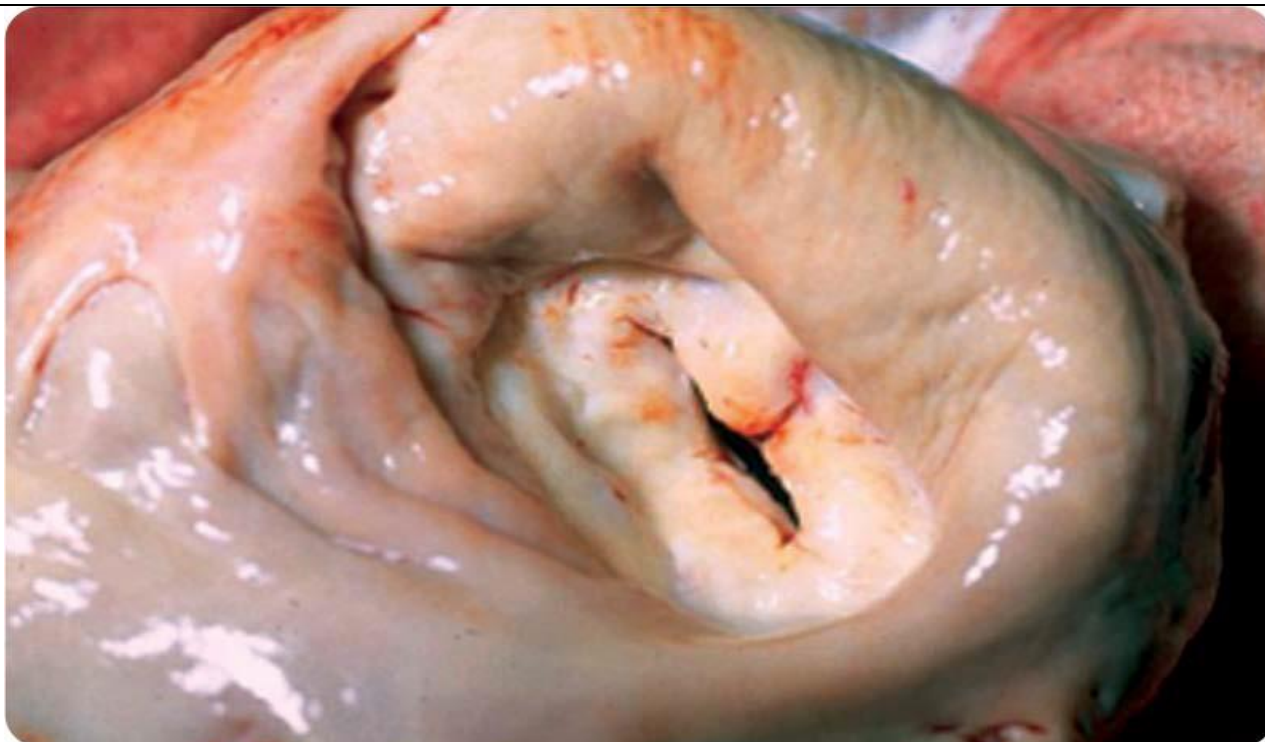


Figure. 3.5 G/a: complication of rhermatic heart disease: Autopsy specimen showing thickened mitral valve leaflets with stenosis.

Chapter Four

Respiratory System

Contents:**Learning Outcomes**

- Recognize the microscopic appearance of bacterial, viral and fungal pneumonias and pulmonary TB.
- Recognize under light microscope the histopathology slides of common respiratory conditions in infants, children and adults.
- Describe the gross and microscopic features of some lung disease due to inhalation of dust (pneumoconiosis).
- Describe the gross and microscopic features of lung cancer.

Pneumonia:

Pneumonia is any infection in the lung parenchyma distal to the terminal bronchioles (i.e. the respiratory bronchiole, alveolar ducts, alveolar sacs and alveoli).

Bacterial Pneumonia:

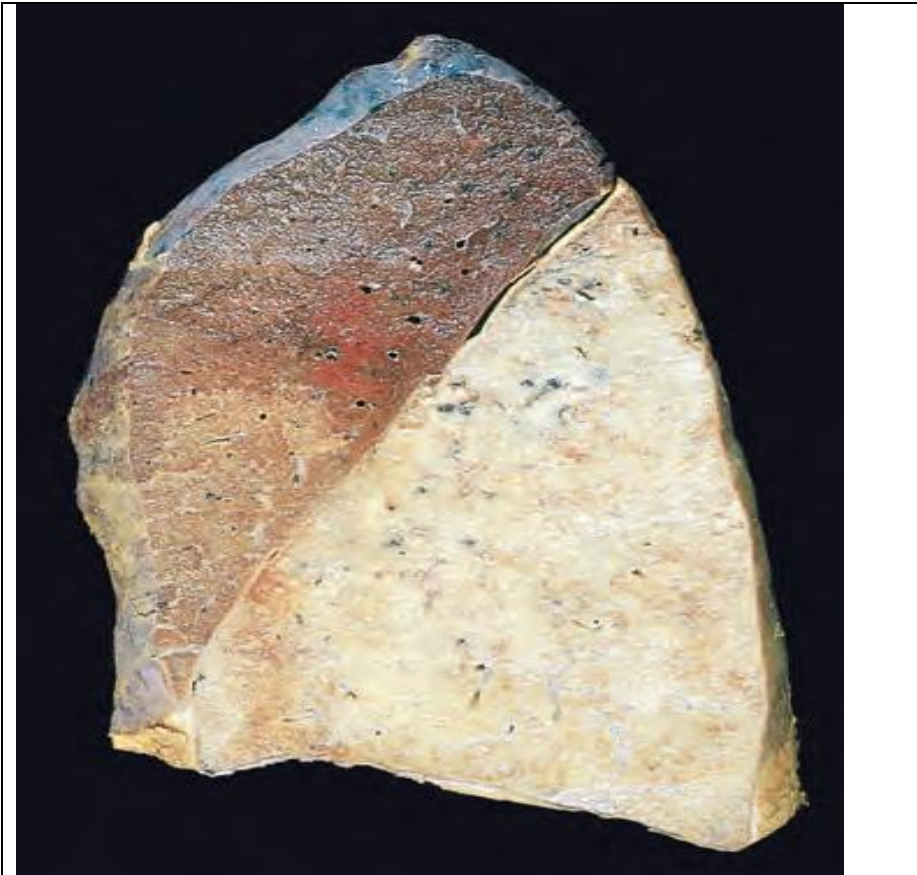


Figure: 4-1GA: Lobar pneumonia (gray hepatization). The lower lobe is uniformly consolidated.

Stages of bacterial pneumonia:

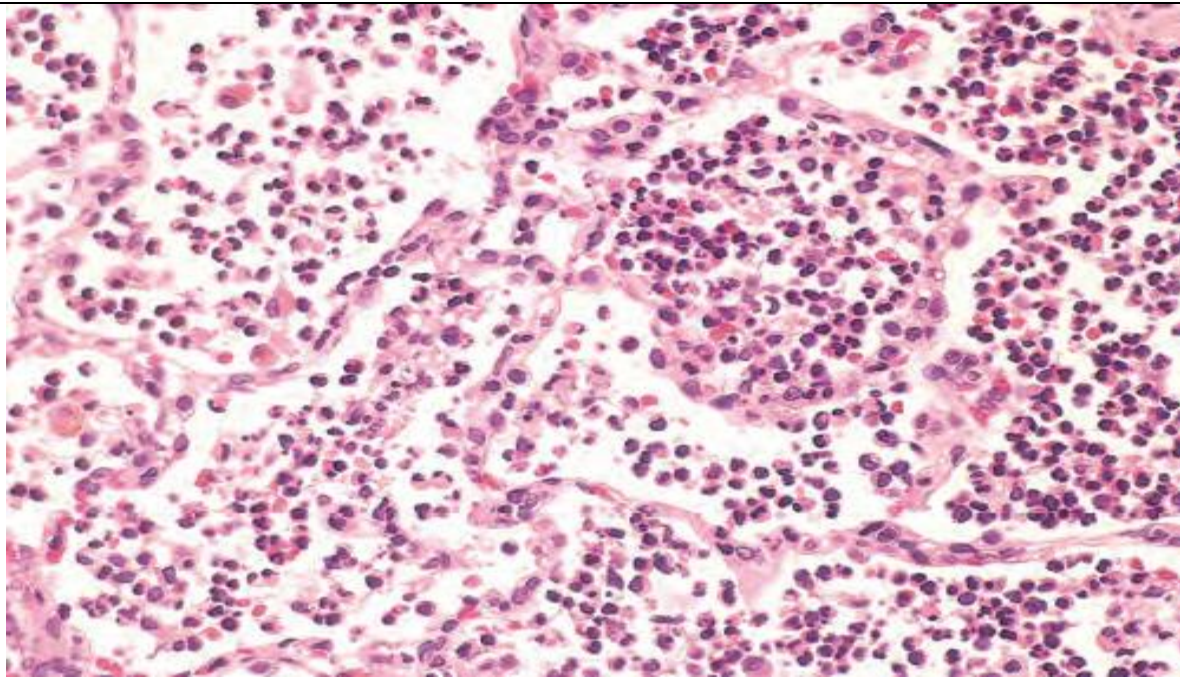


Figure: 4.4 Acute pneumonia. Early red hepatization. The septal capillaries are congested, and numerous intra-alveolar neutrophils are noted.

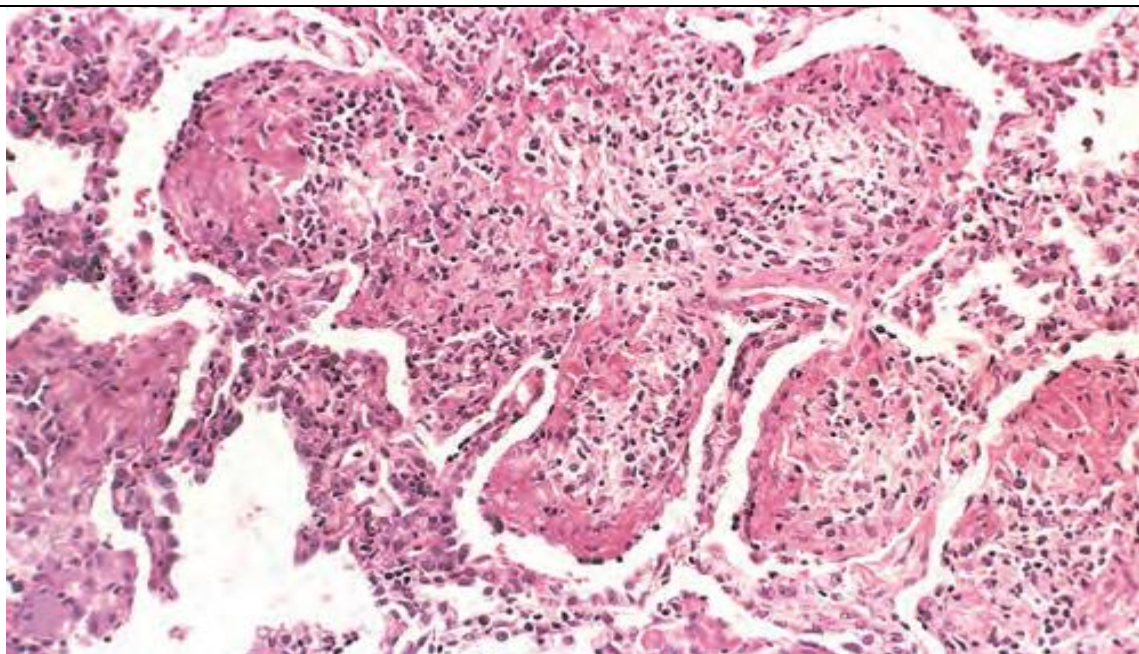


Figure: 4.5: M/E:Early organization of intra-alveolar exudate.

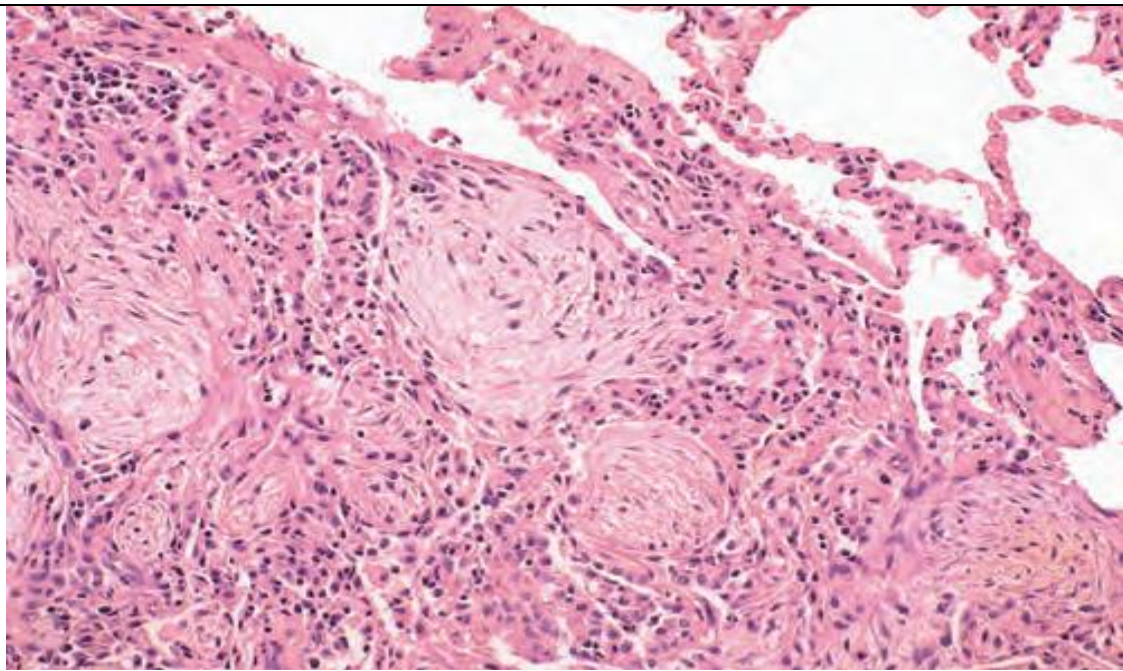


Figure: 4.6 M/E: Advanced organizing pneumonia. The exudates have been converted to fibromyxoid masses rich in macrophages and fibroblasts.

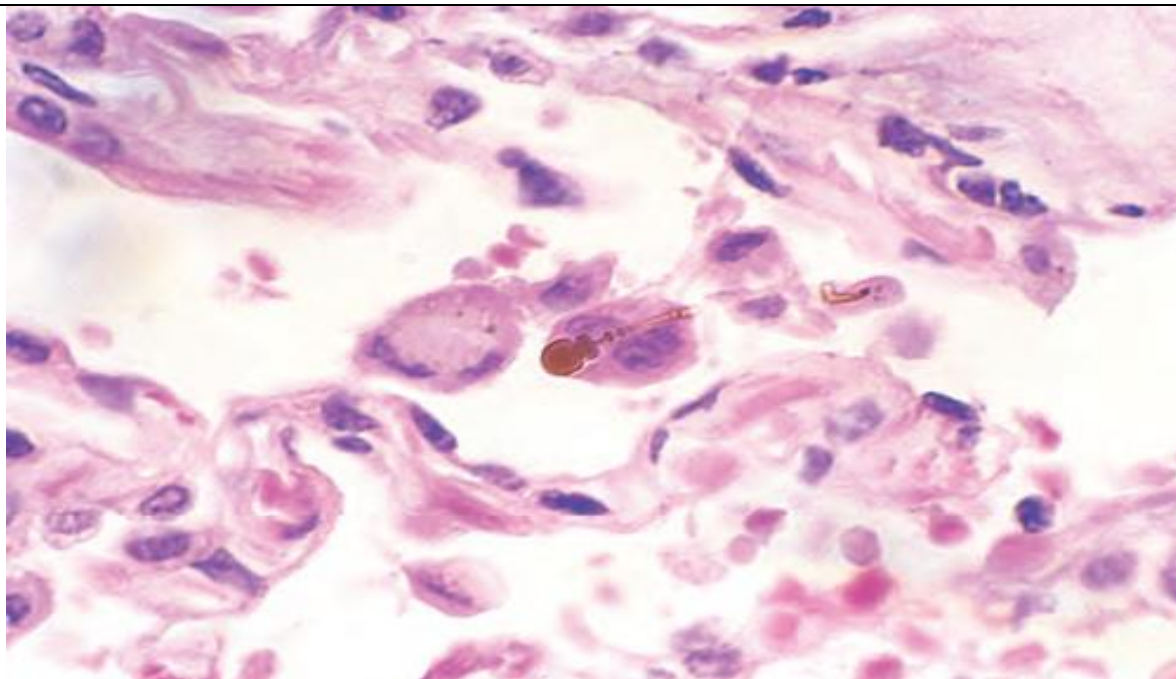


Figure: 4.7. M/E; Pneumoconiosis: Asbestos body, revealing the typical knobbed ends

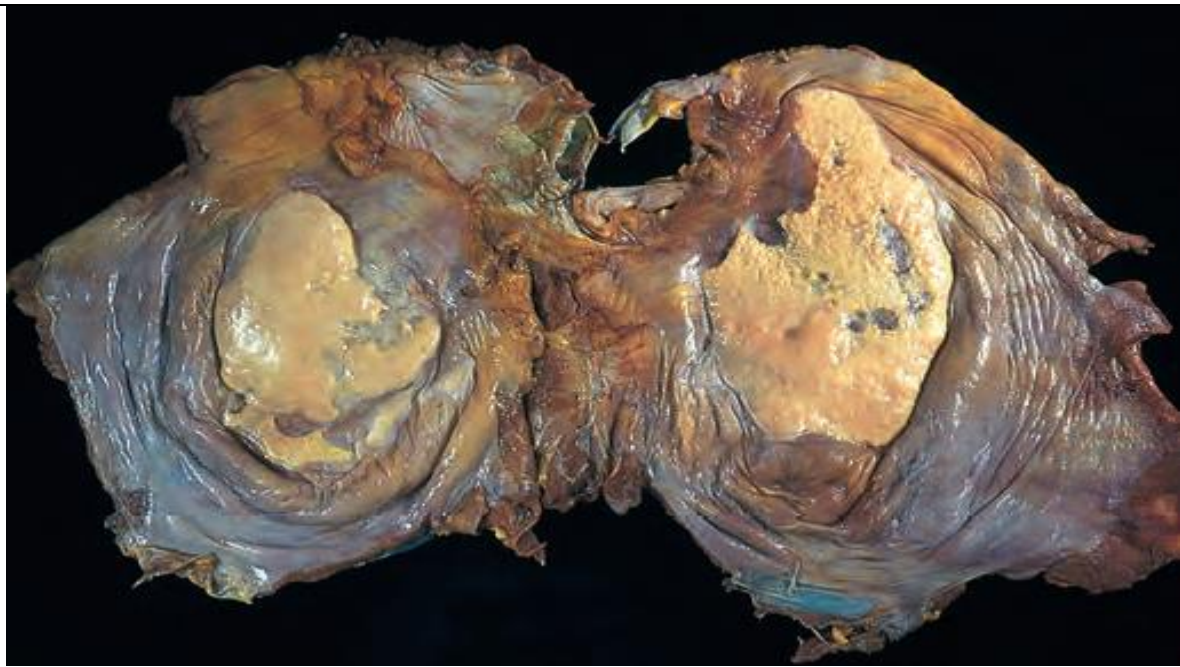


Figure: 4.8. G/A: Asbestos related pleural plaque.

Lung tumors:

Histologic Classification of Malignant Epithelial Lung Tumors:

- Adenocarcinoma: Arise from glands. 35% to 40%.
- Located periphery or centrally.
- Precursor lesions are atypical adenomatous hyperplasia (AAH).
- Most common type of cancer in women and non-smokers.

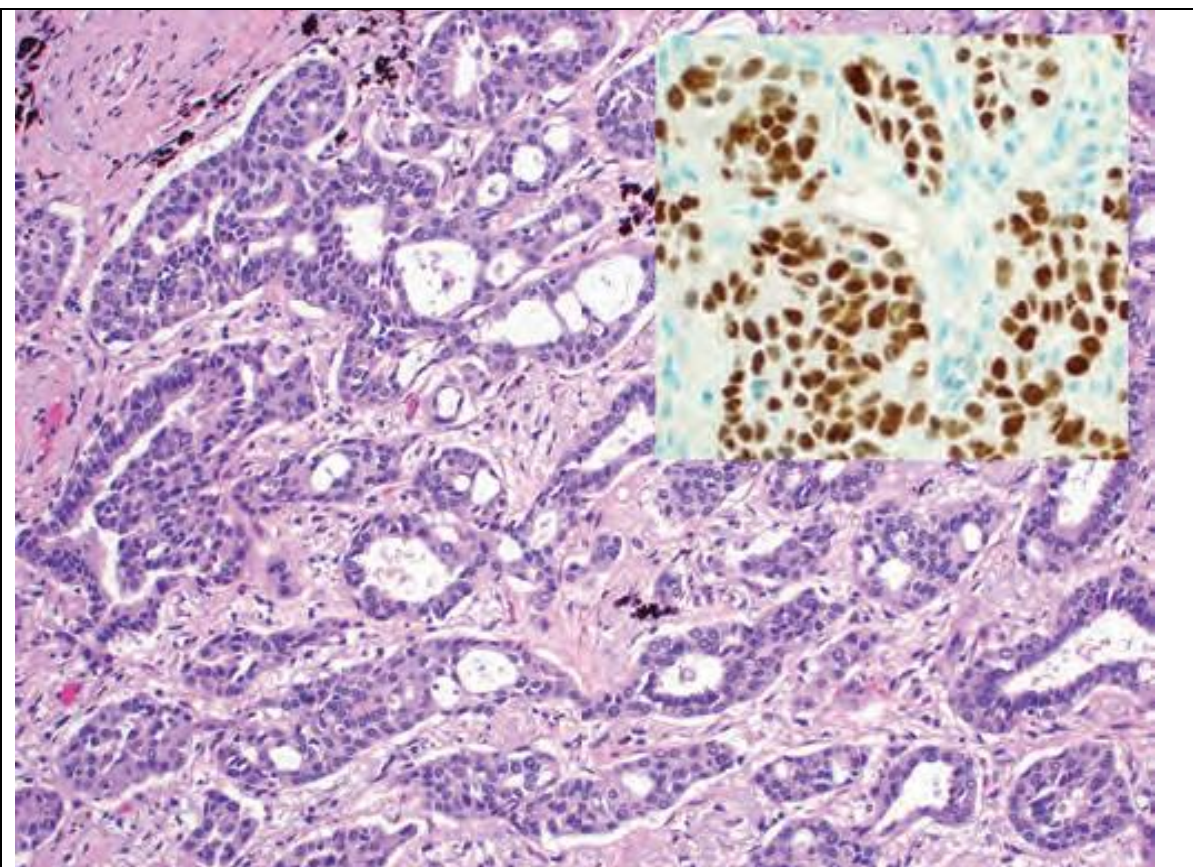


Figure 4-8: M/E: Gland-forming adenocarcinoma. (H&E stain) inset shows thyroid transcription factor 1 (TTF-1) (Immunohistochemical stain)

Squamous cells carcinoma: epithelium of squamous mucosa.

- 20% to 30% of lung cancers.
- Central location.
- This is usually preceded by squamous metaplasia and dysplasia and later transform into carcinoma in situ.

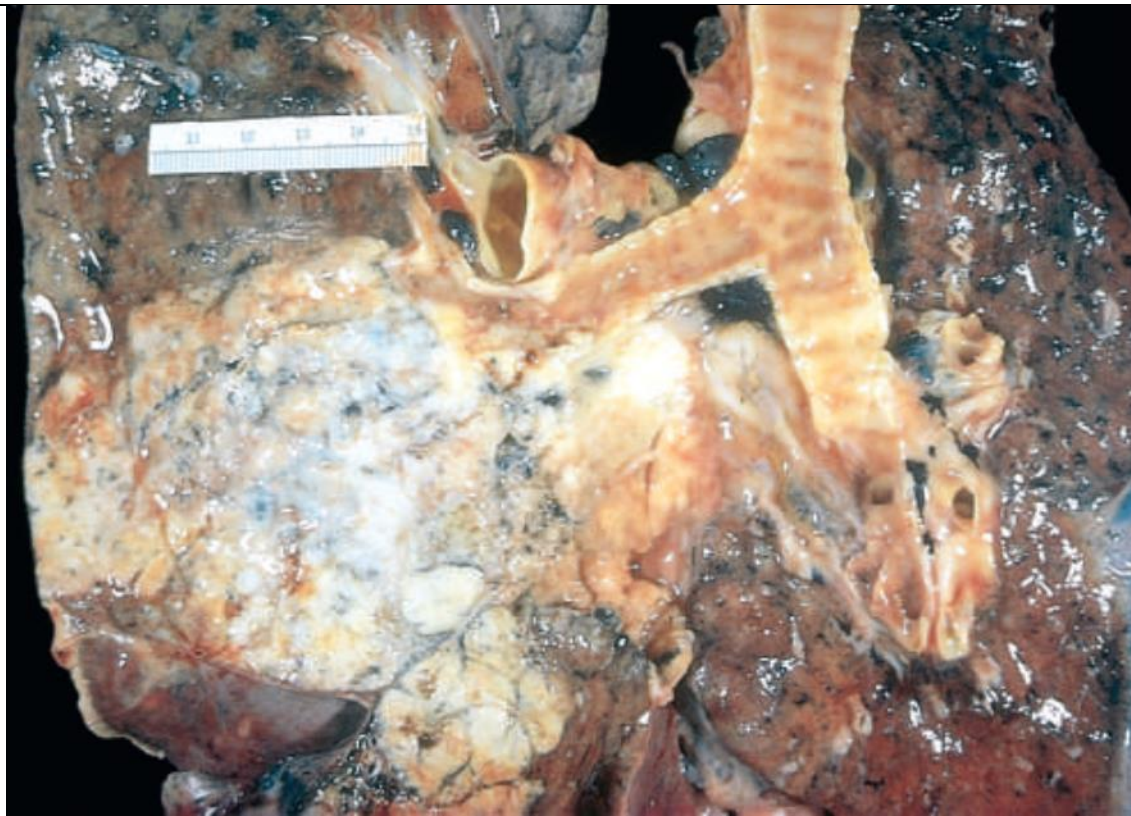

Figure: 4-9 G/A: squamous cell carcinoma of a large bronchus. The tumor is whitish in color and infiltrating the lung.

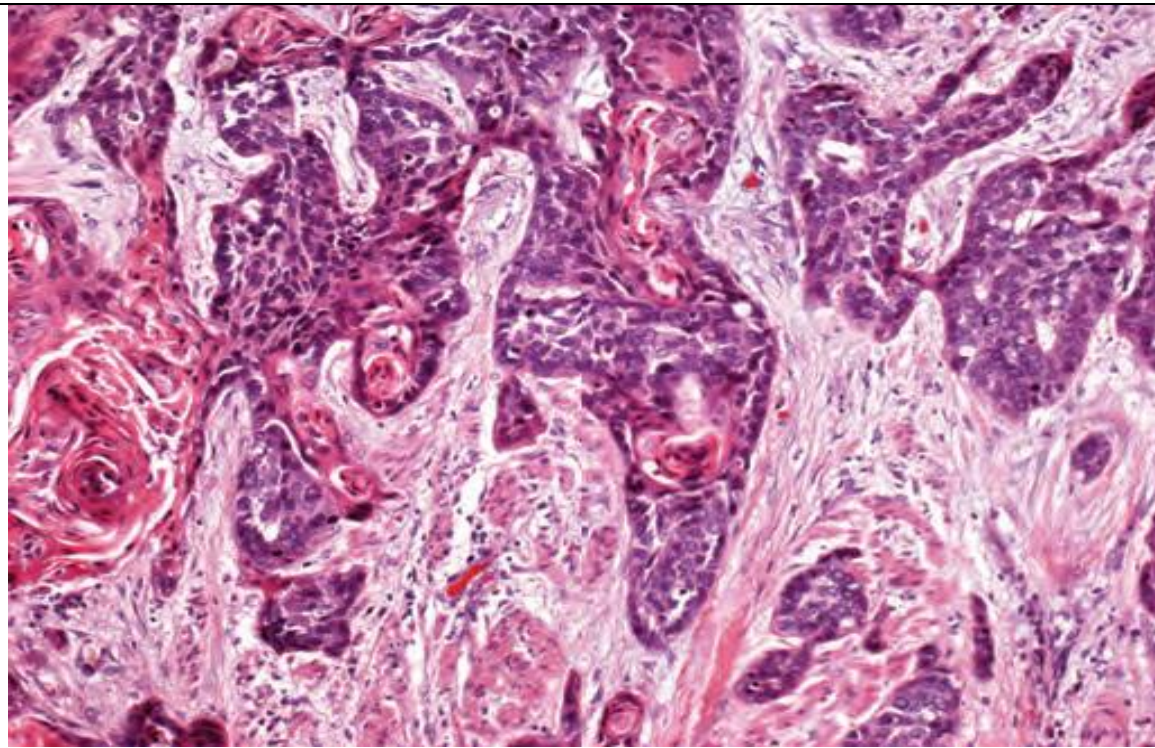


Figure: 4-10 M/E: Well-differentiated squamous cell carcinoma showing keratinization

Large cell carcinoma:

- High grade carcinoma composed of large cell or anaplastic morphology with no specific histologic features of differentiation.

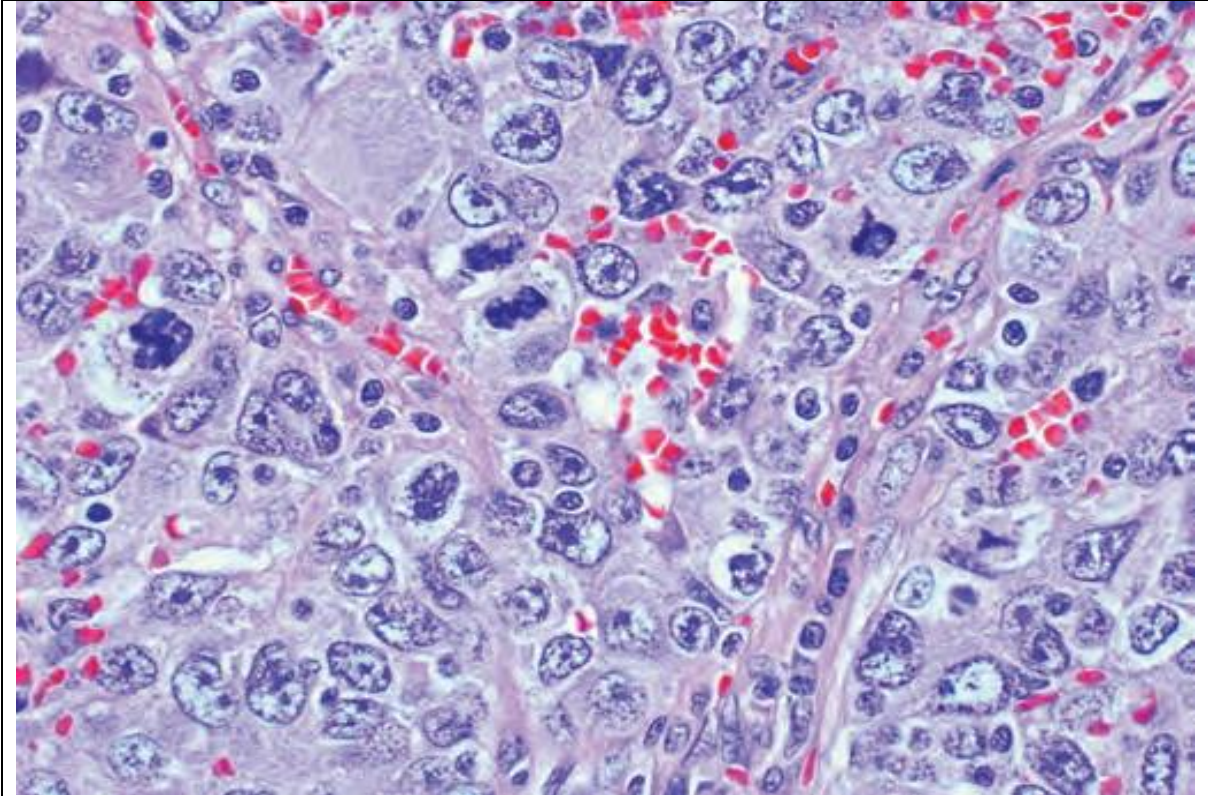


Figure: 4-11 M/E large cell carcinoma composed of sheets of large cells with marked pleomorphism and increased mitosis

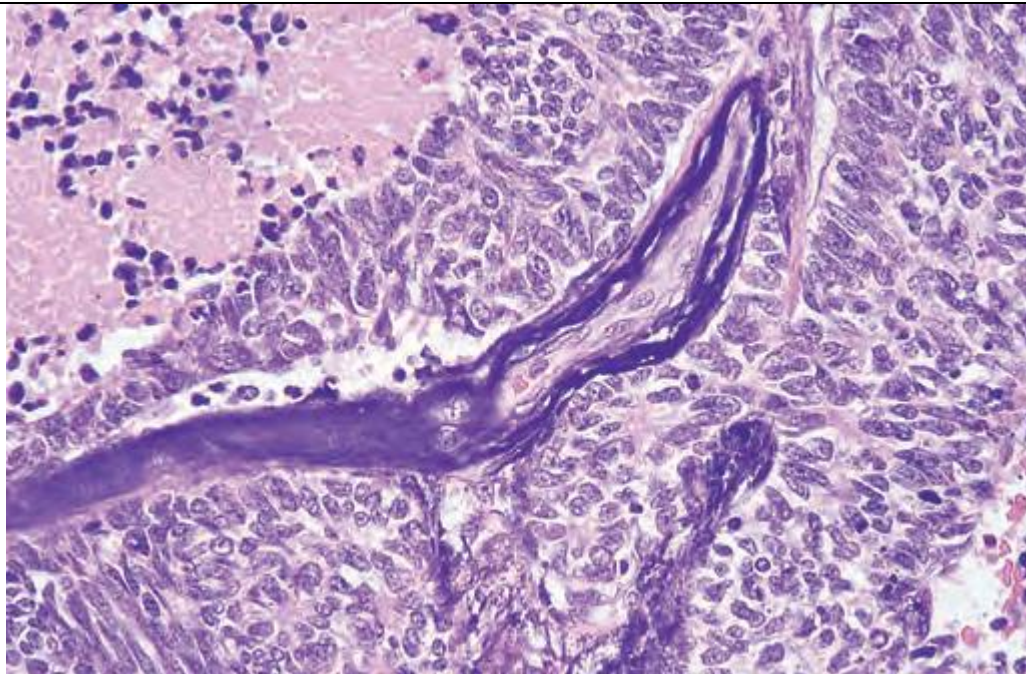


Figure: 4-12 M/E: microscopic appearance of small lung carcinoma of the lung

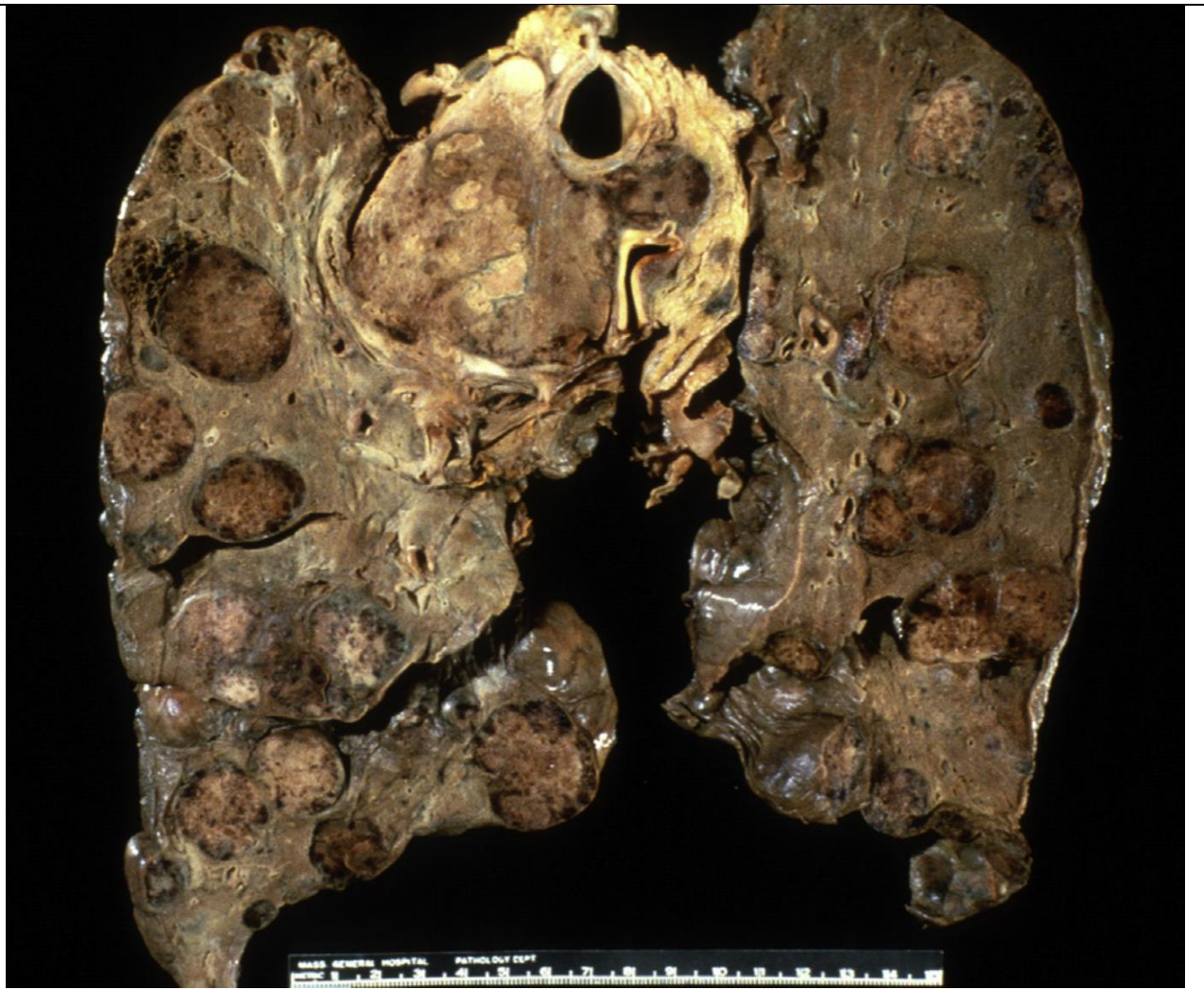


Figure: 4-13 G/A: Multiple lung metastasis, lung is common site for metastasis from different types of tumors due to rich blood supply.

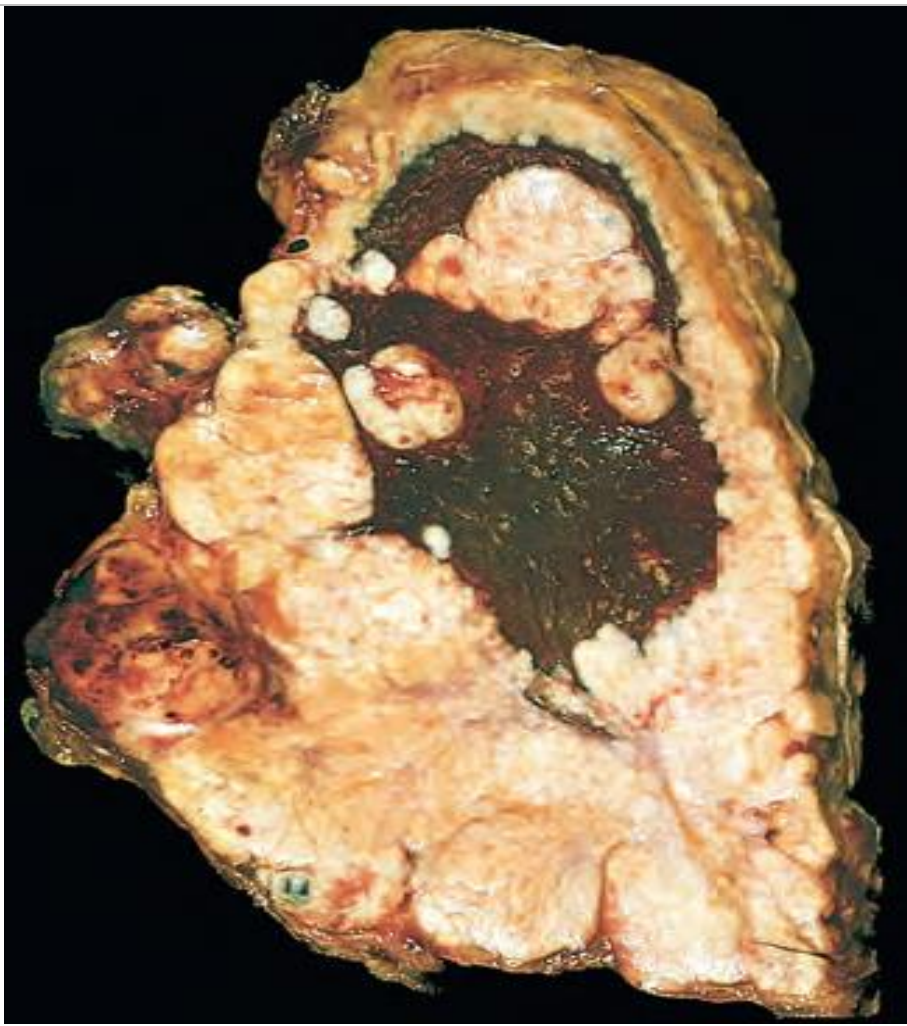

Figure: 4-14 Malignant mesothelioma. Note the thick, firm, white pleural tumor tissue that surrounding the lung.

Chapter Five

Musculoskeletal system

Contents

Learning Outcomes

- Describe the gross and microscopic changes produced in the course of bone infections.
- Describe the main gross differences between osteoporosis and osteomalacia.
- Describe the pathological changes, complications of infectious arthritis.
- Identify the pathologic changes in gross and microscopy in patients with non- infectious arthritis.

Osteomalacia:

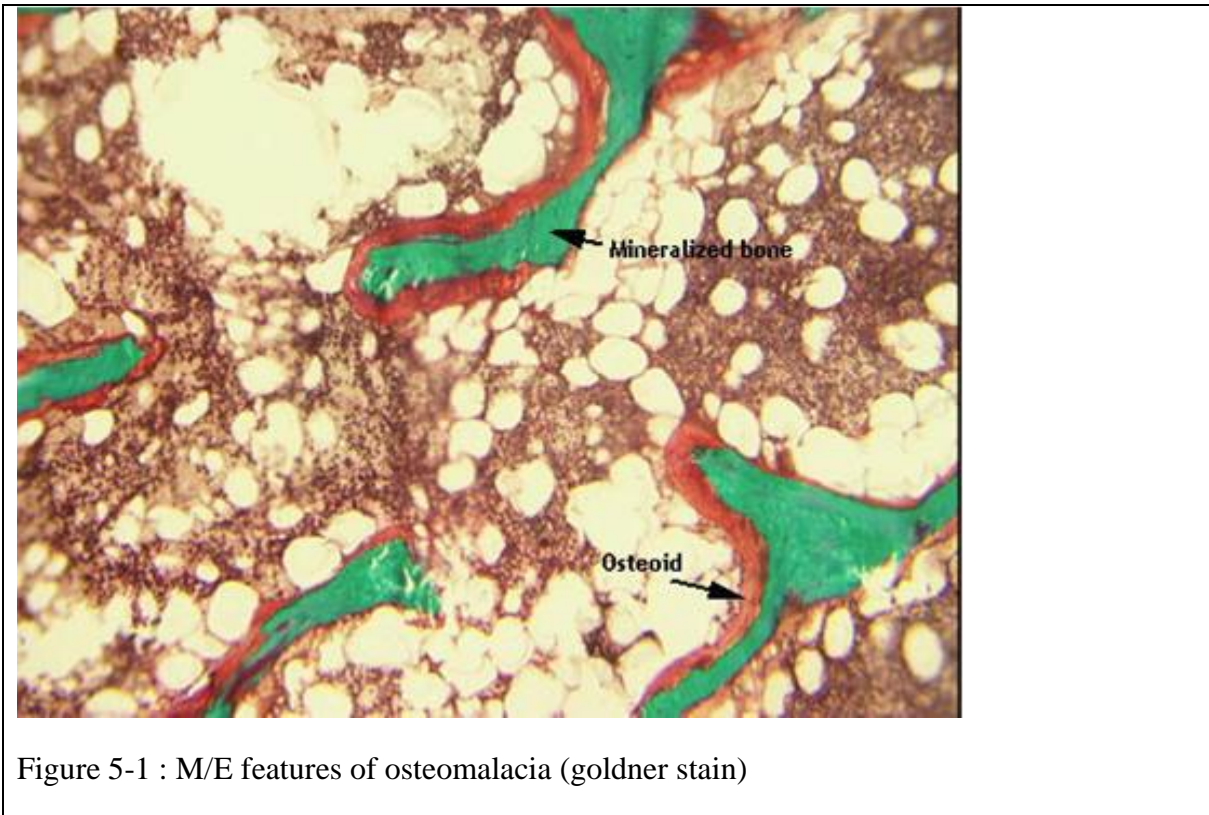


Figure 5-1 : M/E features of osteomalacia (goldner stain)

Osteoporosis

- Osteoporosis is a disease characterized by increased porosity of the skeleton resulting from reduced bone mass.
- May be localized to a certain bone or region, as in disuse osteoporosis of a limb, or may involve the entire skeleton, as a manifestation of a metabolic bone disease.
- Normally there is a dynamic equilibrium between bone formation by osteoblasts, maintenance by osteocytes, and resorption by osteoclasts.
- Osteoporosis occurs when the balance tilts in favor of resorption.

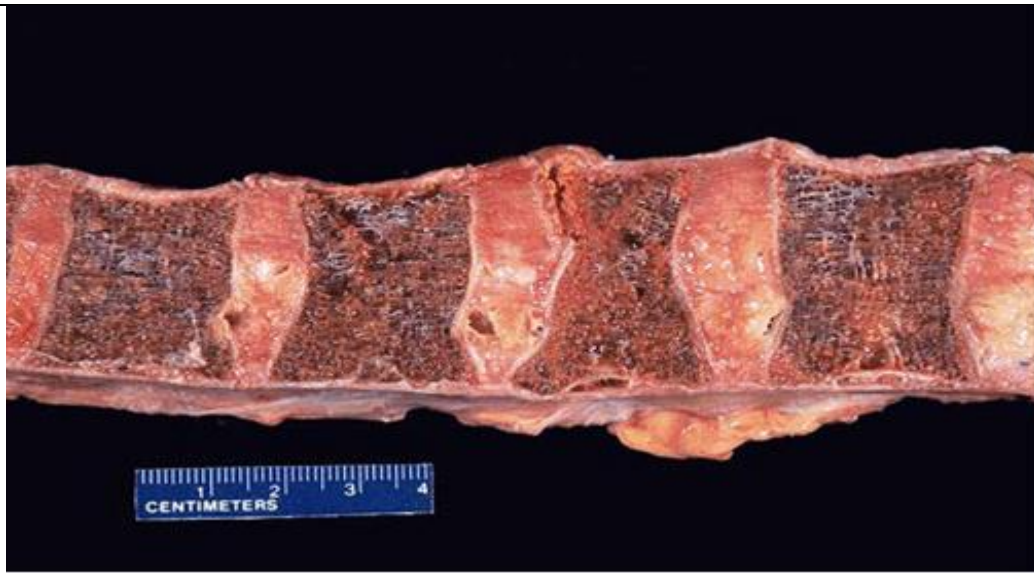

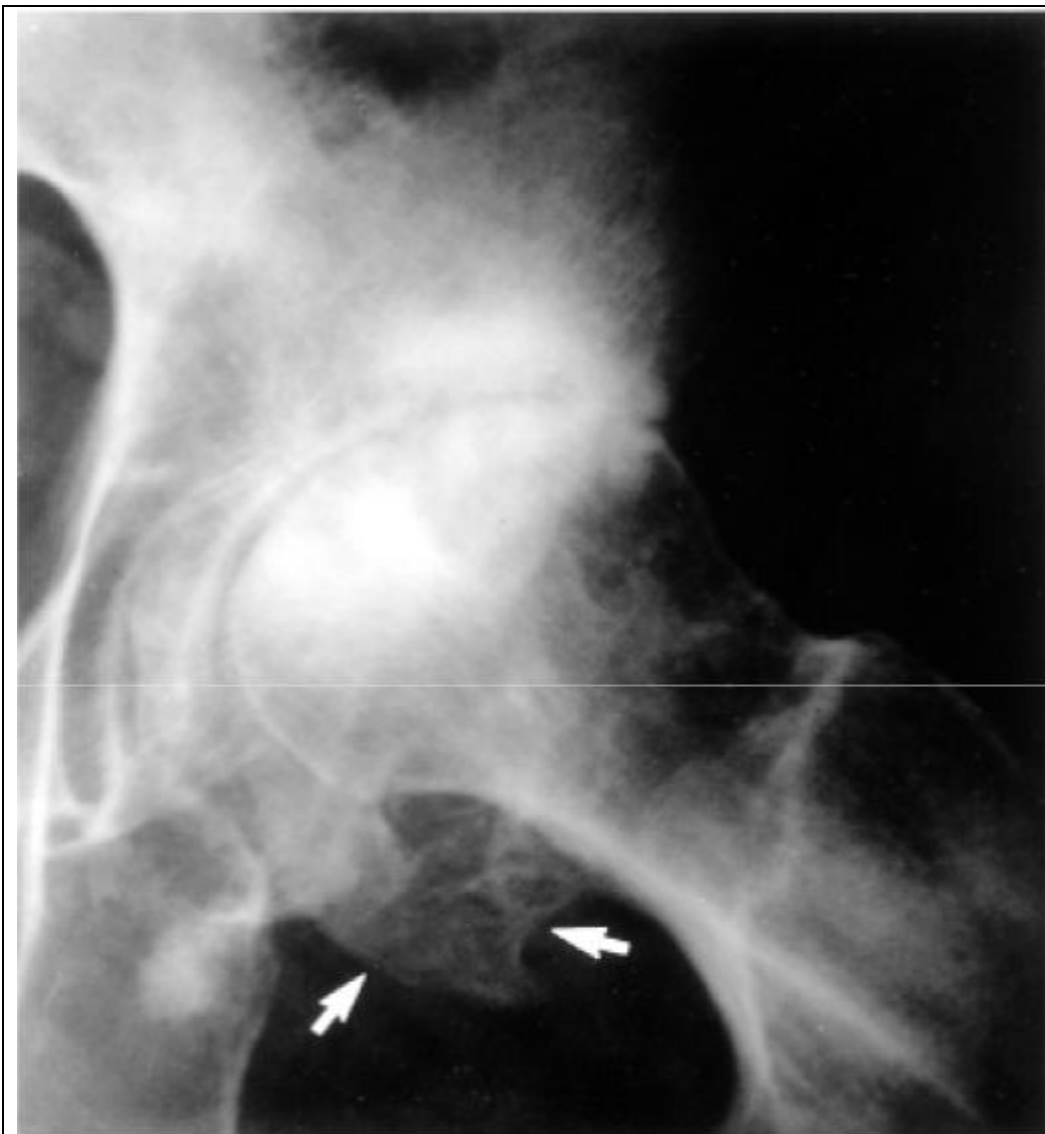
Figure 5-2: features of osteoporosis, loss of vertebral height

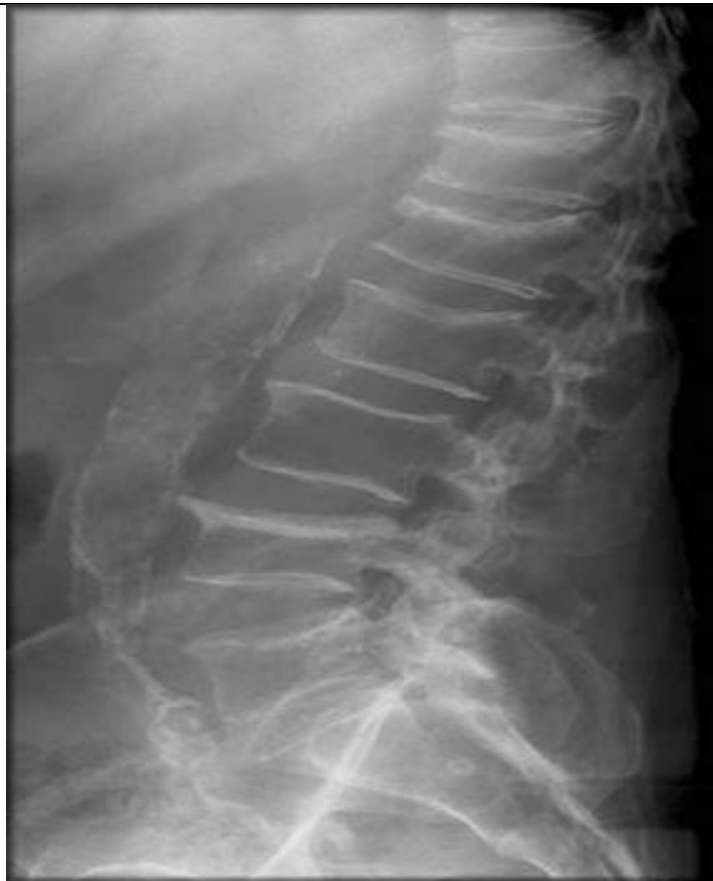

Figure 5-3: features of osteoporosis, compression fractures

Osteoarthritis:

- Also known as osteoarthrosis and atrophic arthritis.
- it is a slowly progressive, degenerative disease of di-artrodial (synovial) joints that characterize by destruction of articular cartilage which leads to narrowing of joint, subchondral bone thickening, and finally nonfunctioning painful joints.



Slide 3: Features of osteoarthritis

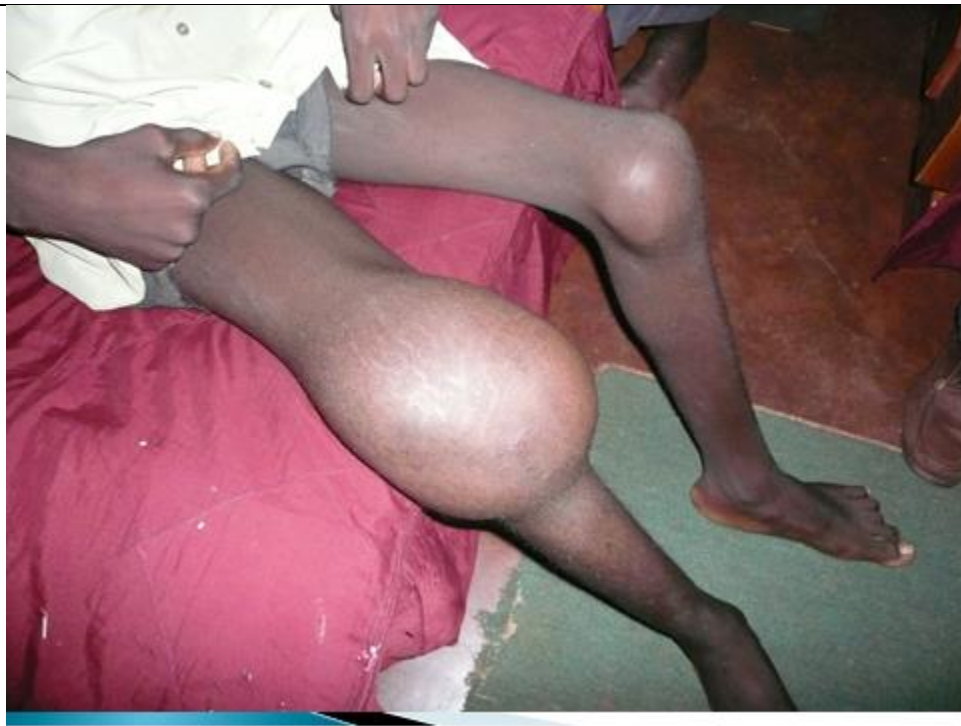

Figure: Heamoarthritis

Chapter 6

Gastrointestinal system

Objectives of GIT Pathology Practical:

(A): Oral cavity:

- 1- Describe the diseases of the oral cavity like ulcerative stomatitis, candidiasis and aphthous ulcers.
- 2- Explain the pathogenesis of common salivary gland tumors.

Procedures:

- To observe and review the morphological features and pathological changes of above diseases of oral cavity:

Materials:

- Microscopes.
- H & E Stained slides.
- Images of gross changes seen in oral cavity disease.
- Images of diagnostic microscopic features of GIT diseases.

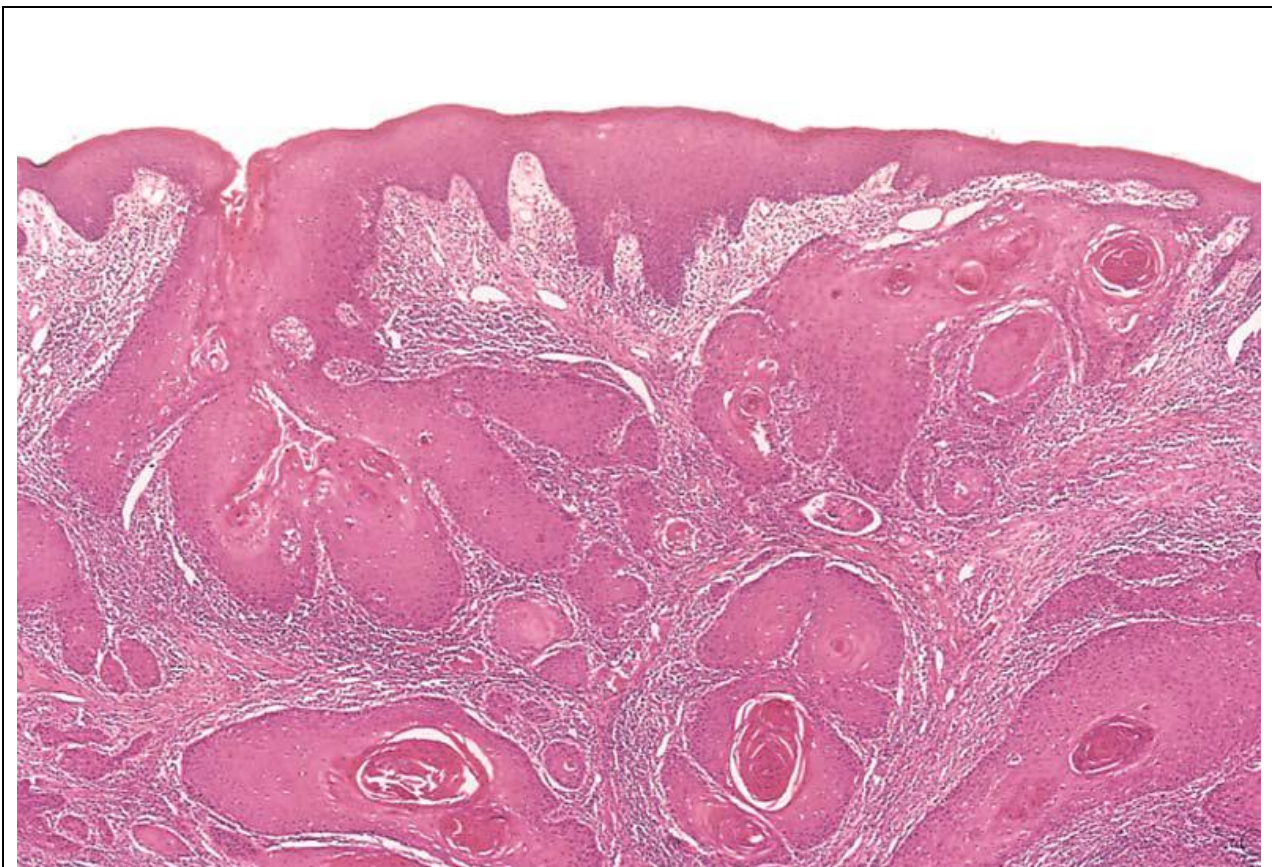


Figure -1: squamous cell carcinoma of oral cavity.

(B): Pathology of the esophagus

1. Outline the common inflammatory diseases and other benign diseases affecting the esophagus, and explain their pathophysiology, complications, investigative procedures and management ((C1).
2. Outline the malignant diseases affecting the esophagus, and explain their pathophysiology, complications, investigative procedures and management (C1).

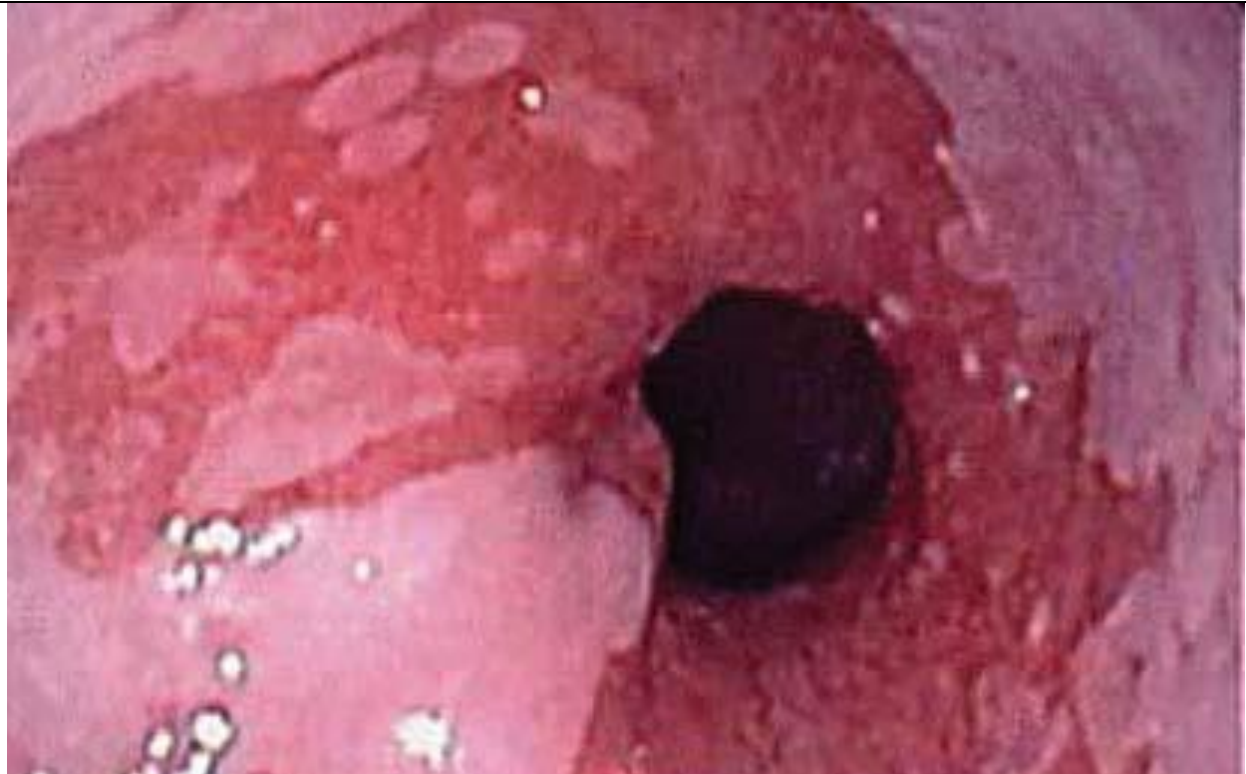


Figure -2 Endoscopic features of Barrett's esophagus

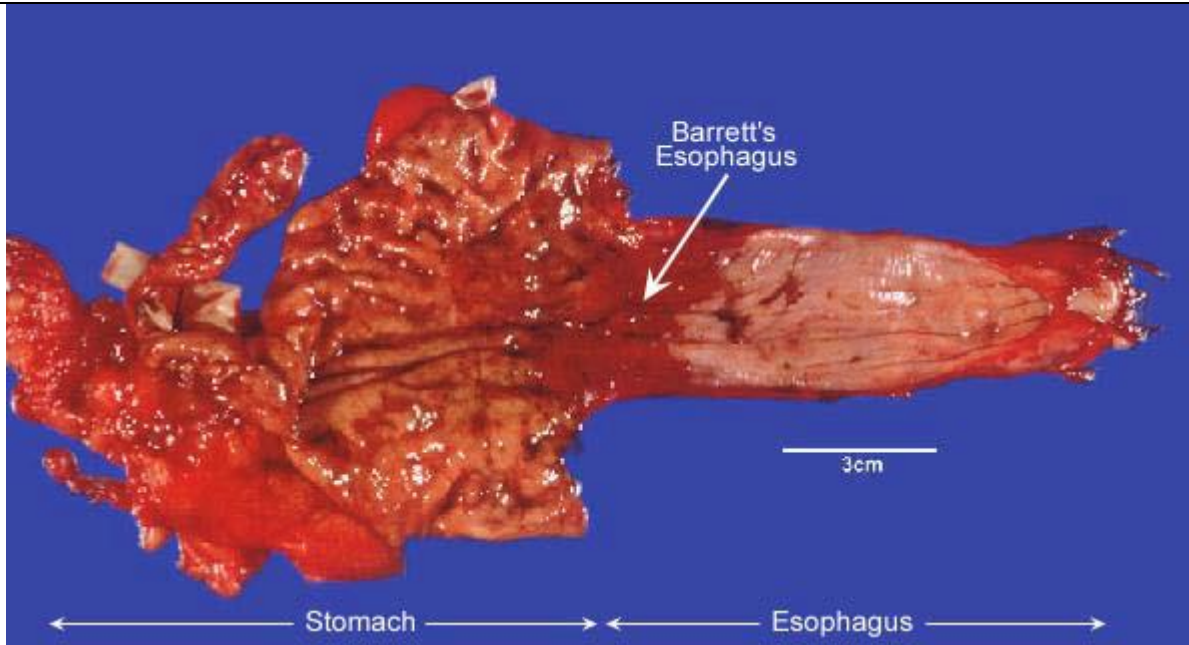


Figure -3 gross morphology of Barrett's esophagus

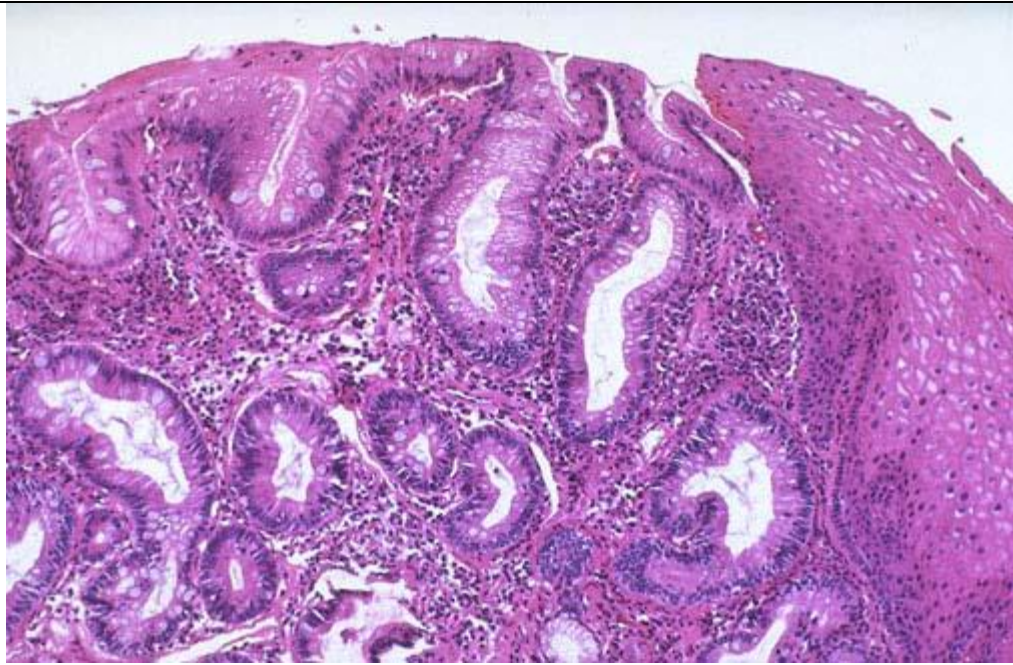


Figure: microscopic features of Barrett's esophagus

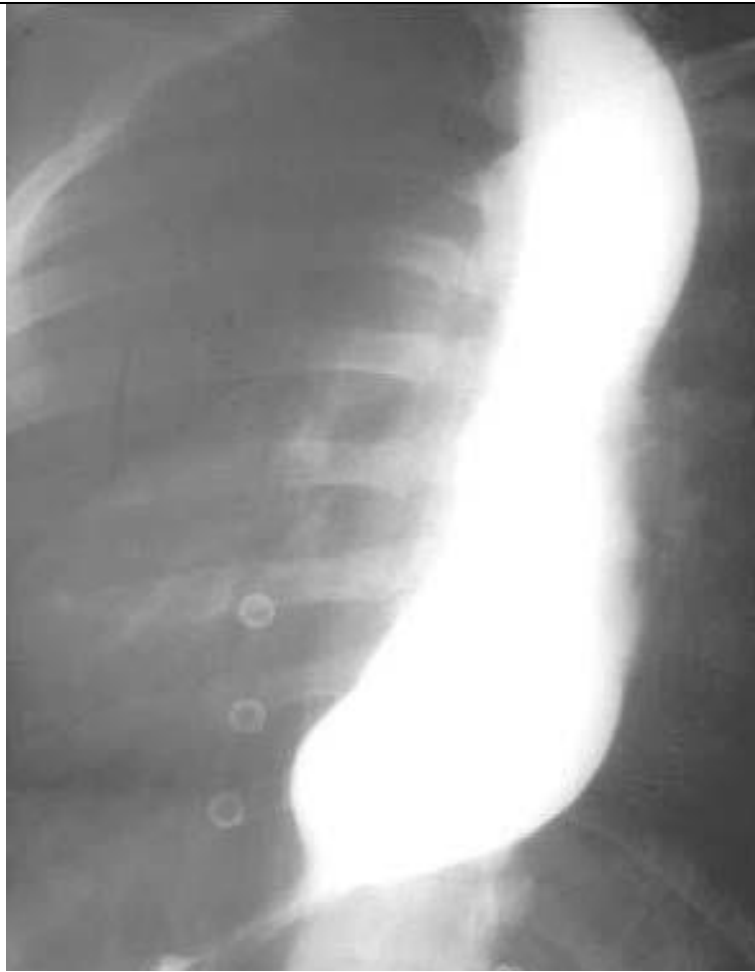


Figure barium enema of esophagus, in achalasia.

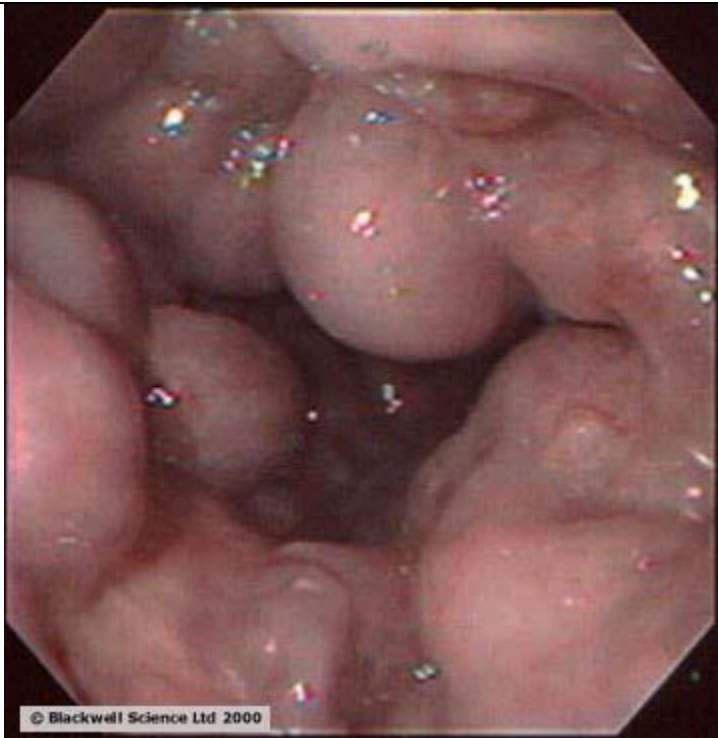


Figure: endoscopy of esophageal varices

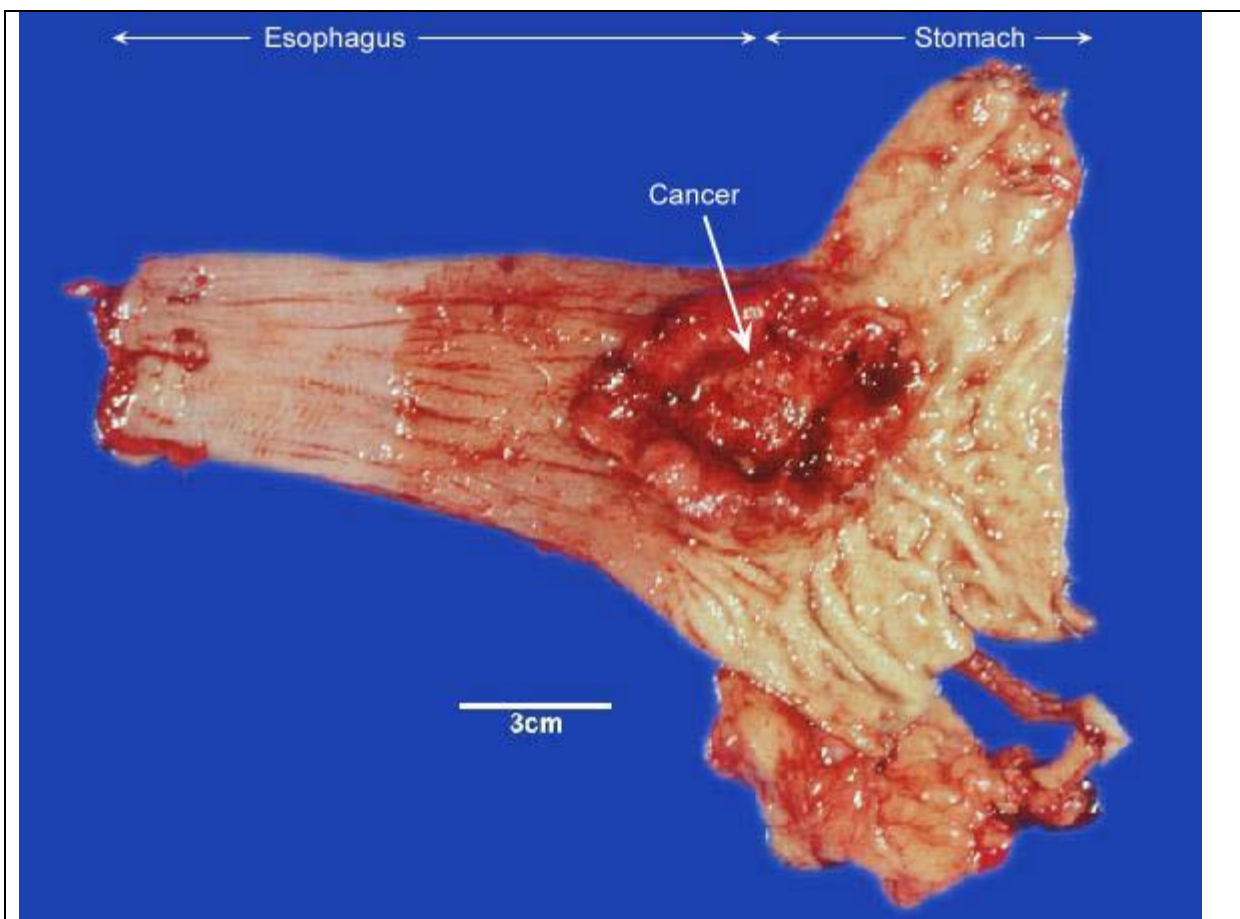


Figure -4 esophageal carcinoma.

Stomach:

1. List the inflammatory conditions affecting the stomach and their complications (C1).
2. Describe the causes and presentation of stomach ulcer and outline management, prevention and complications (C1).
3. List the neoplastic diseases affecting the stomach (C1)

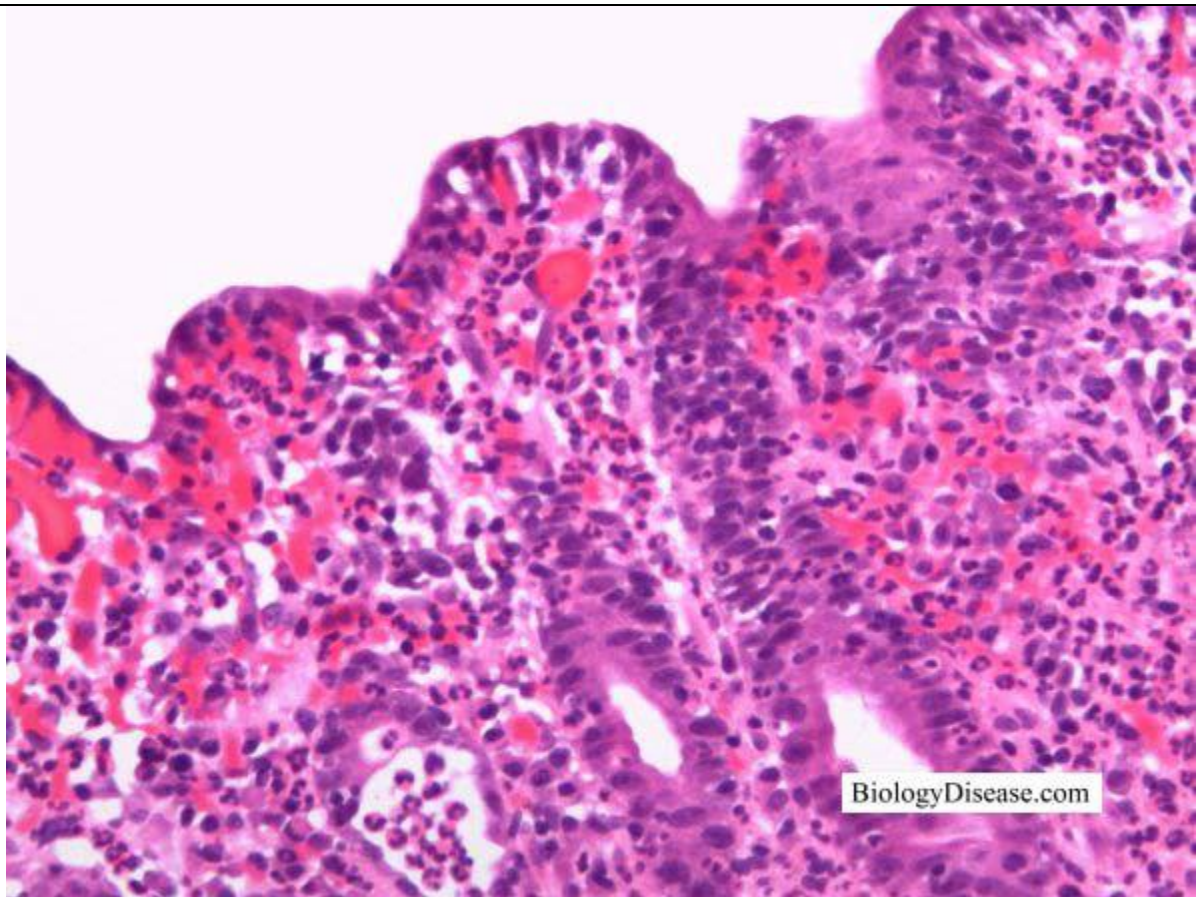


Figure: H pylori associated gastritis (H& E stain)

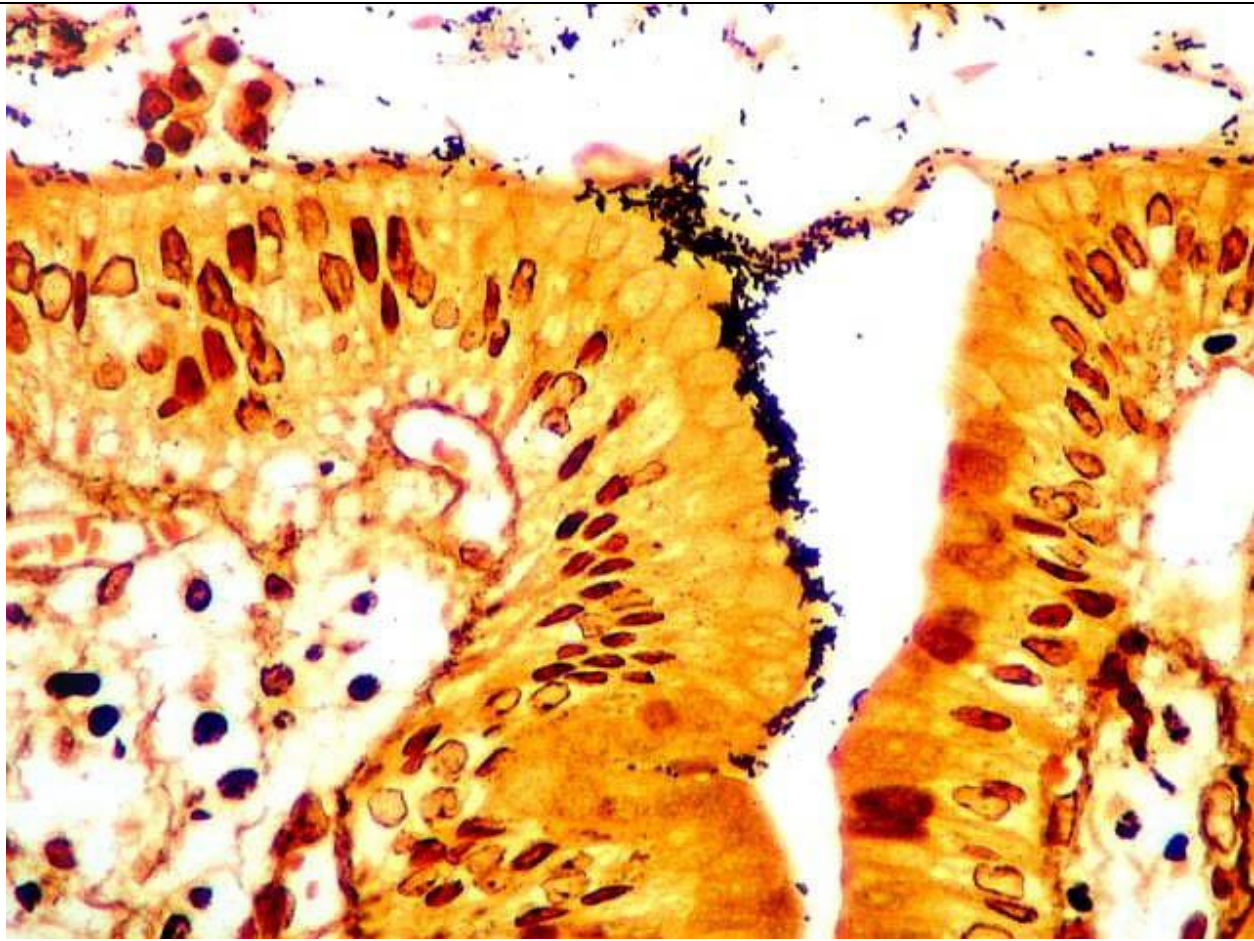


Figure: H pylori associated gastritis (silver stain)

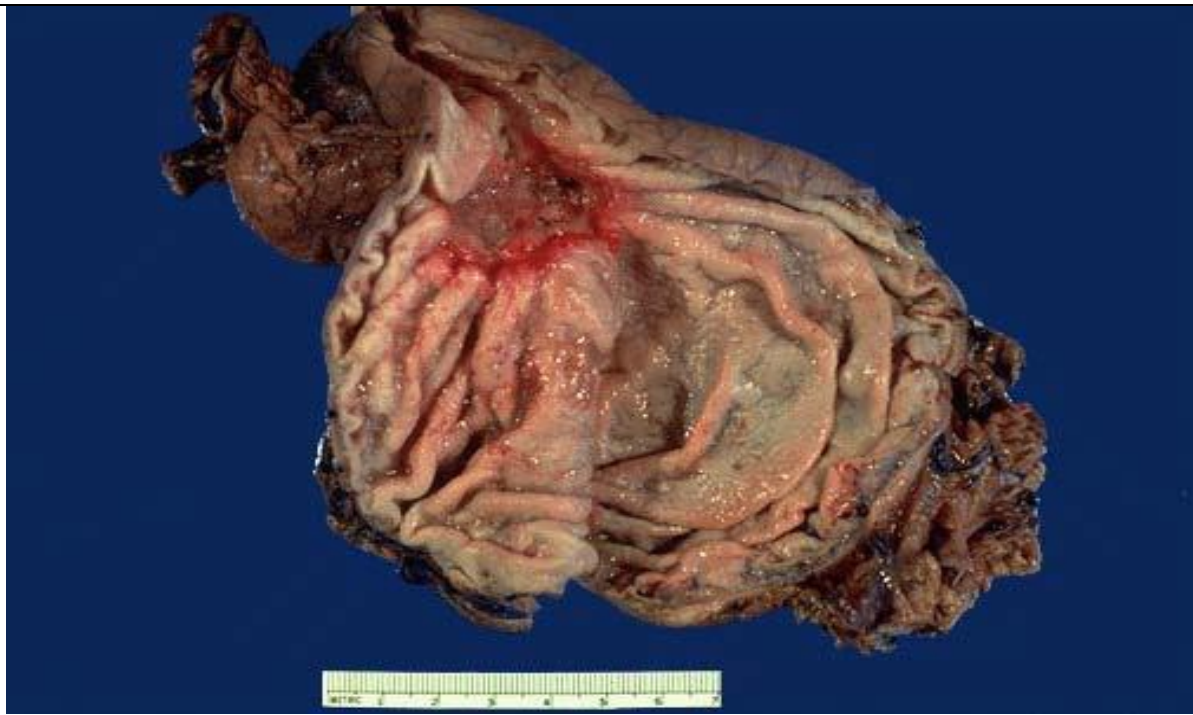

Figure: gross morphology of peptic ulcer diseases

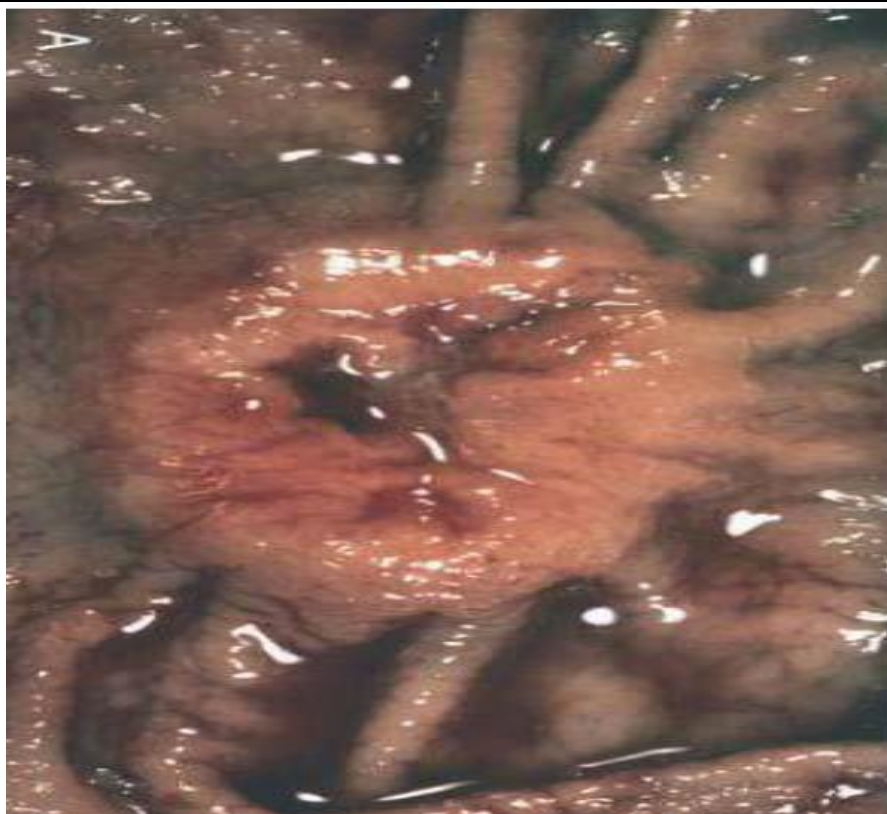
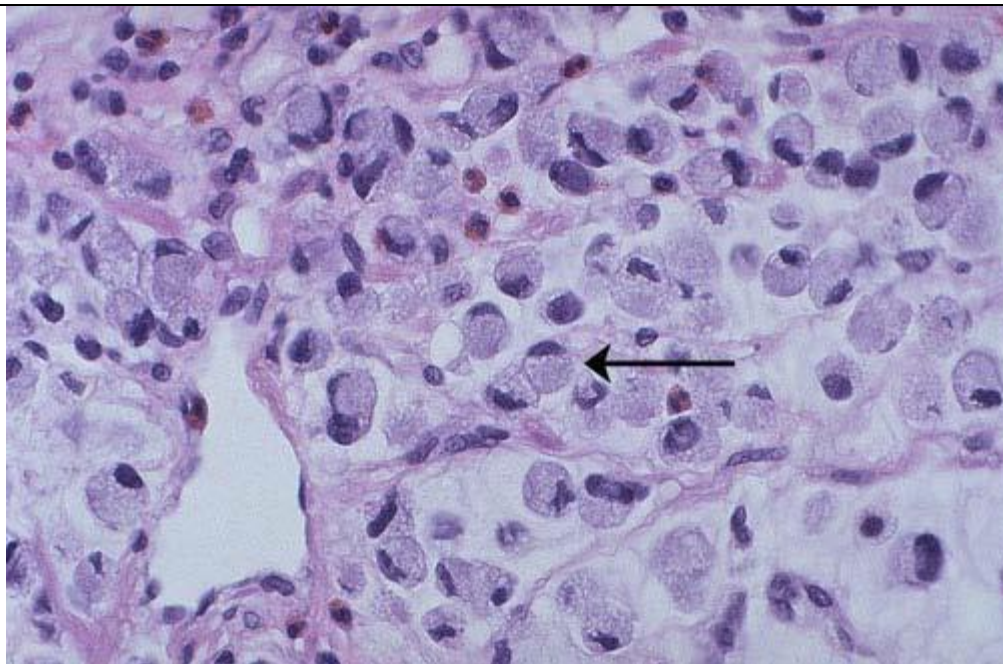


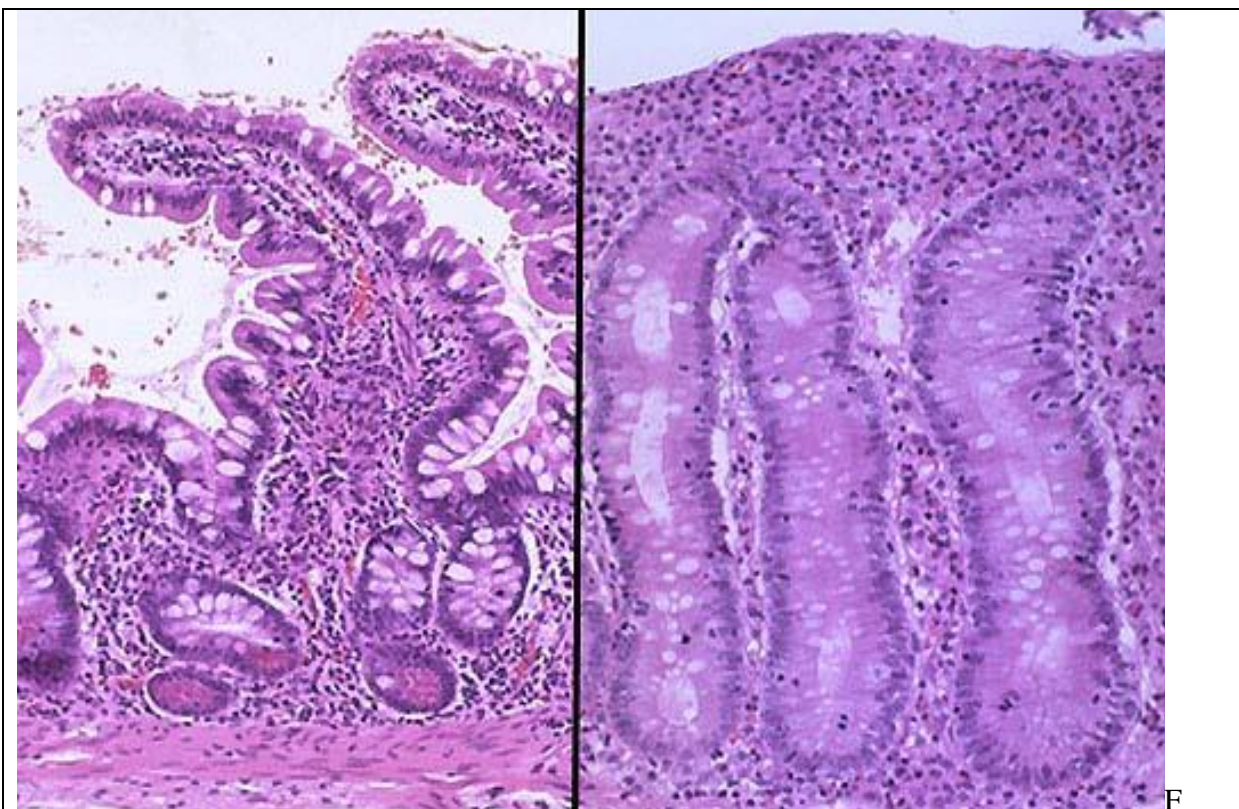
Figure: gastric ulcer.

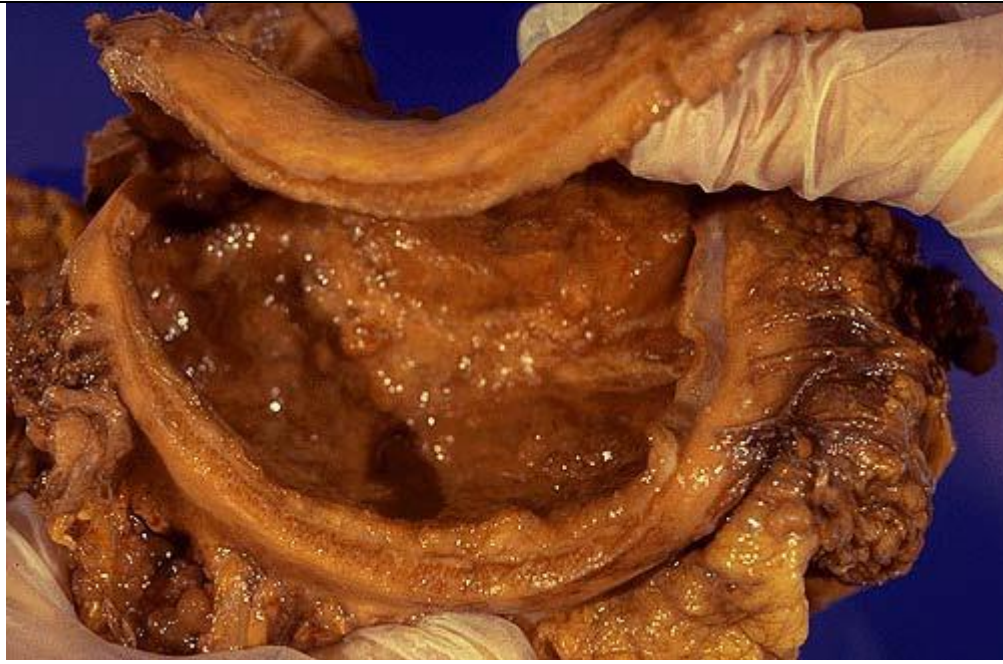

Figure: gastric carcinoma, lentis plastic.



Figure; gastric adenocarcinoma, signet ring type.



Features of celiac disease (Lt. is normal), flat villi with heavy lymphocytic inflammatory infiltrate (right)

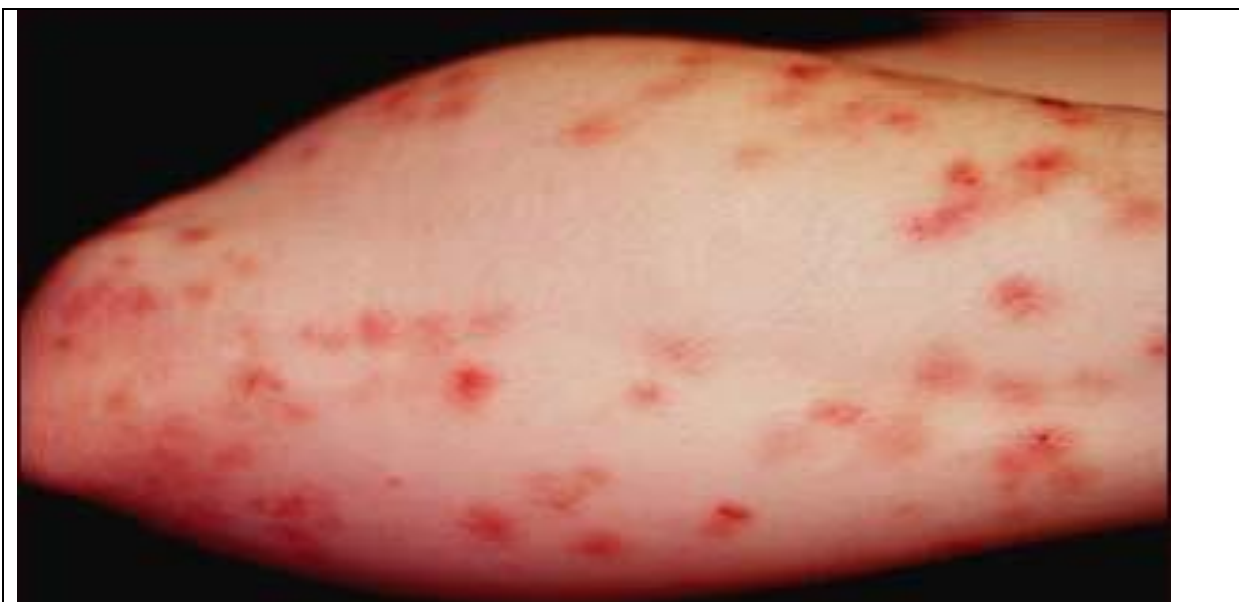

Figure: GA: Dermatitis herpetiformis dermatological manifestations of celiac disease,

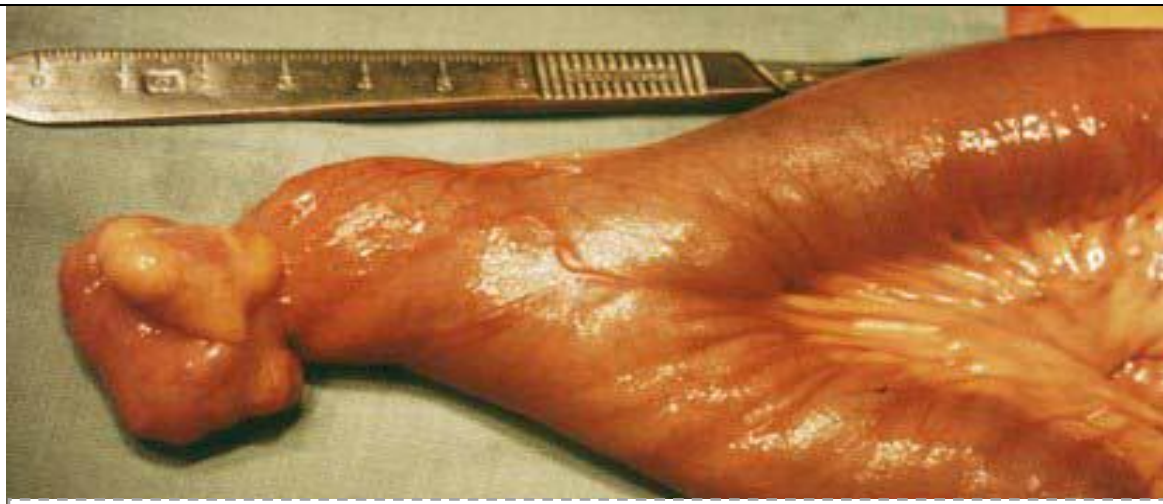
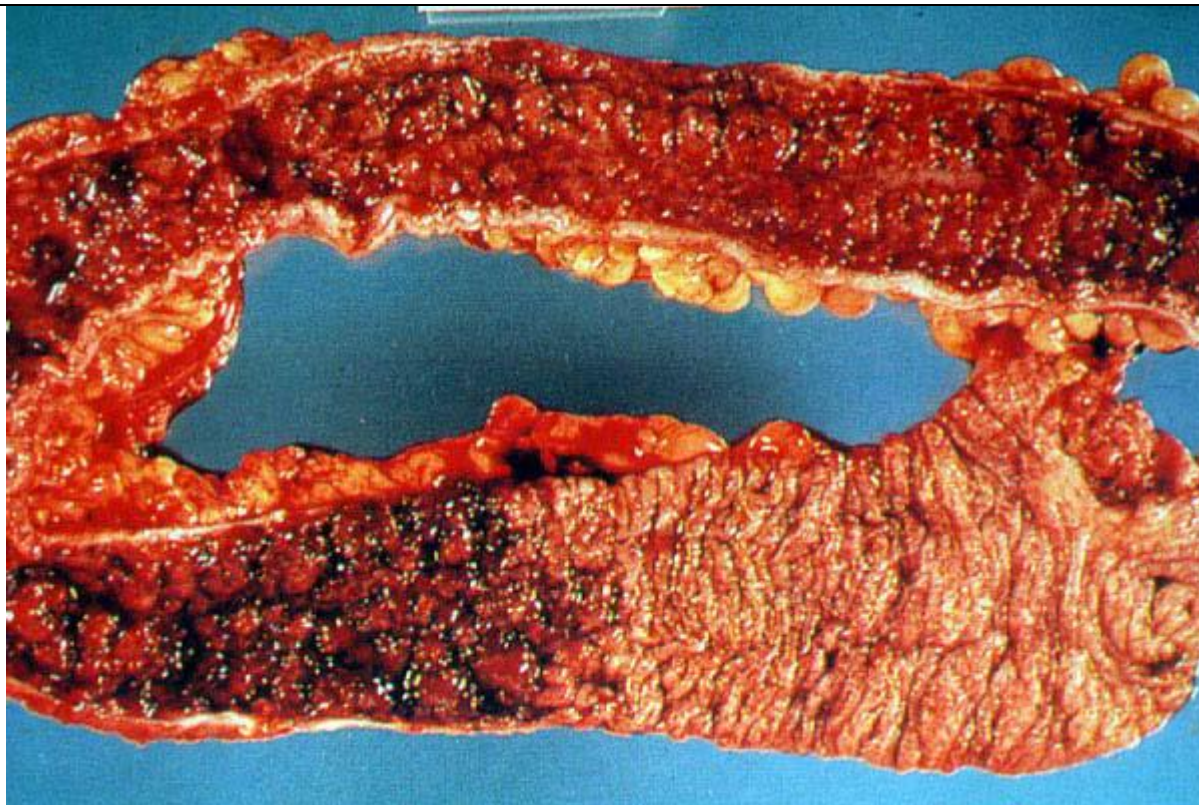


Figure: G/A of Meckel's diverticulum

1. Describe the pathological changes of inflammatory diseases affecting the large intestine including inflammatory bowel diseases.
2. Recognize the morphology of pre-cancerous conditions affecting GI system.
3. Identify, classify and describe the polyps of GIT system.
4. Discuss the etiology, and the microscopic features of cancer in colon, rectum and anal canal.



Figure; G/A Ulcerative colitis

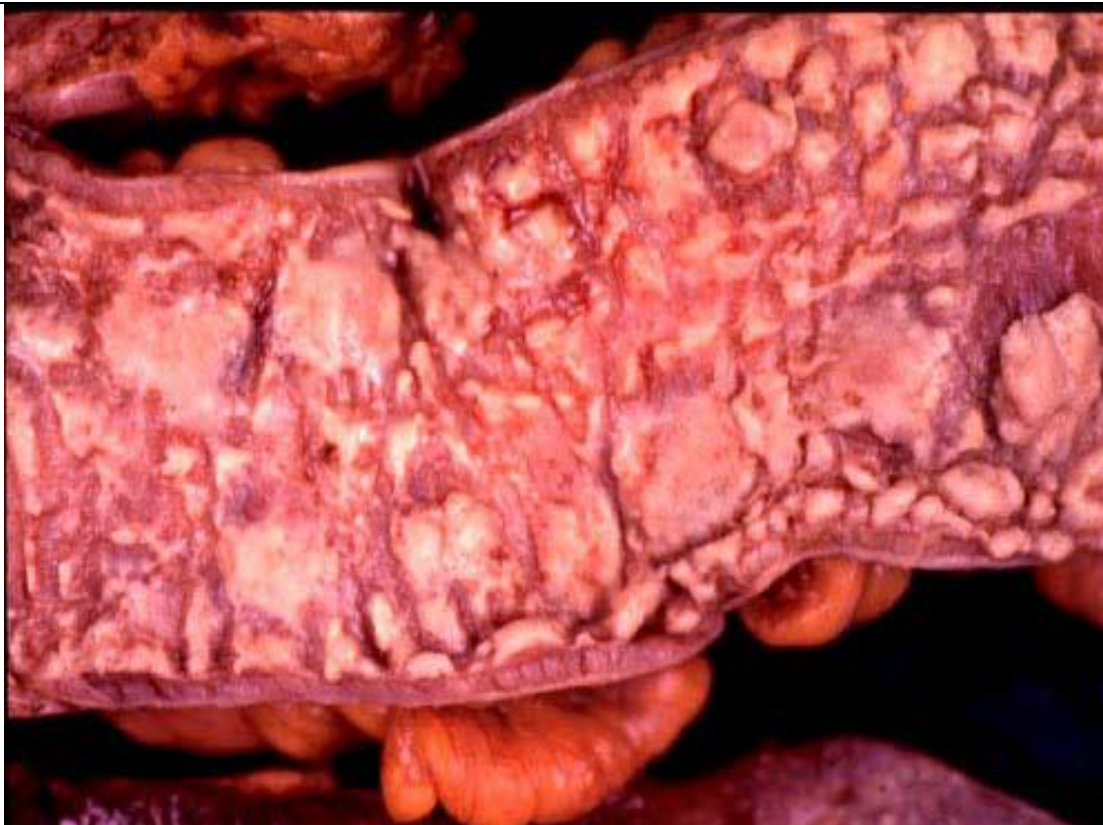

Figure: G/A Pseudo-polyps of ulcerative colitis

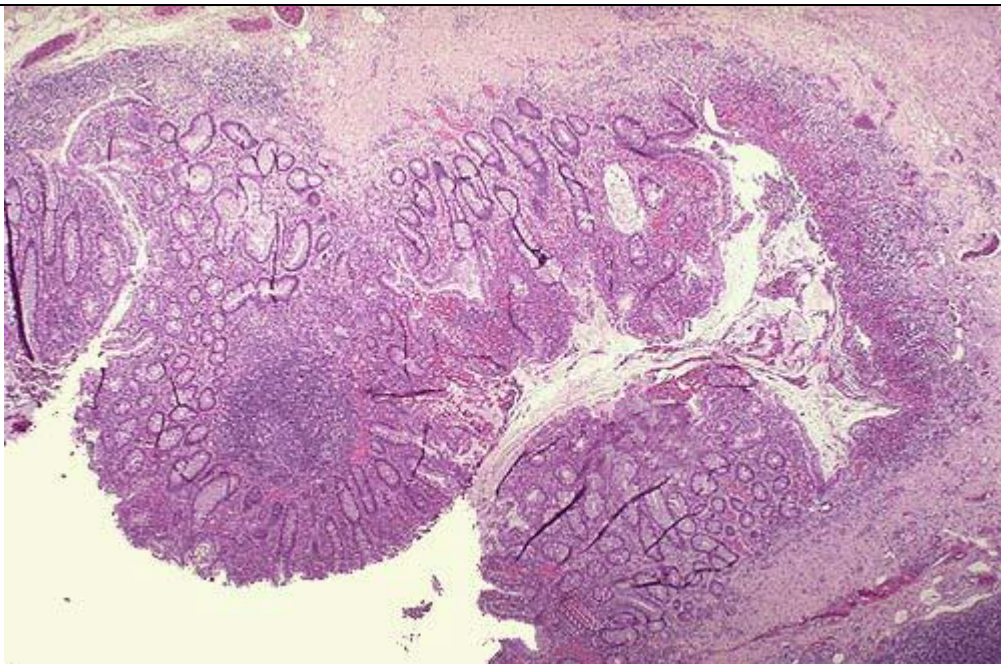
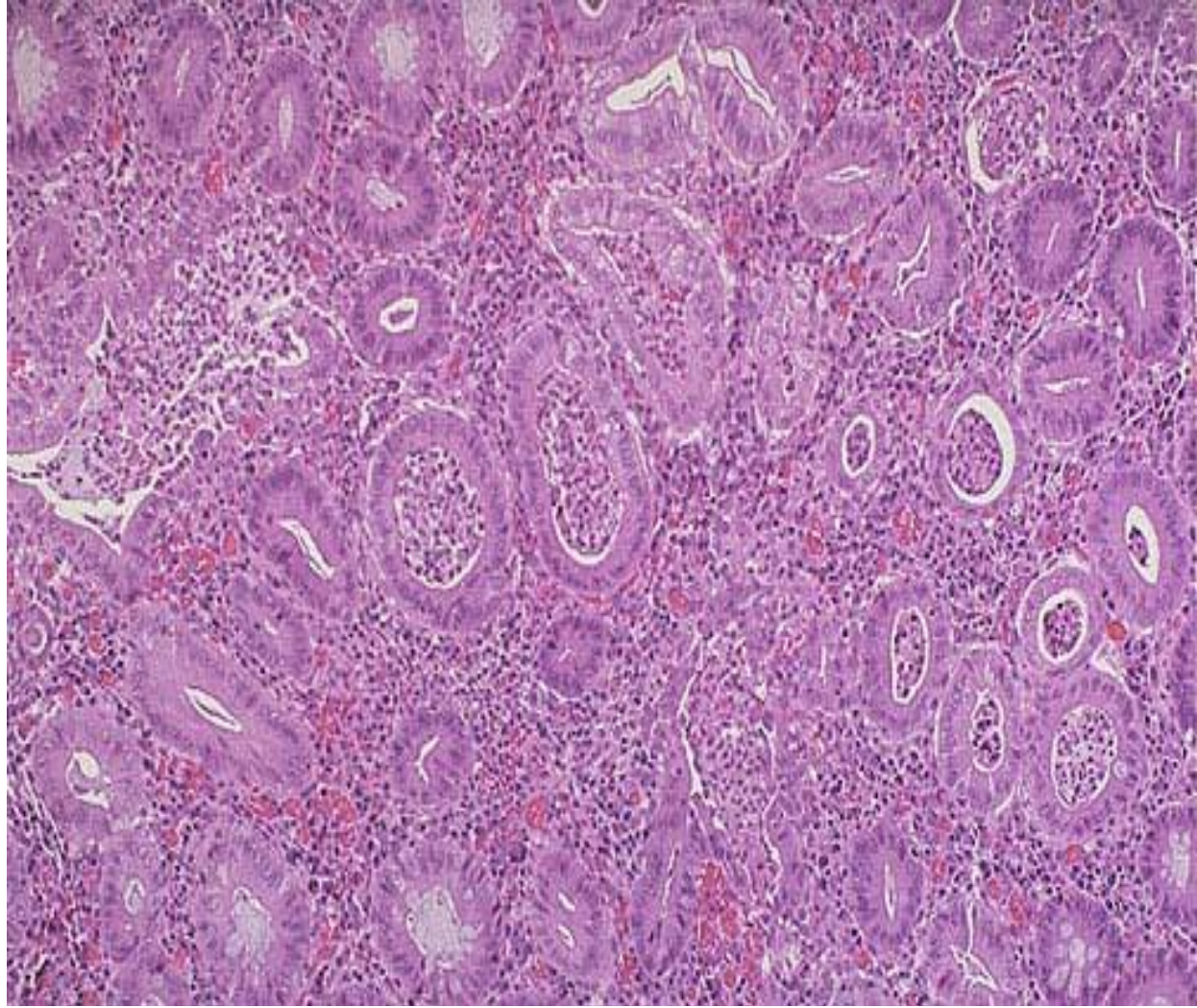
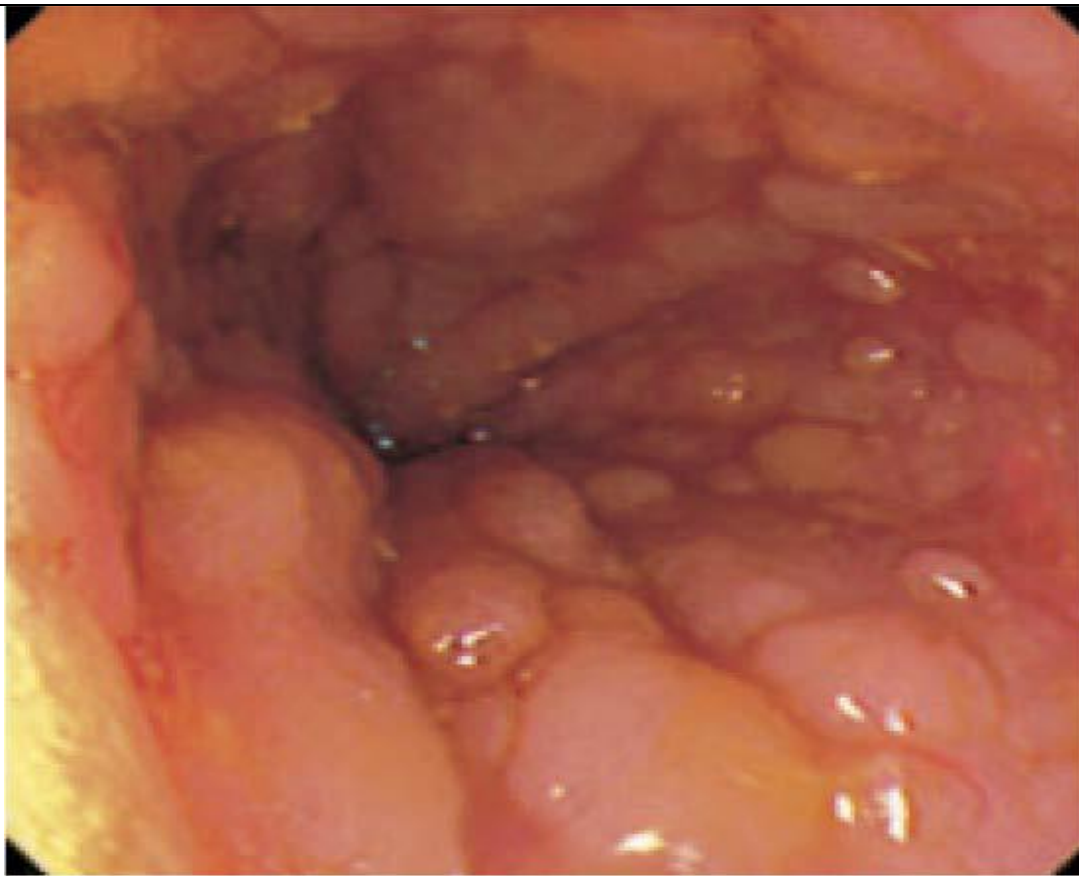

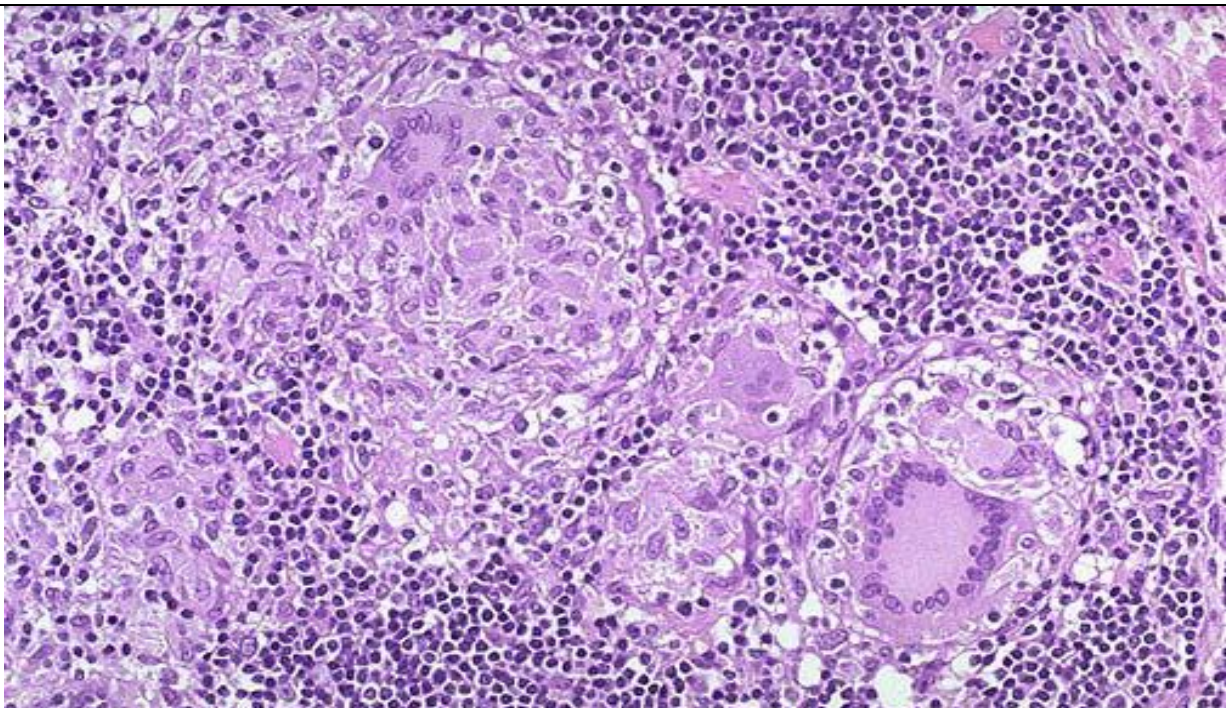
Figure: G/A Superficial ulcer in Ulcerative colitis



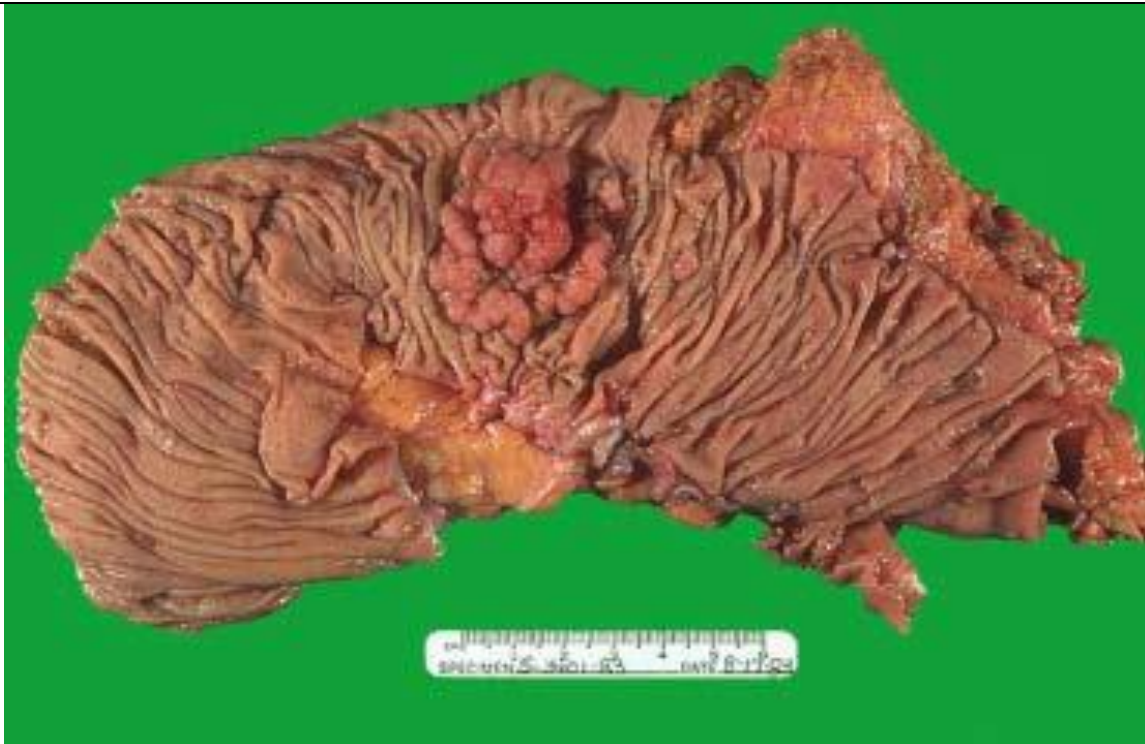Figure; G/A; Cryptitis and crypt abscess in inflammatory bowel diseases



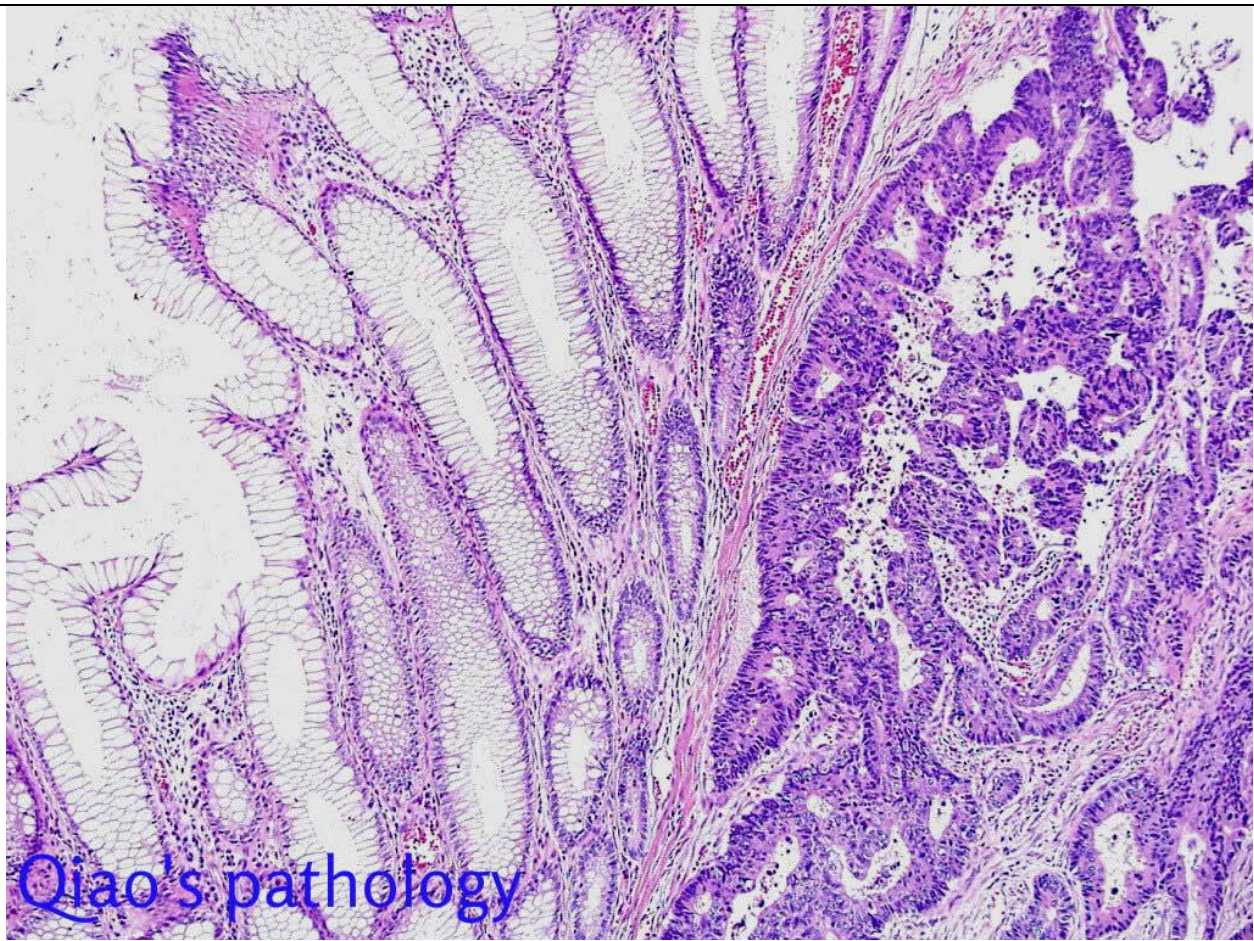
G/A: Crohn's disease; cobblestone appearance



Non caseating granuloma of crohn's diseases



Macroscopic appearance of Colonic carcinoma



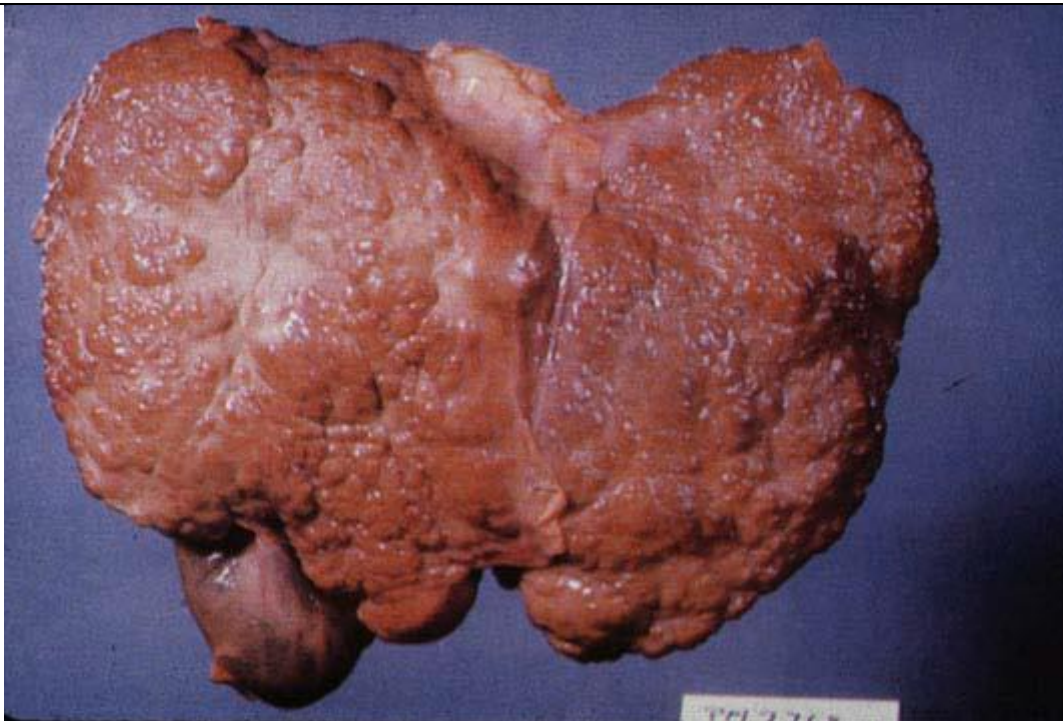
Microscopic appearance of colonic carcinoma

Liver, gall bladder and pancreas:

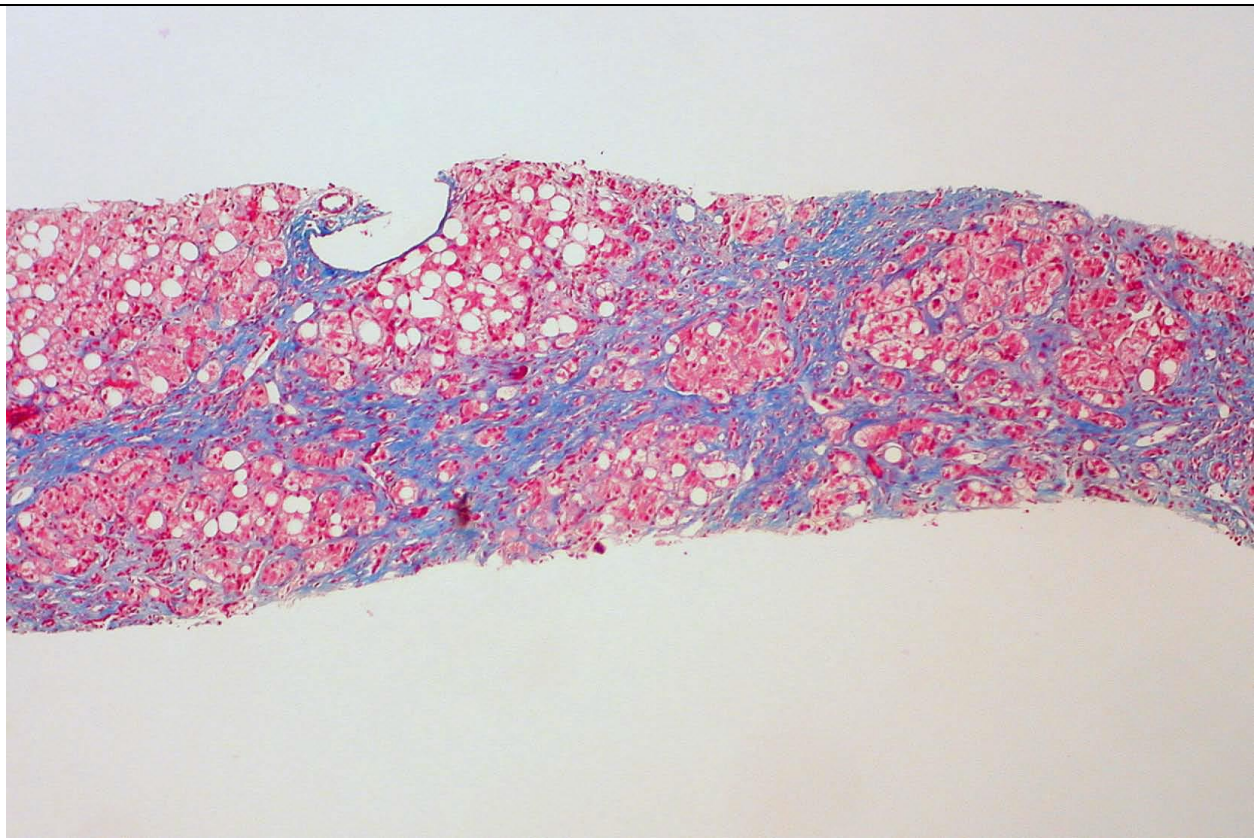
1. Discuss various types of jaundice, its classification according to physiological and biochemical bases (C2, P2).
2. List the inflammatory and neoplastic conditions of the gallbladder (C1).
3. Discuss the formation, presentation, management and complications of gallstones (C2).
4. Describe briefly the common inflammatory conditions affecting the pancreas with their etiology, pathogenesis and complications (C1).
5. List the neoplastic conditions of the pancreas and outline the presentation, diagnostic management and complications of pancreatic malignancy (C1).

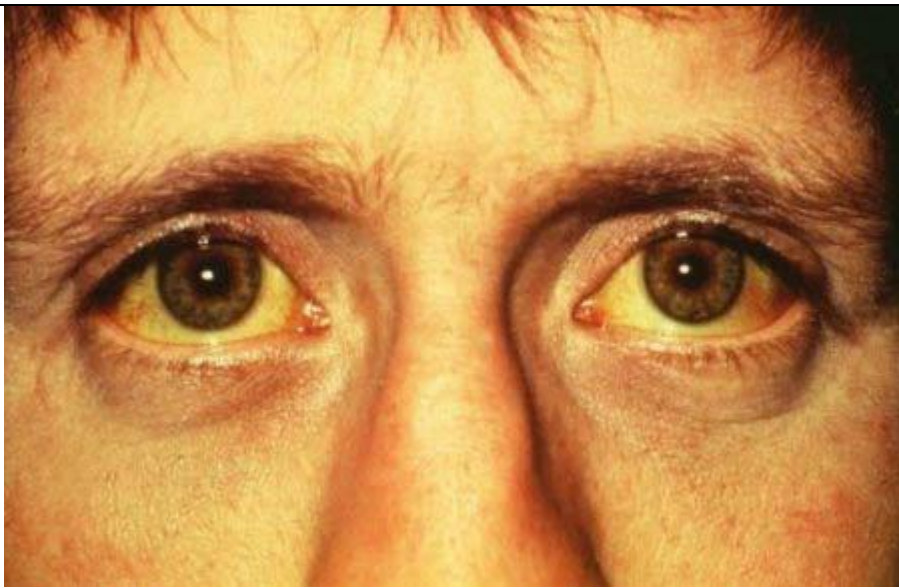

FIG: G/A Jaundice:yellow discoloration of sclera



FIG; G/A of liver cirrhosis.



Liver: microscopic appearance of cirrhosis. (trichrome stain)

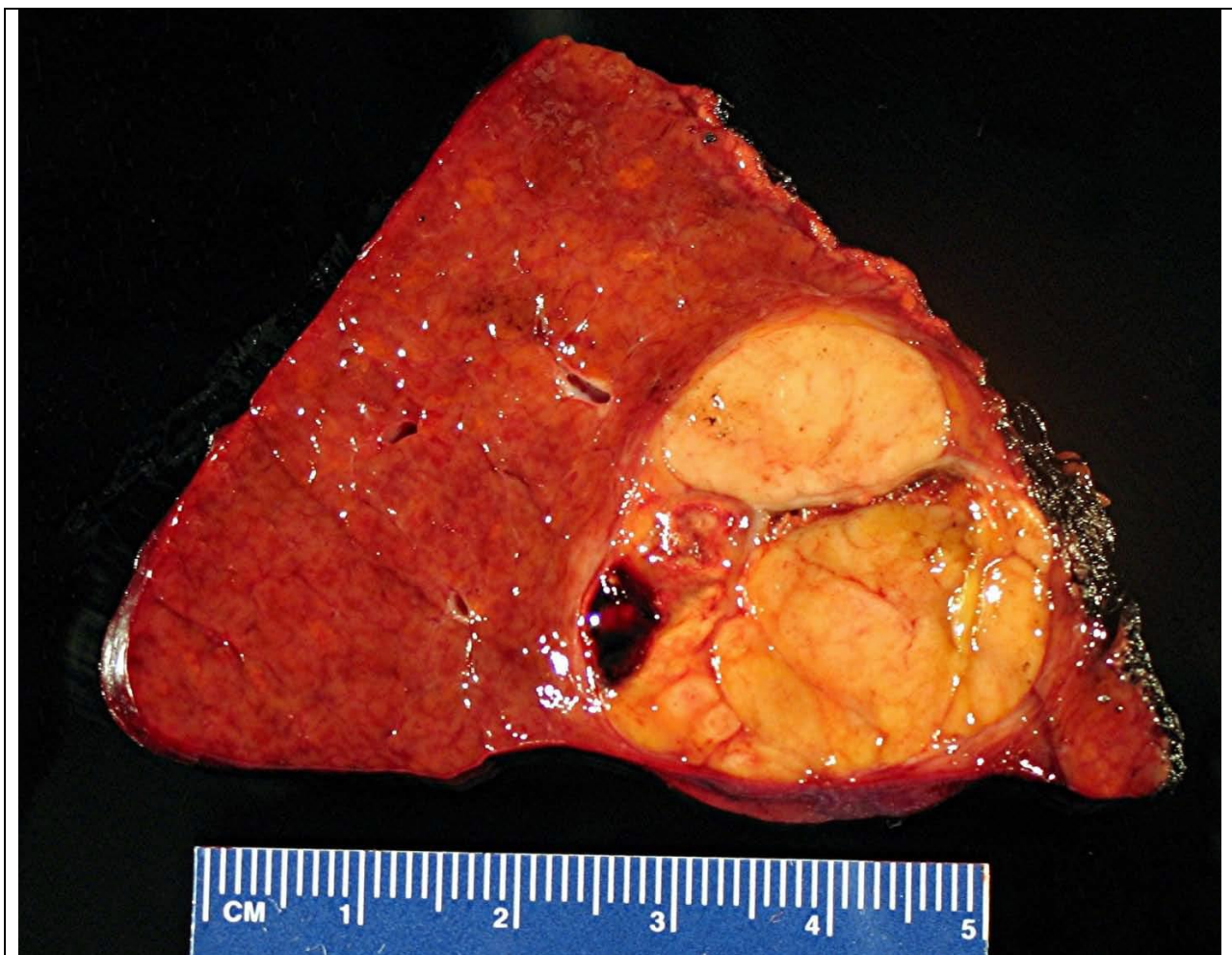
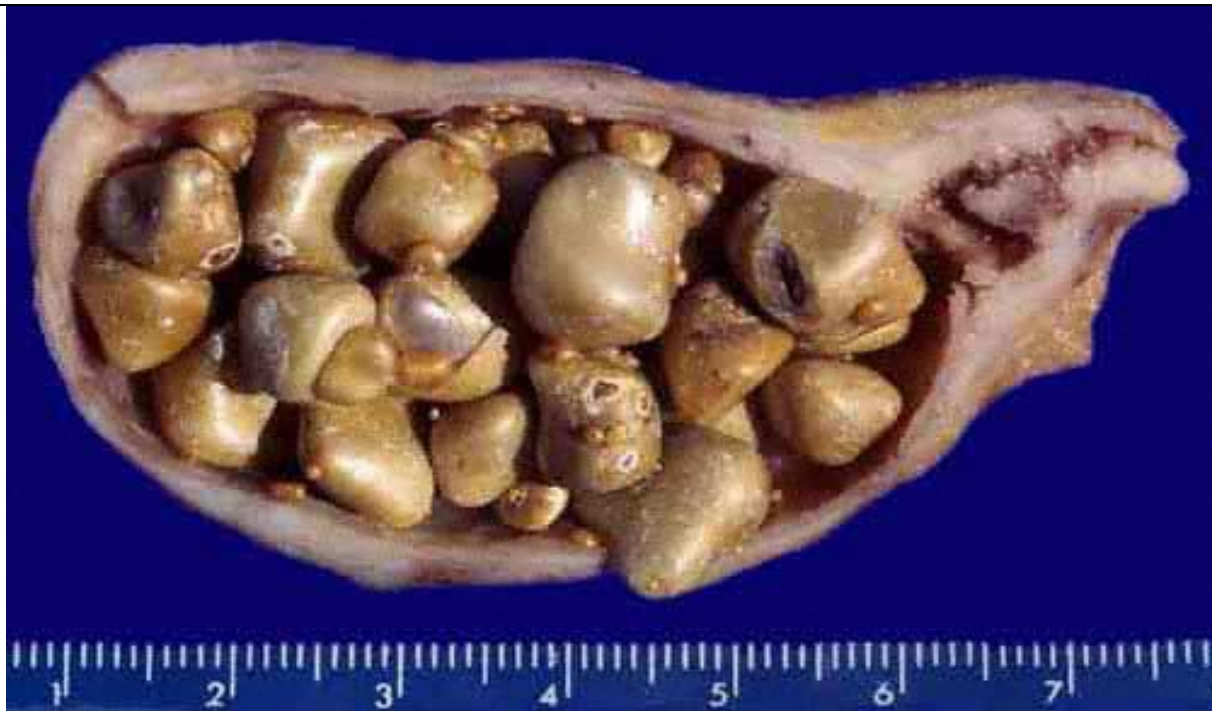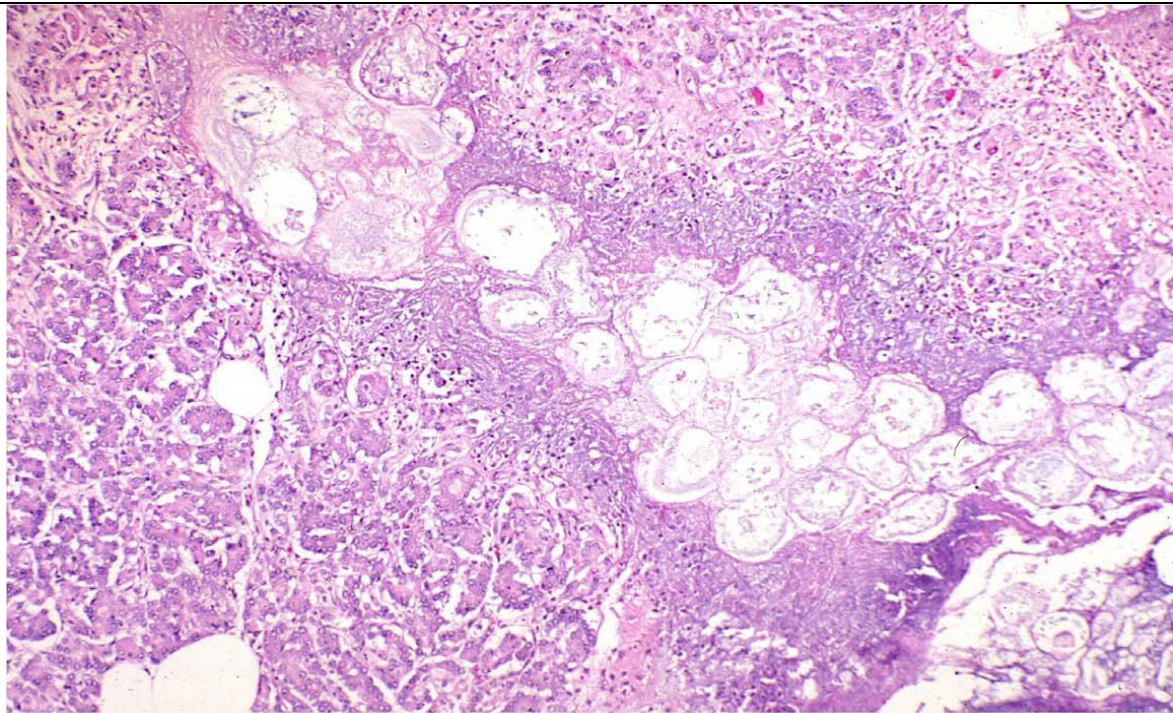


Figure: Macroscopic appearance of hepatocellular carcinoma



Gall

bladder stones



Microscopic appearance of acute pancreatitis

\

Chapter 6

Urinary Tract System

Contents:**Learning outcomes:**

- Describe the morphological features of the tumors of the urinary tract.
- Describe the morphological features of glomerulonephritis in children and adults.

Investigations in renal system diseases:

Urine analysis.

Renal biopsy.

INDICATIONS FOR URINALYSIS:

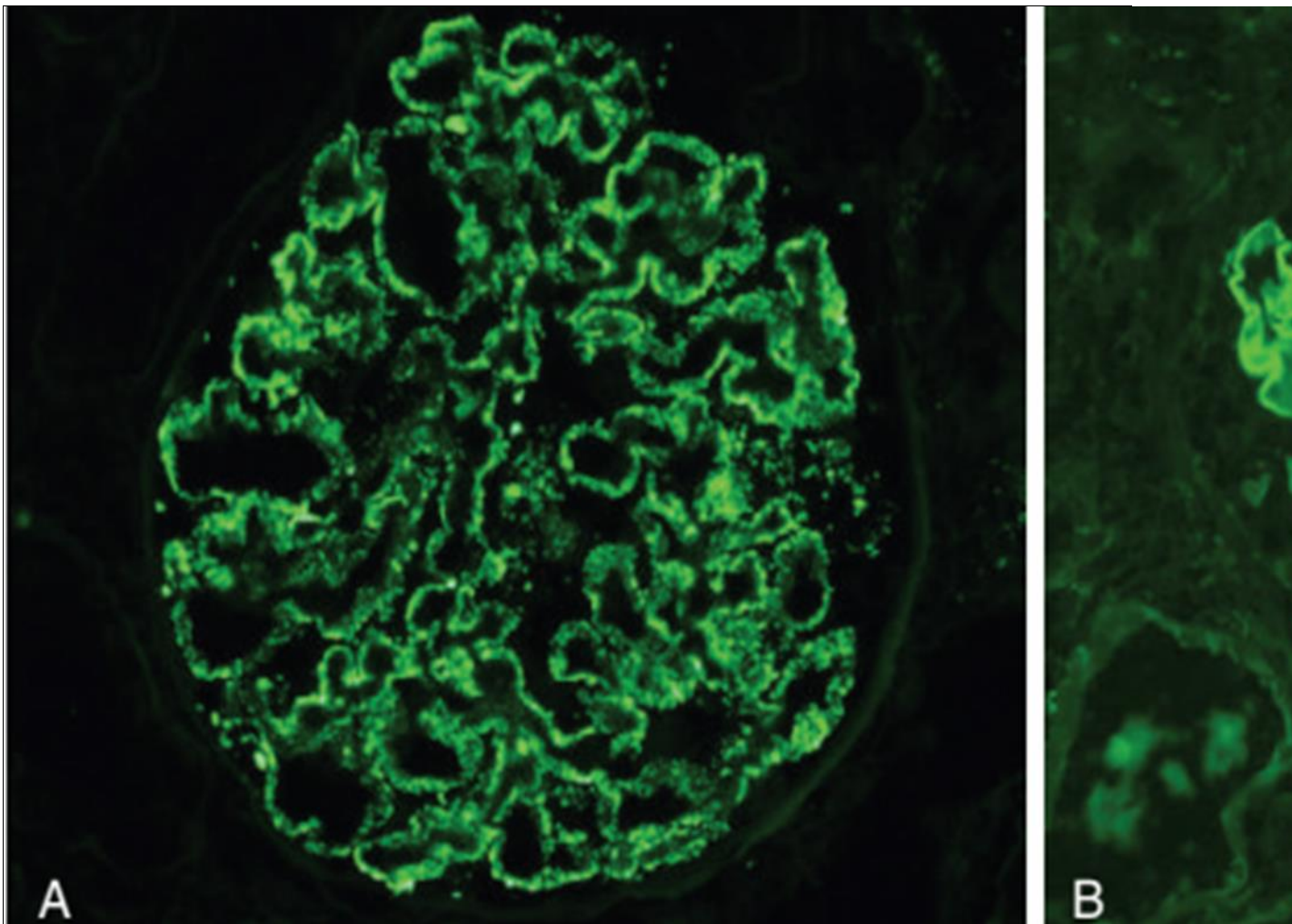
1. Suspected renal diseases like glomerulonephritis nephrotic syndrome, pyelonephritis, and renal failure
2. Detection of urinary tract infection
3. Detection and management of metabolic disorders like diabetes mellitus
4. Differential diagnosis of jaundice
5. Detection and management of plasma cell dyscrasias
6. Diagnosis of pregnancy.

Glomerulonephritis & Glomerulopathy:

- A heterogeneous group of renal diseases in which the glomeruli are primarily affected.
- Lesion is bilateral and symmetrical.

Distribution of glomerular lesions:

- Diffuse: Involving most (> 50%) of glomeruli.
 - Focal: Involving a minority (< 50%) of glomeruli.
 - Global: Most or all of a glomerulus involved.
 - Segmental: Part of a glomerulus involved.
- **Patterns of deposition of immune complexes in glomeruli:**
 - Two patterns of deposition of immune complexes is seen by immunofluorescence microscopy.



Figure; Immunofluorescence staining: Linear, characteristic of classic anti-glomerular basement membrane (anti-GBM) antibody glomerulonephritis

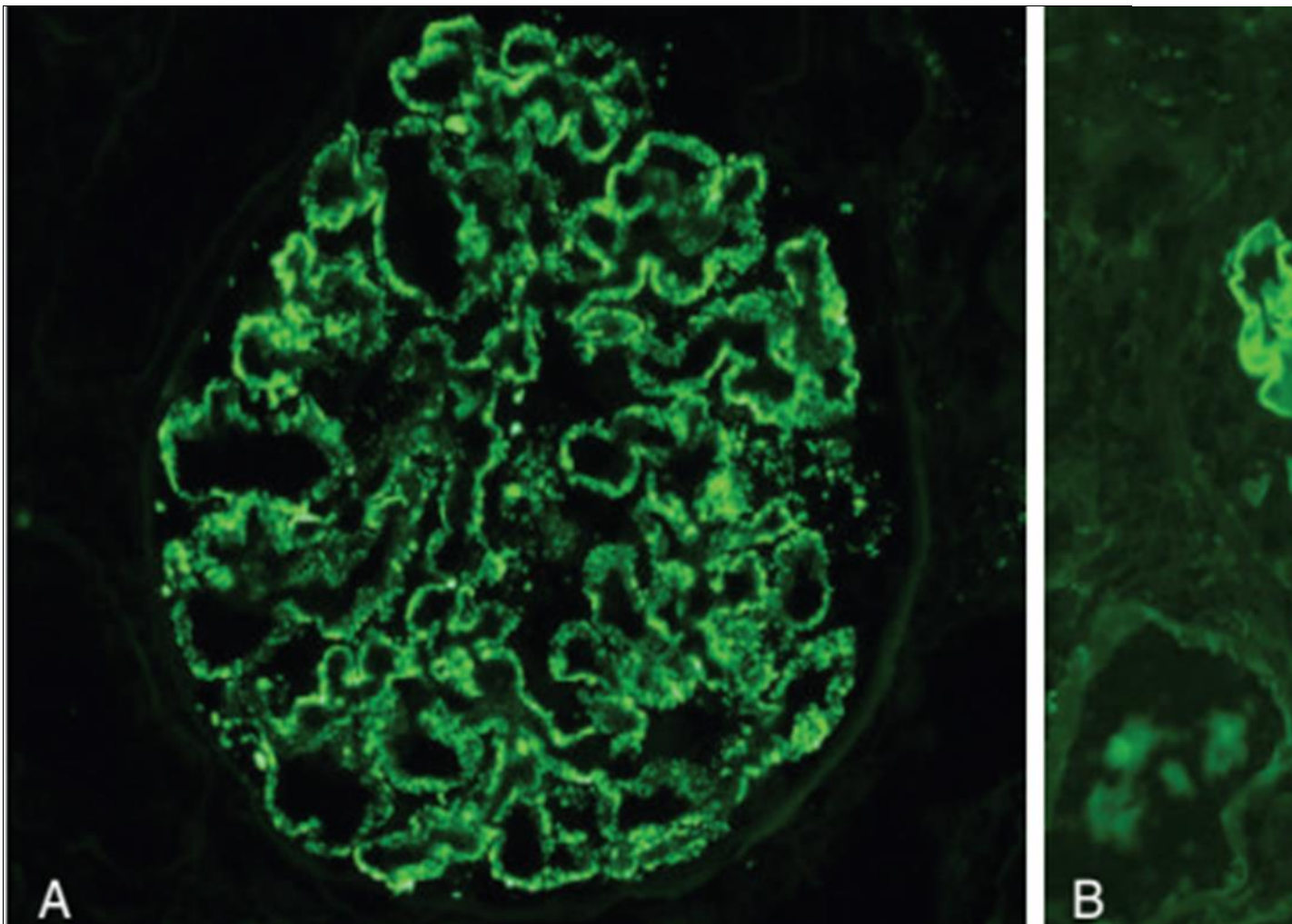
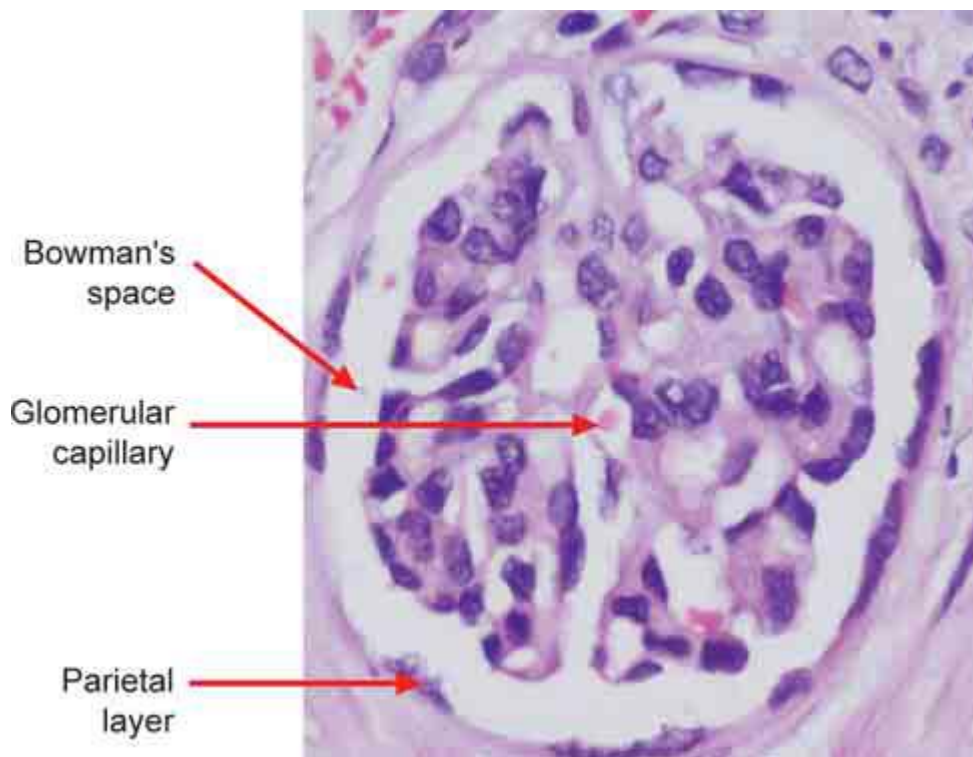


Figure: Immunofluorescence staining: Granular deposits, characteristic of circulating and in situ immune complex deposition.

Minimal changes glomerulonephritis:

Primary glomerular diseases:	Secondary glomerular diseases
1. Minimal-change disease	1. SLE.
2. Focal and segmental glomerulo-sclerosis	2. DM.
3. Membranous nephropathy	3. Amyloidosis.
4. Acute post infectious GN	4. Poly arteritis nodosa.
5. Membrano-proliferative GN	5. Microscopic polyangiitis.
6. IgA nephropathy	6. Wegener granulomatosis.
7. Chronic GN	7. Henoch– Schonlein purpura.
	8. Bacterial endocarditis



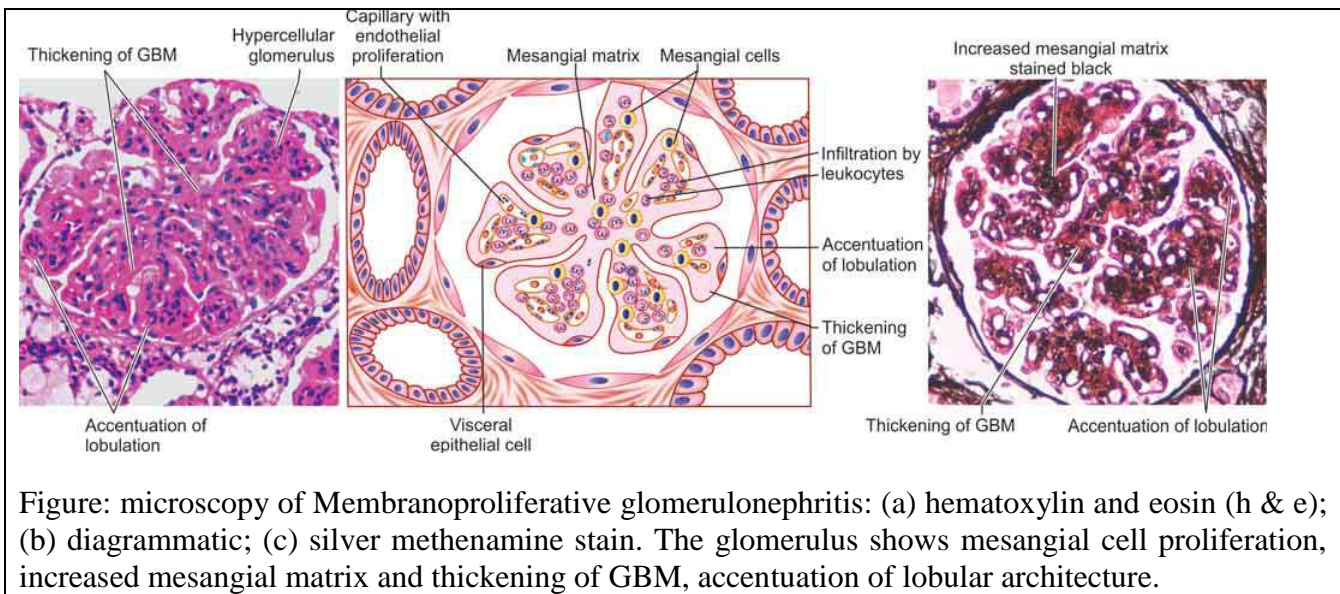
Light microscopic appearance of glomerulus (diagrammatic)

Glomerular diseases

Glomerular diseases may be broadly divided into primary and secondary:

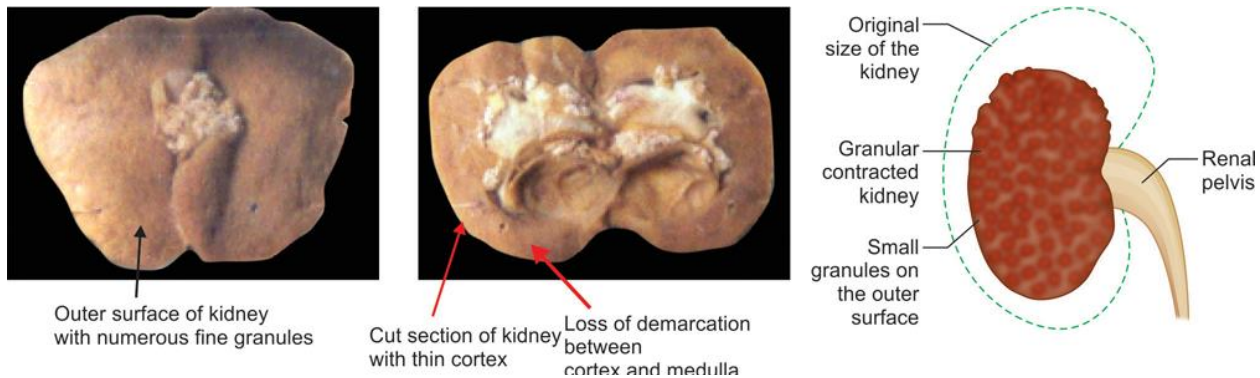
- _ Primary glomerulonephritis or glomerulopathy (those without inflammatory cells): kidney is the only or predominant organ involved.
- _ Secondary glomerular diseases: in these disorders, glomeruli are involved secondary to a systemic disease.

Acute glomerulonephritis;



Chronic glomerulonephritis

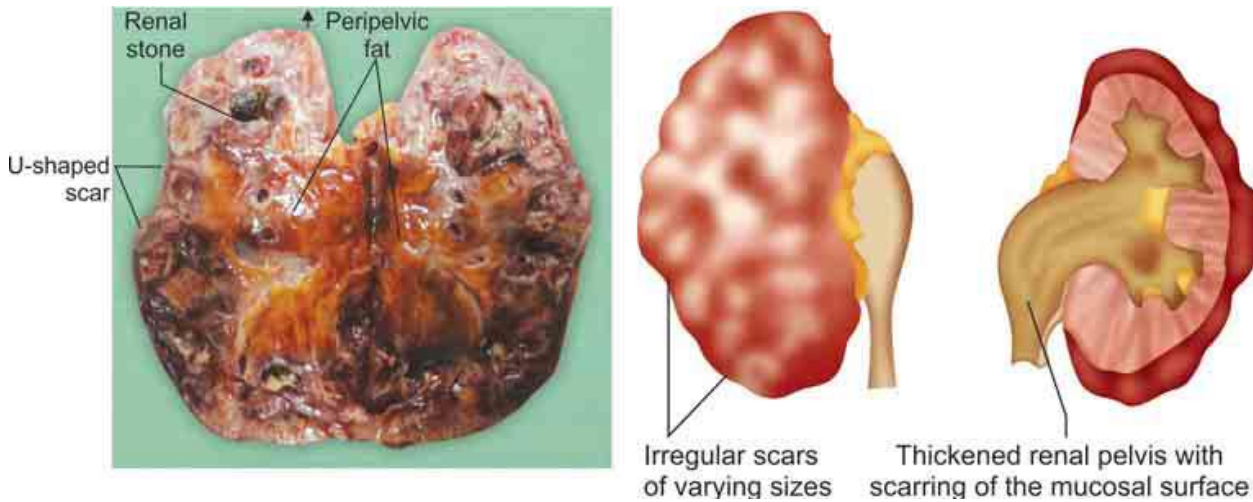
Chronic GN or chronic kidney disease (CKD) is the final stage of a variety of glomerular diseases. **G/A** the kidneys are usually small and contracted weighing as low as 50 gm each. Outer aspect shows contracted kidney with diffusely granular surface.



Chronic pyelonephritis

Chronic pyelonephritis is a chronic tubulointerstitial disease resulting from repeated attacks of inflammation and scarring due to

infection



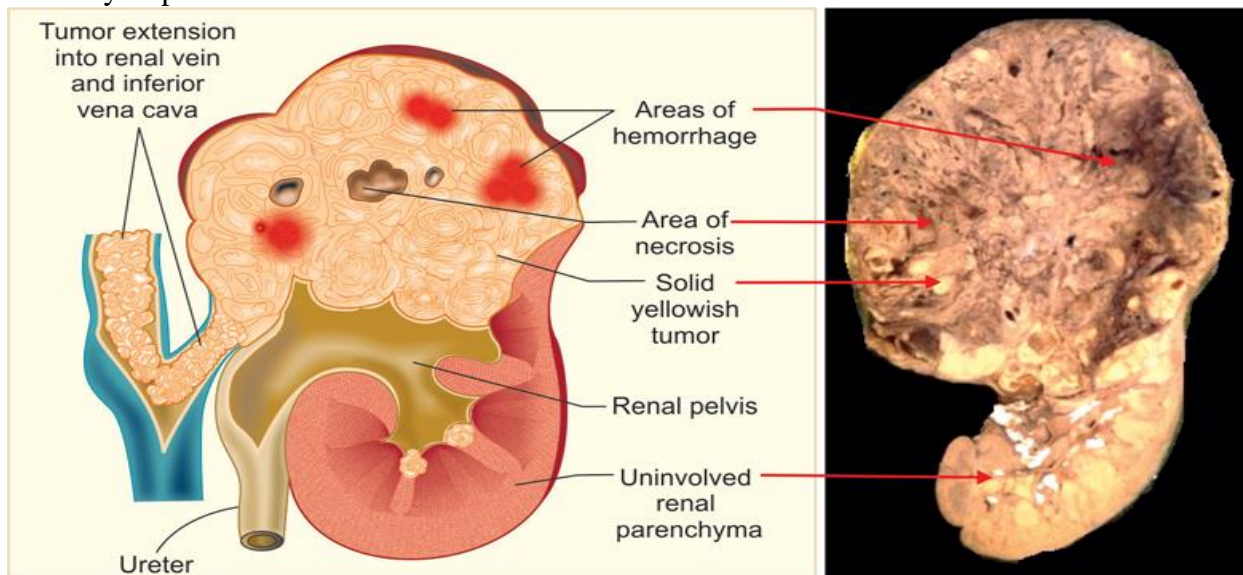
Gross appearance of chronic pyelonephritis. (a) Cut section of kidney showing scars and a renal stone in the calyces; (b) (Diagrammatic) outer aspect; (c) cut section (diagrammatic)

Renal cell carcinoma

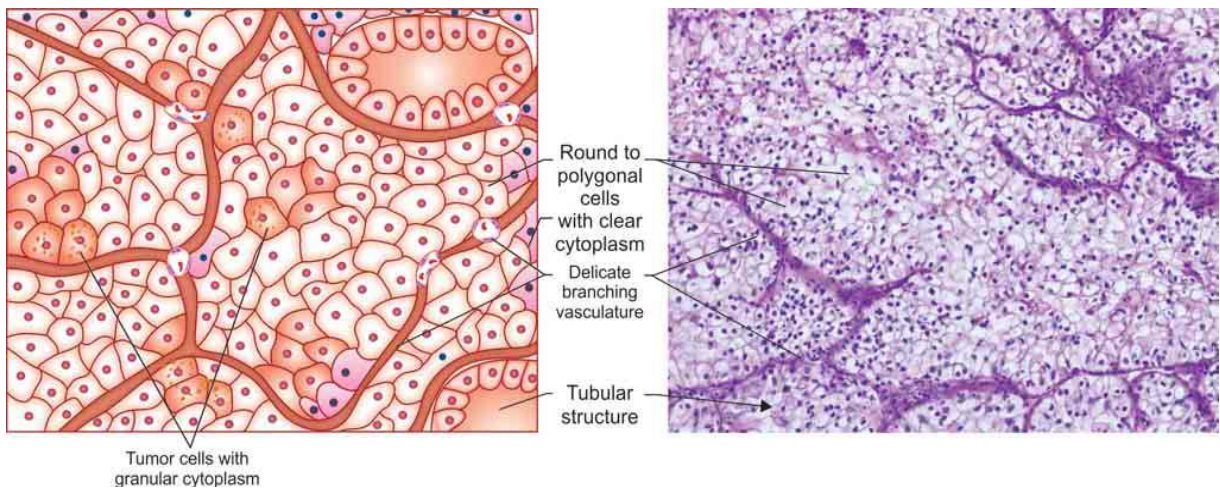
Renal cell carcinoma (RCC) or hypernephroma or adenocarcinoma comprises 70-80% of all renal cancers and occurs most commonly in 50 to 70 years of age.

G/A the tumor commonly arises from a pole, most often upper pole, of the kidney as a solitary and unilateral tumor. The tumor is generally large, golden yellow and circumscribed. Cut section of the tumor commonly shows large areas of ischemic necrosis, cystic change and foci of hemorrhages. Another feature is the frequent presence of tumor thrombus in the renal vein.

A variety of patterns of tumor cells are seen such as:



Cut surface of renal cell carcinoma showing a yellowish, spherical, circumscribed, variegated tumor at the upper pole of kidney. (a) (Diagrammatic); (b) gross specimen



Renal cell carcinoma. (a) Diagrammatic; (b) photomicrograph of clear cell type showing

Chapter 8

Endocrine system

Contents:

Learning outcome:

1. Identify major signs of hyper/ hypopituitarism.
2. Identify major signs of hypo and hyperthyroidism.
3. Describe the microscopic feature of Hashimoto's thyroiditis.
4. Describe the microscopic features of major malignant thyroid tumors.
5. Identify major signs of Cushing syndrome and Addisonian crisis.
6. Identify major signs of diabetes mellitus and its complications.

Pituitary tumor:

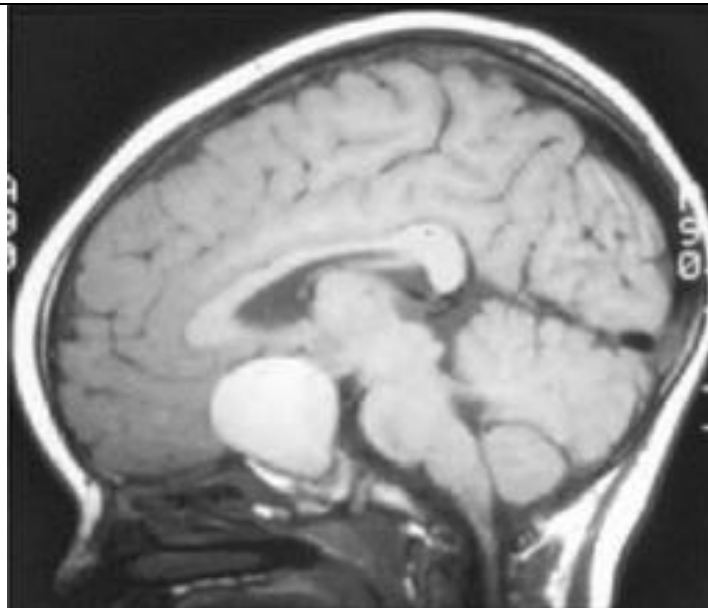


Figure: pituitary tumor, macroadenoma.

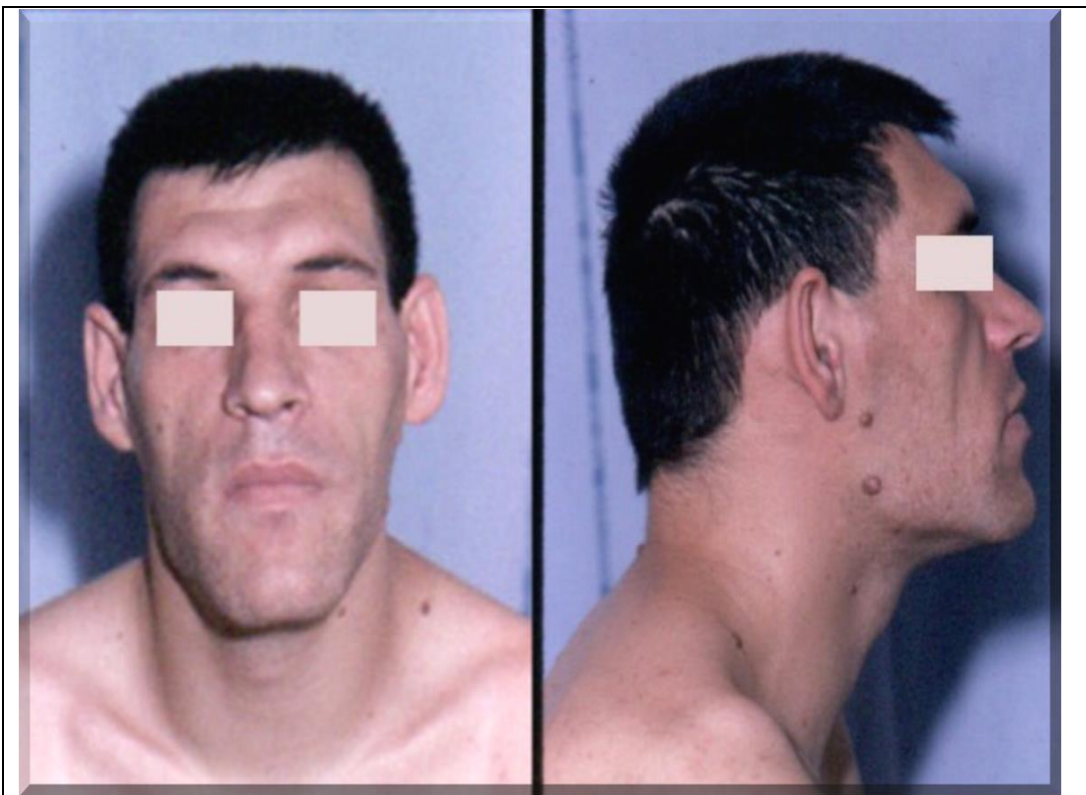

Figure: acromegaly note the large

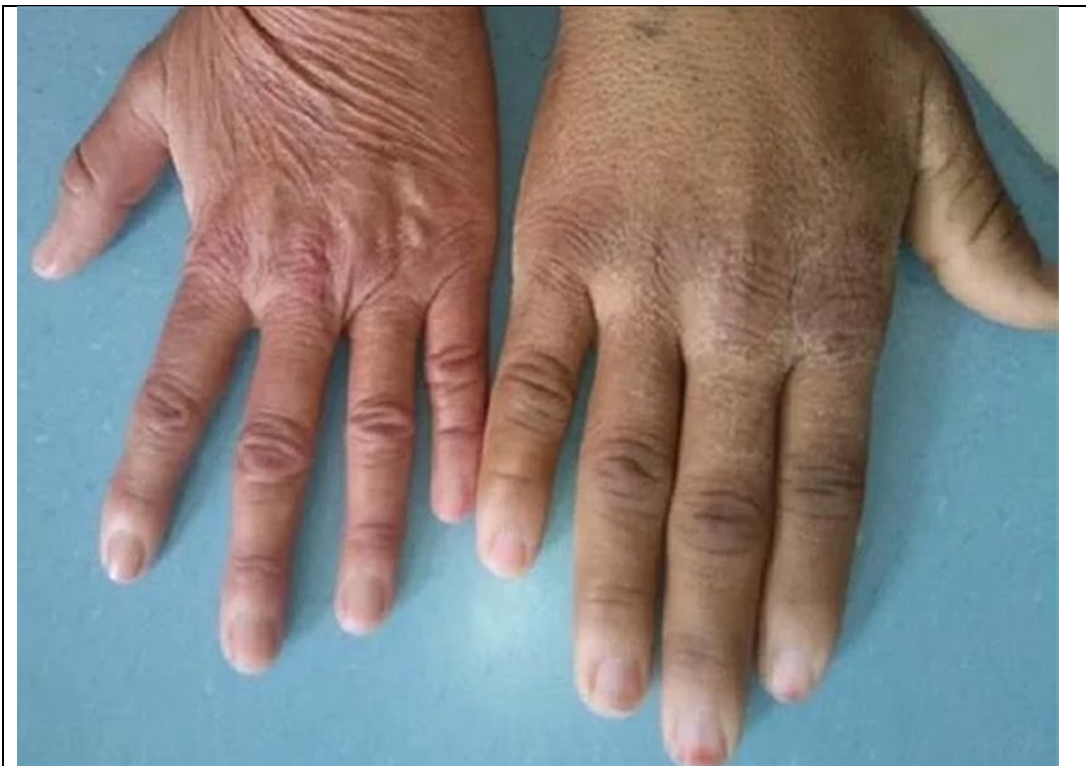

Figure acromegaly

Thyroid diseases:

Hyperthyroidism: causes:

- I. Excessive TSH-Receptor Stimulation: Graves disease (TRAb)
- II. Autonomous Thyroid Hormone Secretion: toxic nodule in Multinodular goiter.
- III. Destruction of Follicles With Release of Hormone: Subacute de Quervain thyroiditis (virus infection) Painless thyroiditis/postpartum thyroiditis, acute thyroiditis (bacterial infection) and Drug-induced thyroiditis.
- IV. Extra-thyroidal sources of thyroid hormone: Iatrogenic over replacement with thyroid hormone.

Hypothyroidism causes:

A. Primary Hypothyroidism

1. Hashimoto thyroiditis
2. Iodine deficiency (endemic goiter)
3. Thyroid infiltration (amyloidosis, hemochromatosis, sarcoidosis, malignancy)

B. Secondary and tertiary causes:

1. Pituitary origin (secondary)
2. Hypothalamic disorders (tertiary)

C. Congenital:

1. TSH deficiency or structural abnormality
2. TSH receptor defect
3. **Graves disease: it is a multisystem autoimmune disorder characterized by thyroid stimulating hormone receptors auto antibodies (TSHRAb). Hallmarks of the disease were palpitations (hyperthyroidism), goiter, and exophthalmos,**

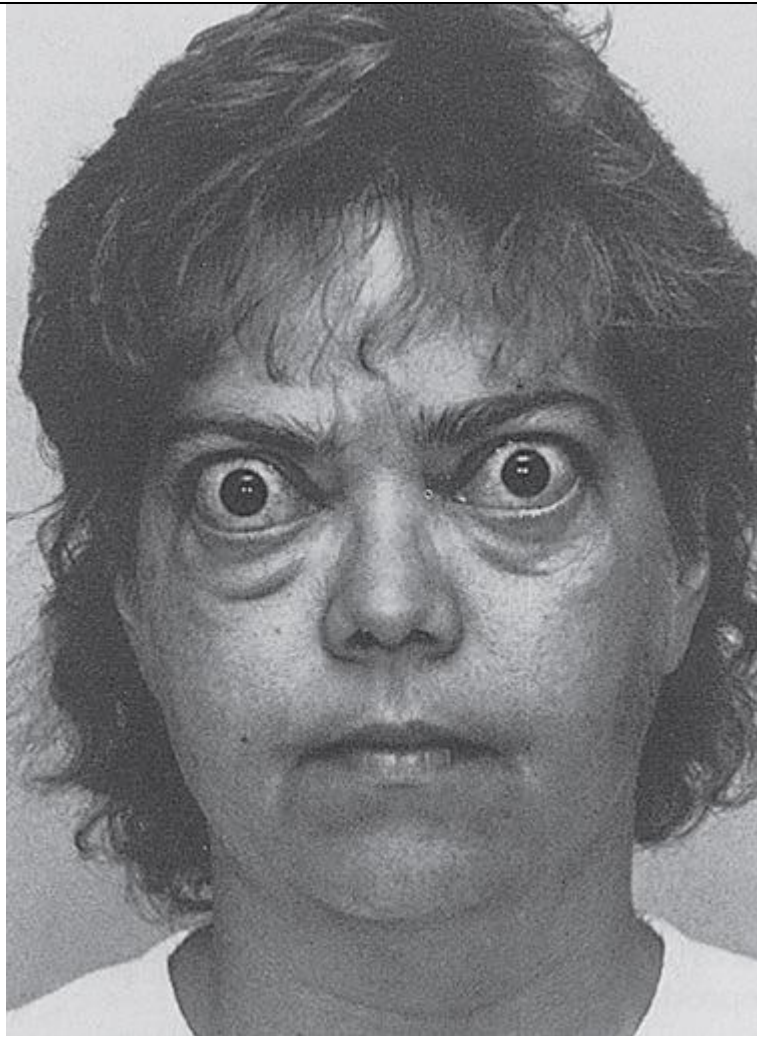

Figure: Patient with Graves's orbitopathy. Note the typical bilateral eye disease with periorbital swelling, stare, and exophthalmos.

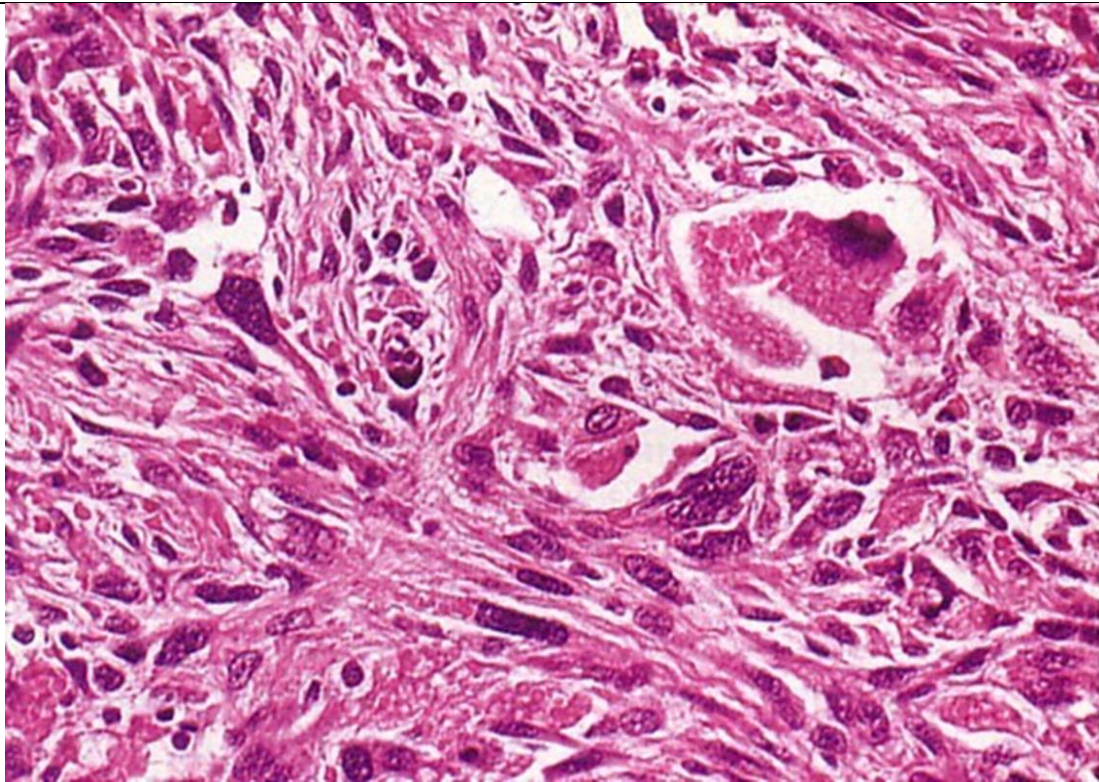
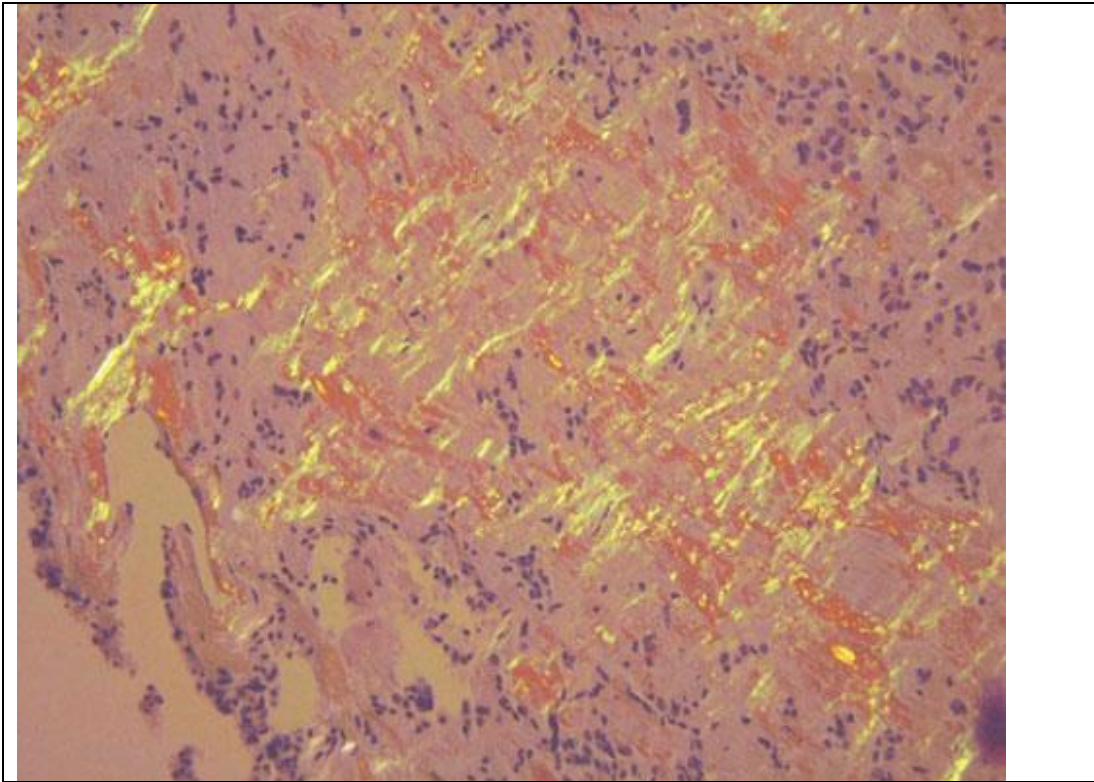


Figure: M/S Anaplastic carcinoma of thyroid gland. Highly anaplastic cell on histology with Giant, spindle, small or mix cell population Foci of papillary or follicular differentiation



Figure; medullary thyroid carcinoma. Amyloid deposits stain orange-red with Congo Red stain

Chapter 9

Reproductive system

Contents:

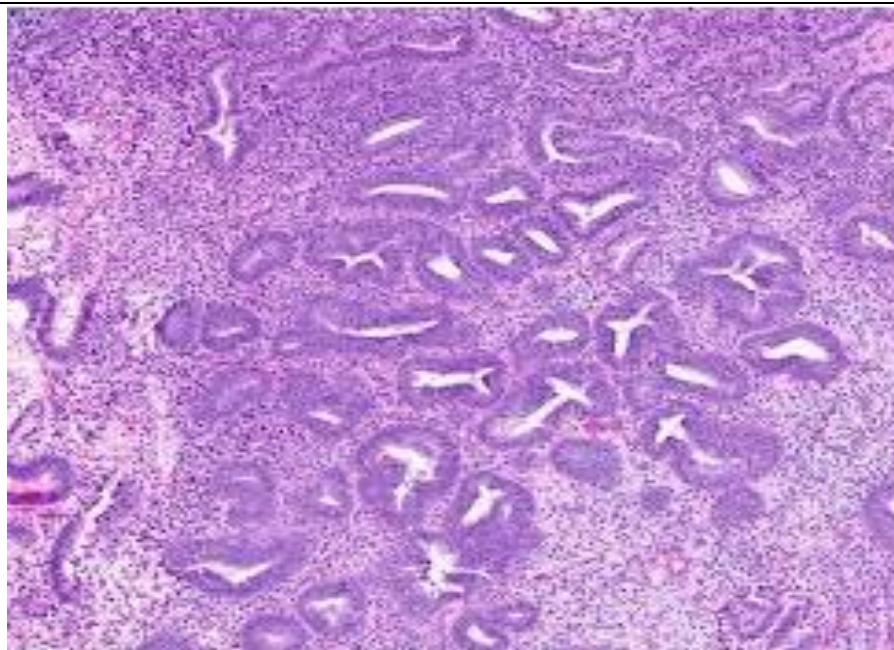
Learning outcome:

- Morphology of disorders associated with abnormal hormones (C1).
- Morphology of disorders associated with abnormal genetic constitution
- Review of common neoplastic and non-neoplastic pathologies of male reproductive system.
- Review of common neoplastic lesions of female reproductive organs.
- Gross morphology and microscopic features of benign and malignant tumors of breast.

Female genital tract:

Endometrial hyperplasia:

Endometrial hyperplasia is a condition characterized by proliferative patterns of glandular and stromal tissues



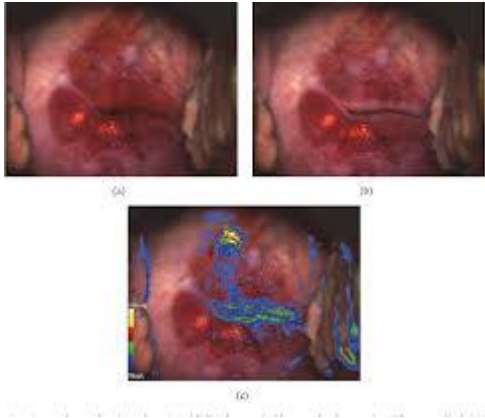
M/e: i. presence of varying-sized glands, many of which are large and cystically dilated and are lined by atrophic epithelium.

i. The stroma is sparsely cellular and edematous

Invasive cervical cancer:

Invasive cervical cancer in about 80% of cases is epidermoid (squamous cell) carcinoma, with peak incidence in 4th to 6th decade.

G/a: invasive cervical carcinoma may present 3 types of patterns—fungating, ulcerating and infiltrating. The fungating or exophytic pattern appears as cauliflower-like growth infiltrating the adjacent vaginal wall.



- M/e:**
- i. most commonly, the tumor is moderately-differentiated, non-keratinizing, large cell type.
 - ii. The tumor cells are seen as masses of anaplastic cells of varying size and have abundant cytoplasm.
 - iii. Keratin formation may be seen in some cells.
 - iv. Intervening stroma shows prominent inflammatory cell infiltrate

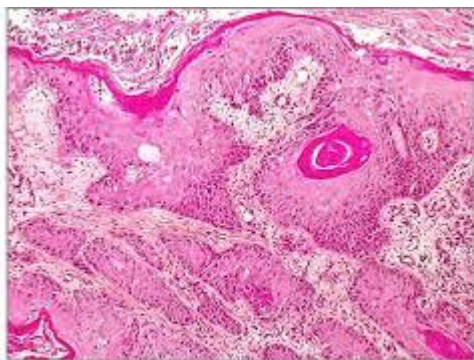


FIGURE 3.7: Histology – Keratinizing well differentiated invasive squamous cell carcinoma (×10).

Classification is according to the tissue of origin:

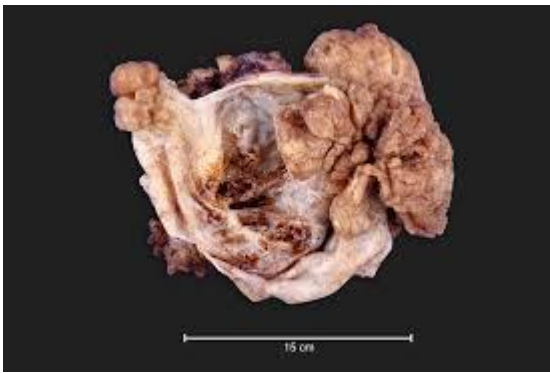— Primary tumors may arise from one of three ovarian components:

1. Surface epithelium which is derived from the coelomic epithelium.
 2. Germ cells which migrate to the ovary from the yolk sac.
 3. Sex cord/stroma of the ovary.
- Secondary or metastatic tumors.

Serous ovarian tumors

Serous tumors comprise the largest group constituting about 20% of all ovarian tumors. These tumors arise from the ovarian surface (coelomic) epithelium which differentiates along tubal-type of epithelium.

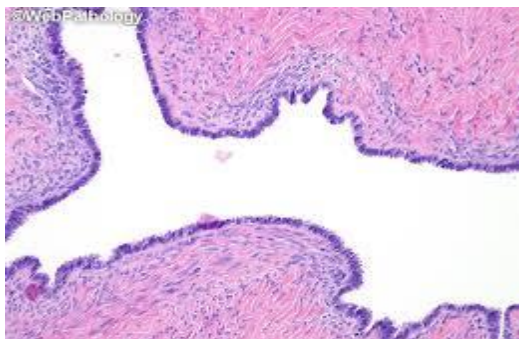
G/a: serous tumors of benign, borderline and malignant type are large and spherical masses. Cut section of benign tumors is unilocular while larger cysts are multilocular with daughter loculi in their walls containing clear watery fluid. Malignant serous tumours have solid areas in the cystic mass and may contain exophytic as well as intracystic papillary projections.



M/e: features of benign and malignant serous tumors are as follows:

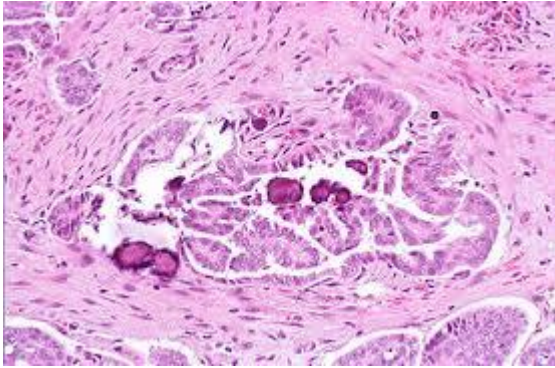
Serous cystadenoma ovary

- i. The cyst is lined by properly-oriented low columnar epithelium.
- ii. The lining cells may be ciliated and resemble tubal epithelium



Papillary serous cystadenocarcinoma ovary

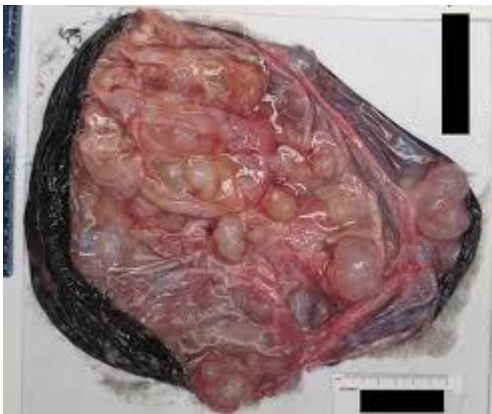- i. Lining of the cyst is by multilayered malignant cells having features such as loss of polarity, presence of solid sheets of anaplastic epithelial cells.
- ii. There is definite evidence of stromal invasion by malignant cells.
- iii. Papillae formations are more frequent in malignant variety and may be associated with psammoma bodies



Mucinous ovarian tumors

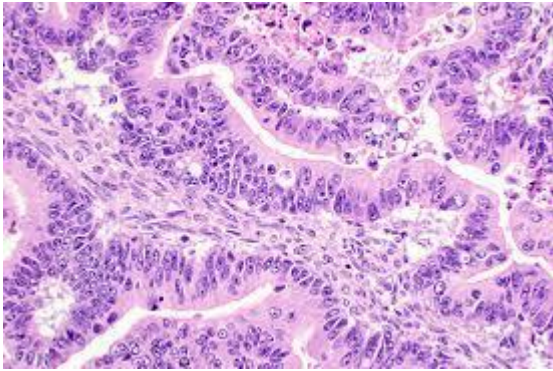
Mucinous tumors are more commonly unilateral than serous tumors. These tumors arise from coelomic epithelium.

G/a: mucinous tumors are larger than serous type. They are smooth-surfaced cysts with characteristic multiloculations containing thick and viscid gelatinous fluid. Benign tumors have thin wall and septa which are translucent while malignant variety has thickened areas.



M/e: i. the cyst is lined by a single layer of cells having basal nuclei and apical mucinous vacuoles, resembling intestinal mucosa.

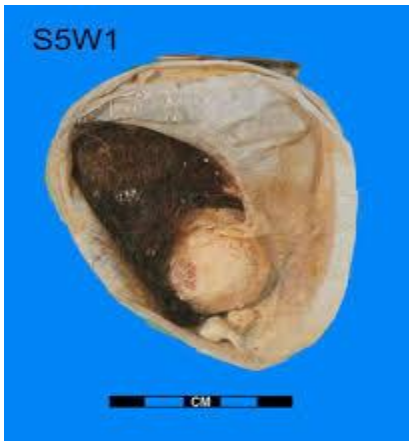ii. There is no invasion or papillae formation



Benign cystic teratoma

Ovary benign cystic teratoma or dermoid cyst of the ovary is more frequent in young women in their active reproductive life. teratoma is a tumour composed of tissue derived from three germ cell layers—ectoderm, mesoderm and endoderm.

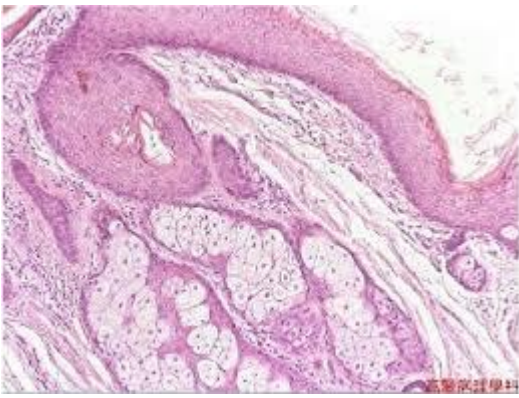
G/a: benign cystic teratoma is characteristically a unilocular cyst, 10-15 cm in diameter. On sectioning, the cyst is filled with paste-like sebaceous secretions and desquamated keratin admixed with masses of hair. The cyst wall is thin and opaque grey-white. Quite often, the cyst wall shows a solid prominence where tissue elements such as tooth, bone, cartilage and other odd tissues are present



M/e: i. viewing a benign cystic teratoma in different microscopic fields reveals a variety of mature differentiated tissues.

ii. Ectodermal derivatives are most prominent. The lining of the cyst wall is by stratified squamous epithelium. The field shows epidermis-lined cyst, islands of cartilage and some adipose tissue with its adnexal structures such as sebaceous glands, sweat glands and hair follicles.

iii. Tissues of mesodermal and endodermal origin are commonly present and include bronchus, intestinal epithelium, cartilage, bone, smooth muscle, neural tissue, salivary gland, retina, pancreas and thyroid tissue

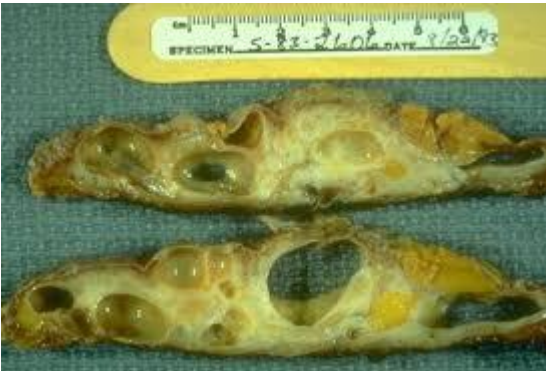

The breast:

Fibrocystic change:

Fibrocystic change is a histologic entity characterized by 3 changes: cystic dilatation of terminal ducts, relative increase in intra- and interlobular fibrous tissue, and variable degree of epithelial proliferation in the terminal ducts.

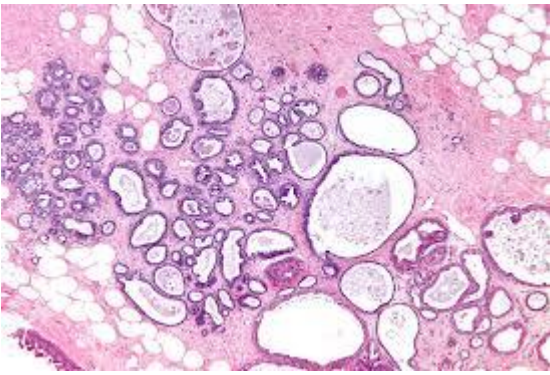
G/a: the cysts are usually multifocal and bilateral, varying in size from microcysts to 5-6 cm in diameter. On sectioning, the cysts contain thin serous to hemorrhagic fluid.



M/e: i. the cysts are often lined by flattened or atrophic epithelium.

ii. In proliferative fibrocystic change, there is epithelial hyperplasia forming tiny intracystic papillary projections.

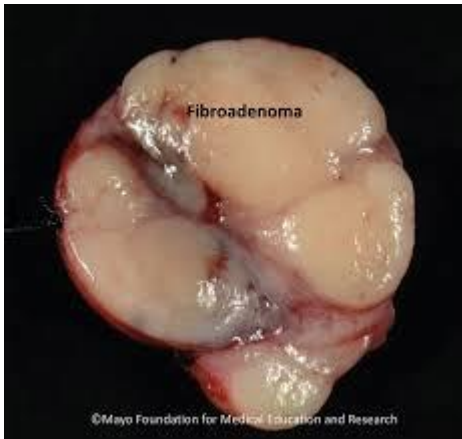iii. There is increased fibrous stroma surrounding the cyst and varying degree of lymphocytic infiltrate



Fibroadenoma

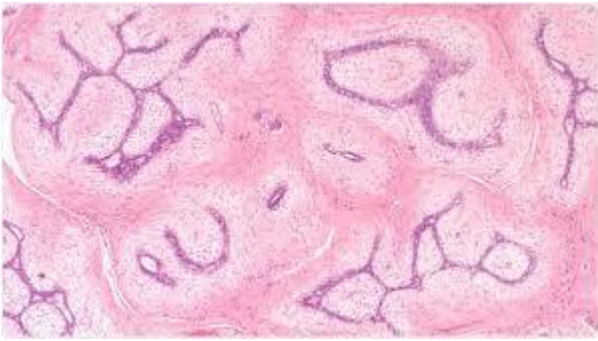Fibroadenoma is a benign tumor of fibrous and epithelial elements of the breast. It is the most common benign tumor of the breast in reproductive life.

G/a: typically fibroadenoma is a small (2-4 cm diameter), solitary, well-encapsulated, spherical or discoid mass. The cut surface is firm, grey-white, and slightly myxoid and may show slitlike spaces. The tumor is encapsulated.



M/e: i. Intracanalicular pattern is one in which the stroma compresses the ducts so that they are reduced to slit-like clefts lined by ductal epithelium and may appear as cords of epithelial elements surrounding masses of fibrous tissue.

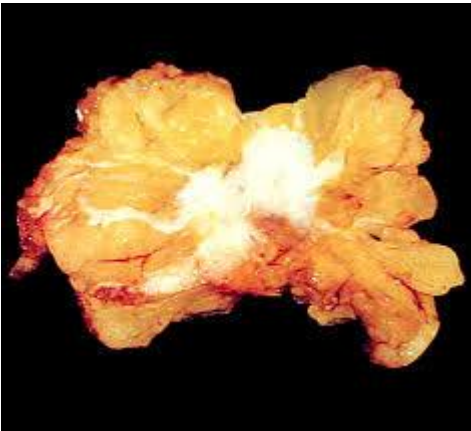
ii. Pericanalicular pattern is characterized by encircling masses of fibrous tissue around the patent or dilated ducts



Infiltrating duct carcinoma-NOS

Infiltrating duct carcinoma–NOS (not otherwise specified) is the classic breast cancer and is the most common histologic pattern accounting for 70% cases of breast cancer.

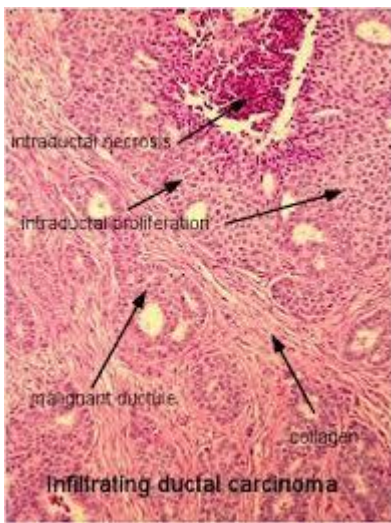
G/a: the tumor is irregular, 1-5 cm in diameter, hard, cartilage-like mass that cuts with a grating sound. Sectioned surface of the tumor is grey-white to yellowish with chalky streaks and often extends irregularly into the surrounding fat.



M/e: i. anaplastic tumor cells form various patterns—solid nests, cords, poorly-formed glandular structures and some intraductal foci.

ii. Infiltration by these patterns of tumor cells into diffuse fibrous stroma and fat.

iii. Invasion by the tumor cells into perivascular and perineural space, besides lymph



Male genital tract:

I. Testes:

- Testicular tumors are most common solid neoplasm among men age <35 years. , they represents about 1-2% of all tumors in men.
- There is marked geographical variation in the incidence of testicular cancer, with the highest incidence among men in European countries and lowest incidence among men in the Middle East and Asia.

Classification of testicular tumors:

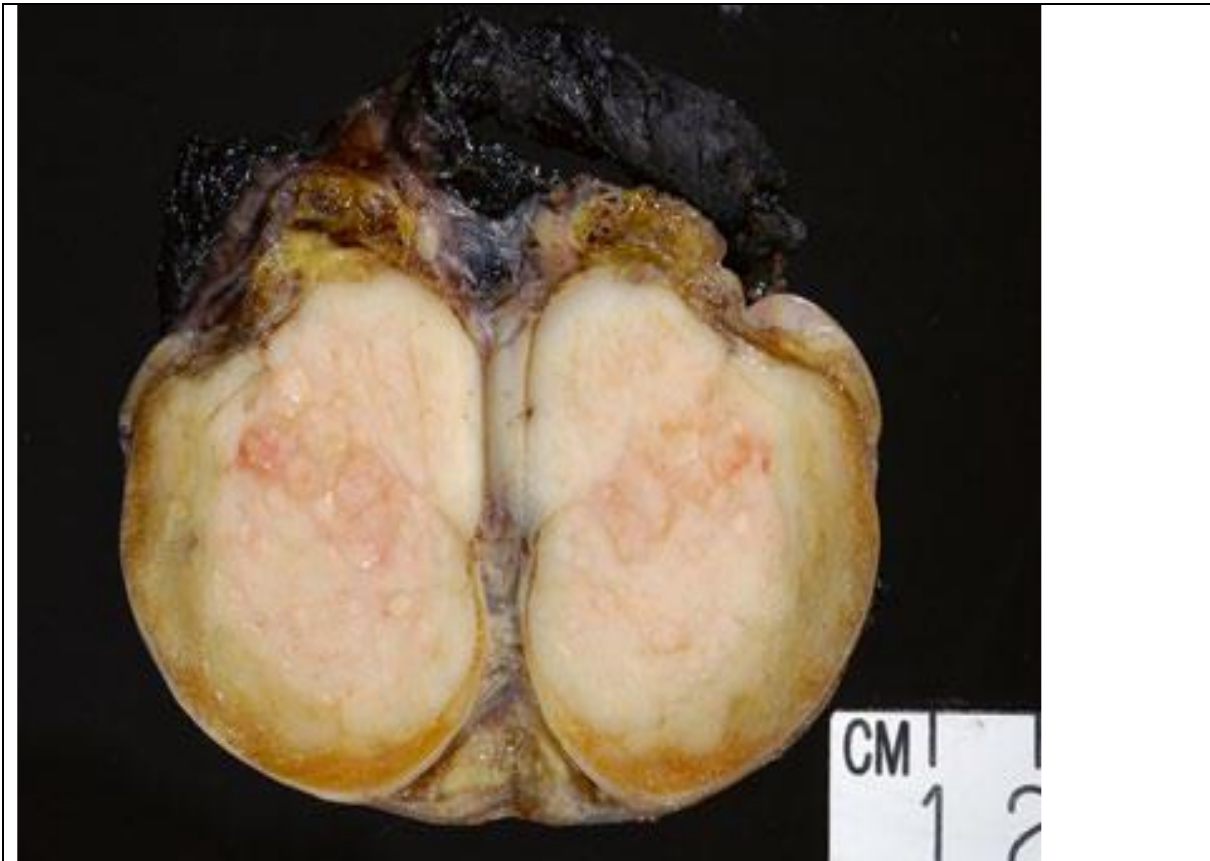Table classification of testicular germ cell tumors

Tumor type	
1- Germ cell tumors	a. Seminoma b. Embryonal carcinoma c. Yolk sac tumor d. Choriocarcinoma e. Teratoma f. Tumors with more than one histological type components)
2- Sex cord/gonadal stromal tumors	a. Leydig cell tumor b. Malignant Leydig cell tumor c. Sertoli cell tumor

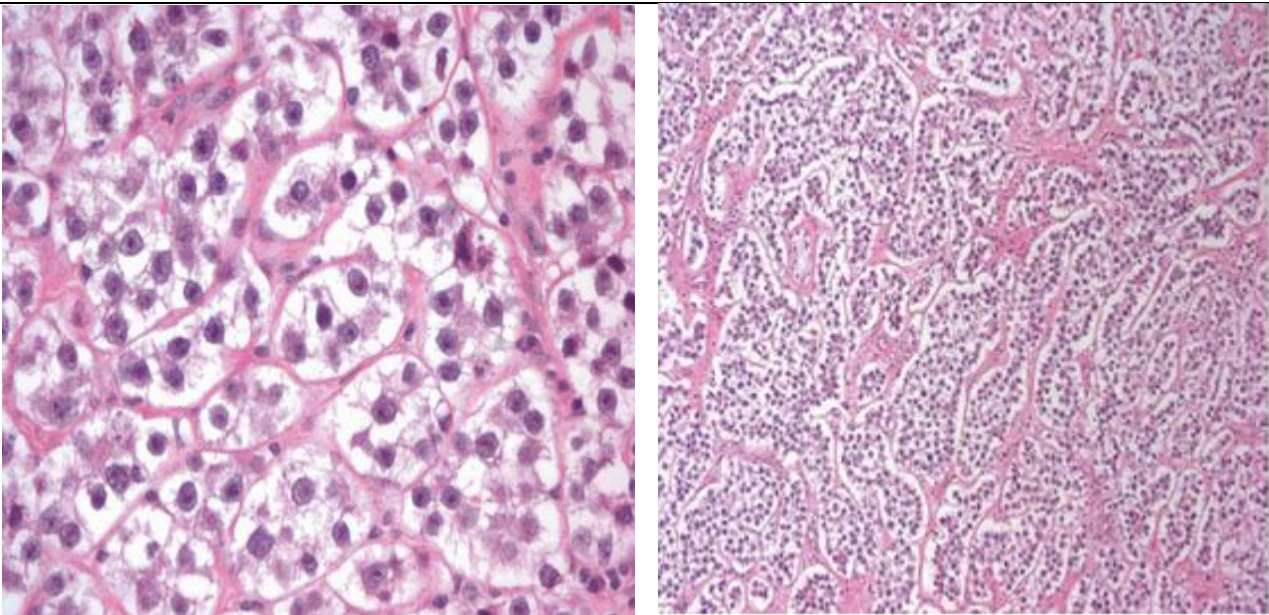
	d. Malignant Sertoli cell tumor
3- Metastatic tumors to the testis	

Seminoma

- Is the most common malignant tumor of the testis, constituting 45% of all testicular germ cell tumors and corresponds to dysgerminoma in the female gonad.



G/a: the involved testis is enlarged. Cut section of the affected testis shows grey-white lobulated appearance.



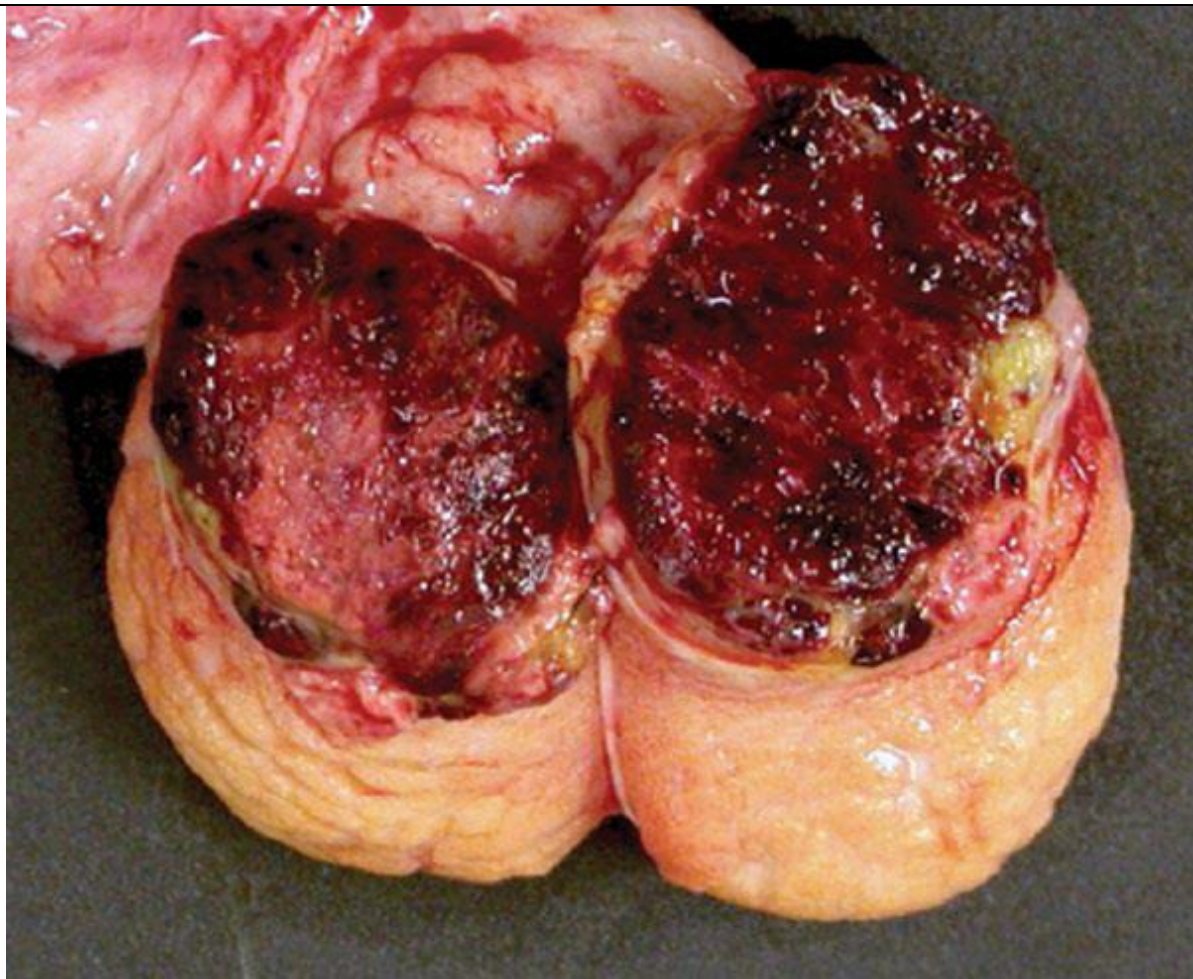
Seminoma:

Rt. Tumor cells are typically uniform in size with clear cytoplasm and well-defined cell borders. The nuclei are central, large, hyperchromatic

Lt. The stroma is delicate fibrous tissue which divides the tumor into lobules. The stroma shows characteristic lymphocytic infiltration.

Choriocarcinoma:

- ▣ Malignant germ cell tumor composed of trophoblastic tissue (syncytiotrophoblast and cytotrophoblast)
- ▣ The trophoblast cells secrete ↑hCG: HCG, which is used as a tumor marker.
- ▣ HCG is similar structurally to TSH, LH and it can result in:
 - Gynecomastia: It stimulates the Leydig cell, increasing testicular estrogen production
 - Hyperthyroidism: TSH stimulates thyroid follicles, increasing production of T3&T4.
- ▣ HCG, acting analogously to LH, causes gynecomastia



Testis replaced by a hemorrhagic nodule of choriocarcinoma.

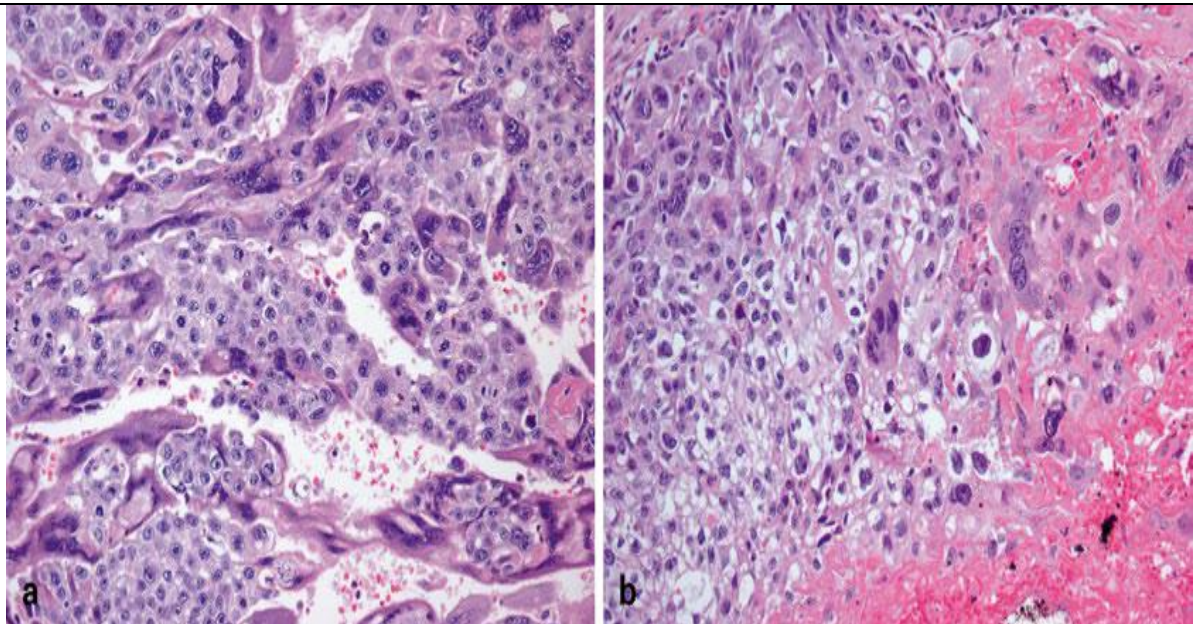


Figure: M/E: Choriocarcinoma composed of an admixture of syncytiotrophoblast,

cytotrophoblast (a), and intermediate trophoblastic cells in a hemorrhagic background (b)

Yolk sac tumors:

- ▣ Malignant germ cell tumor with variable histology, but it forms structures resembling the early yolk sac known as Schiller-Duval bodies.
- ▣ Most common type of testicular tumor in children.
- ▣ Tumors secrete AFP into the serum, which is used as a tumor marker.
- ▣ Prognosis is good in children, and variable in adults.

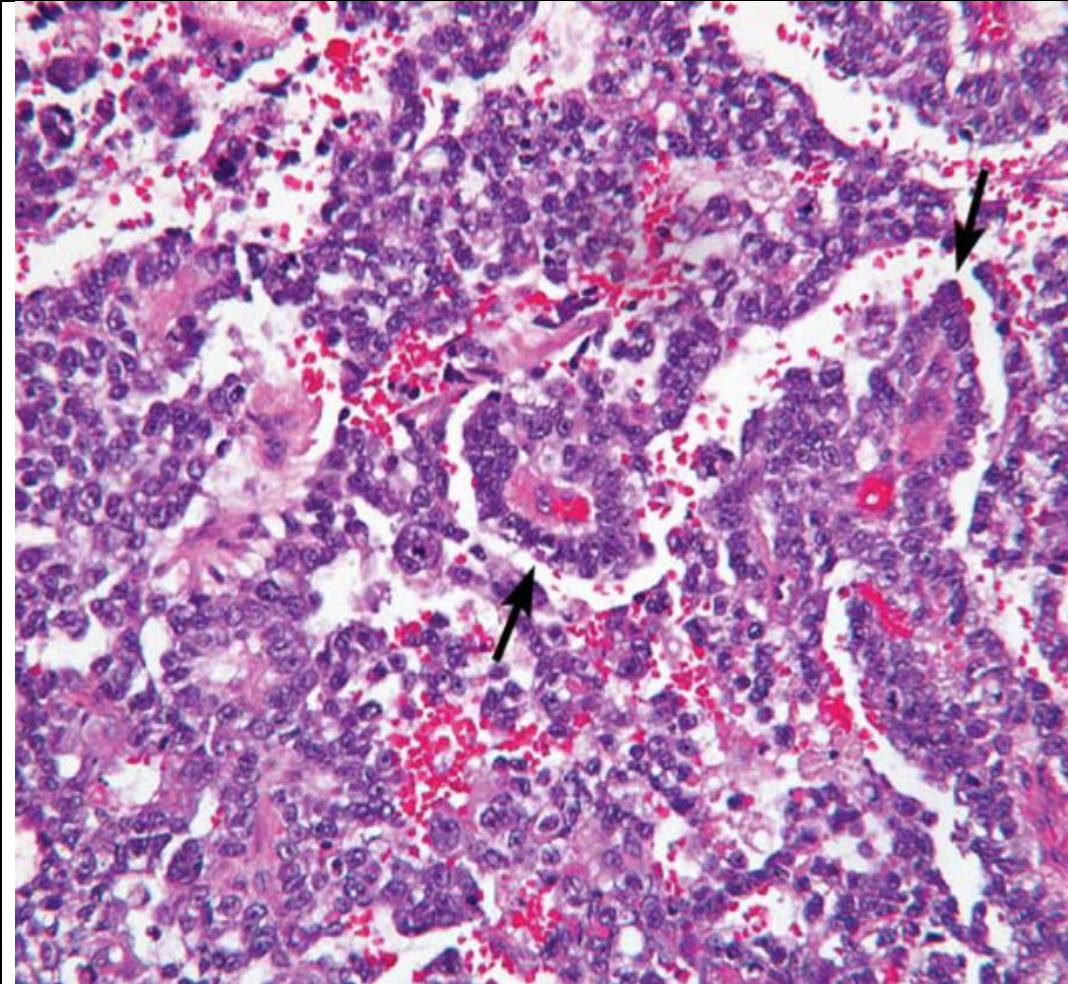


Figure: M/E: yolk sac tumor with Schiller-Duval body (arrow)

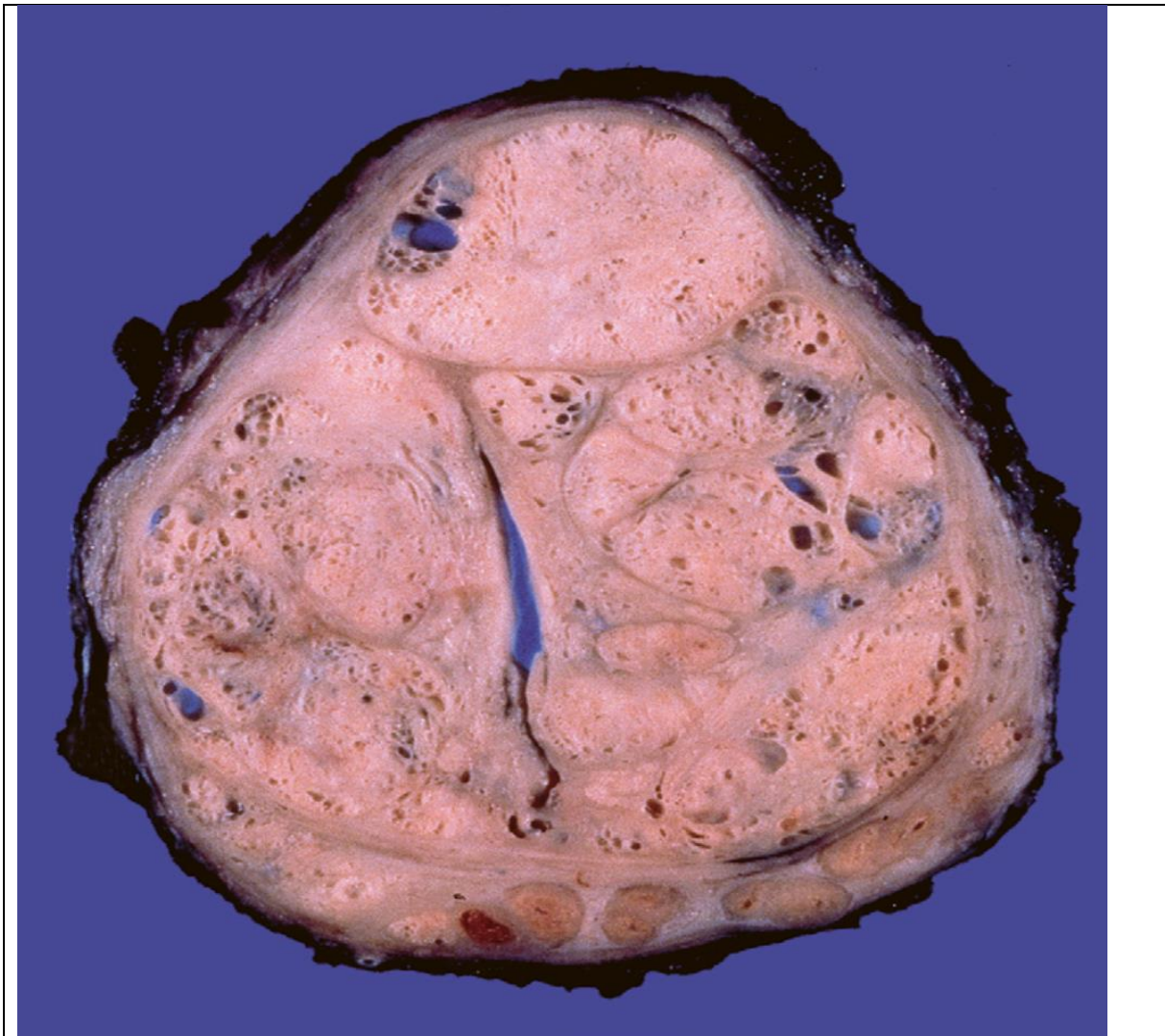
Teratoma:

- ▣ A testicular tumor composed of tissues derived from more than one germ layer.
- ▣ Can occur at any age from infancy to adult life.

- ▣ Pure teratoma is common in infancy and rare in adults.
- ▣ In adult most teratomas are admixed with other germ cell tumors.
- ▣ Before puberty, teratomas are typically benign, but in adults teratomas are malignant.

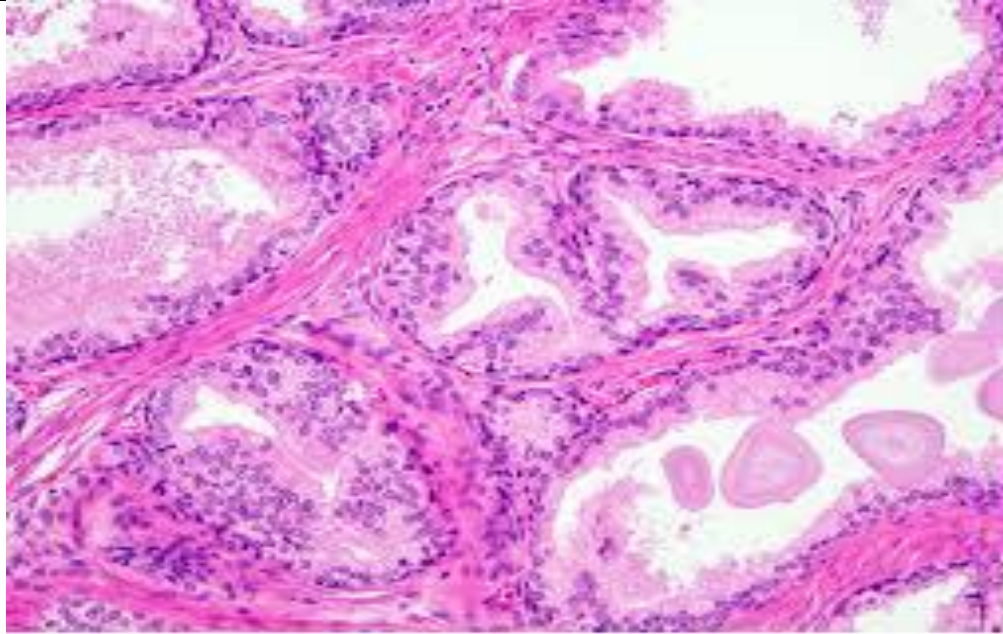
Nodular hyperplasia prostate

- Non-neoplastic tumor-like enlargement of the prostate characterized by hyperplasia of both prostatic stromal and epithelial cells usually in nodular pattern.
- Very common disorder in men above 50 years of age
- Hyperplasia is mainly Peri-urethral.



G/a: the enlarged prostate is nodular, smooth and firm and weighs 2-4 times its normal weight (normal average weight 20 gm). The appearance on cut section shows nodularity having varying admixture of yellowish-pink, soft, honey-combed appearance (glandular

hyperplasia) and firm homogeneous appearance.

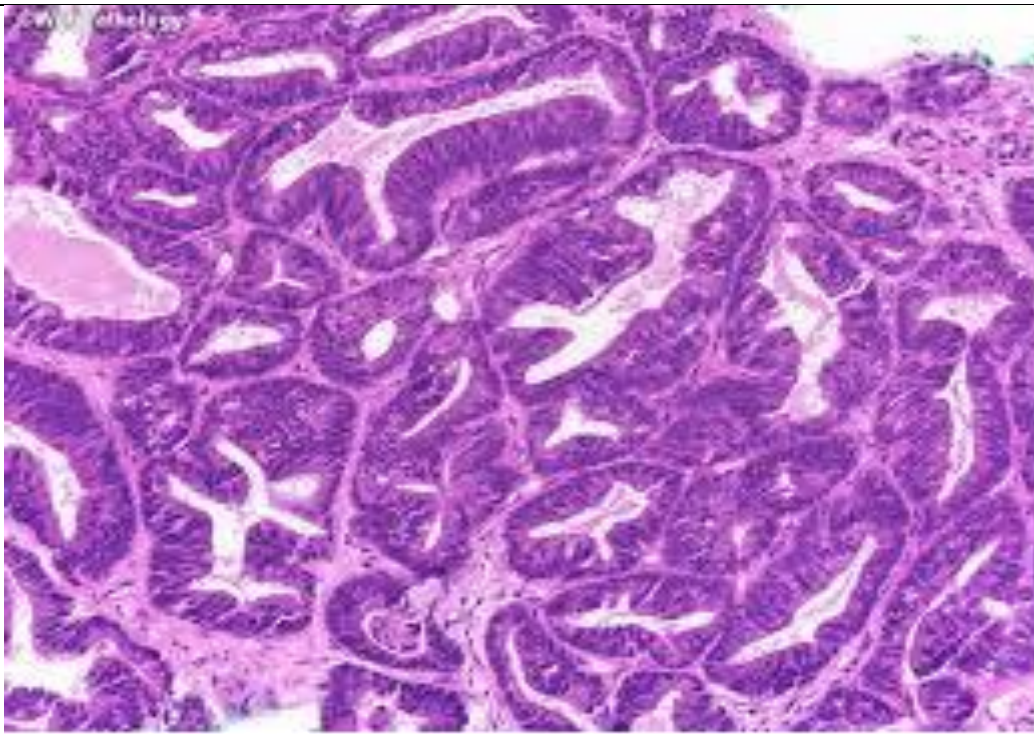


M/e: there is hyperplasia of all three tissue elements in varying proportions—glandular, fibrous and muscular

Adenocarcinoma prostate

Cancer of the prostate is second most common form of cancer in males, next in frequency to lung cancer.

G/a: the prostate is often enlarged, firm and fibrous. Cut section is homogeneous and contains irregular yellowish areas.



M/e: i. Architectural disturbance, acini are either closely packed in back-to-back arrangement, or are haphazardly distributed.

ii. Stroma, malignant acini have little or no stroma between them.

iii. Often the glands are small or medium sized, lined by a single layer of cuboidal or low columnar cells.

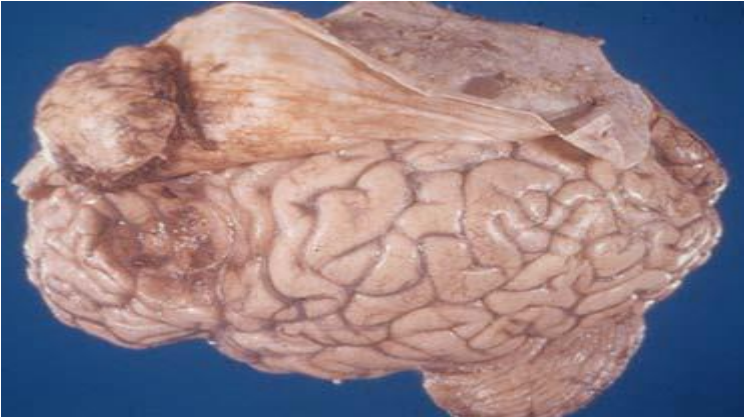
Chapter 9

Central nervous system

Contents:

Learning outcome:

- Identify common disease of nervous system and the pathological changes.



Slide 1a: meningioma

Meningitis

- **Meningitis is an inflammatory process of the leptomeninges and CSF within the subarachnoid space.**

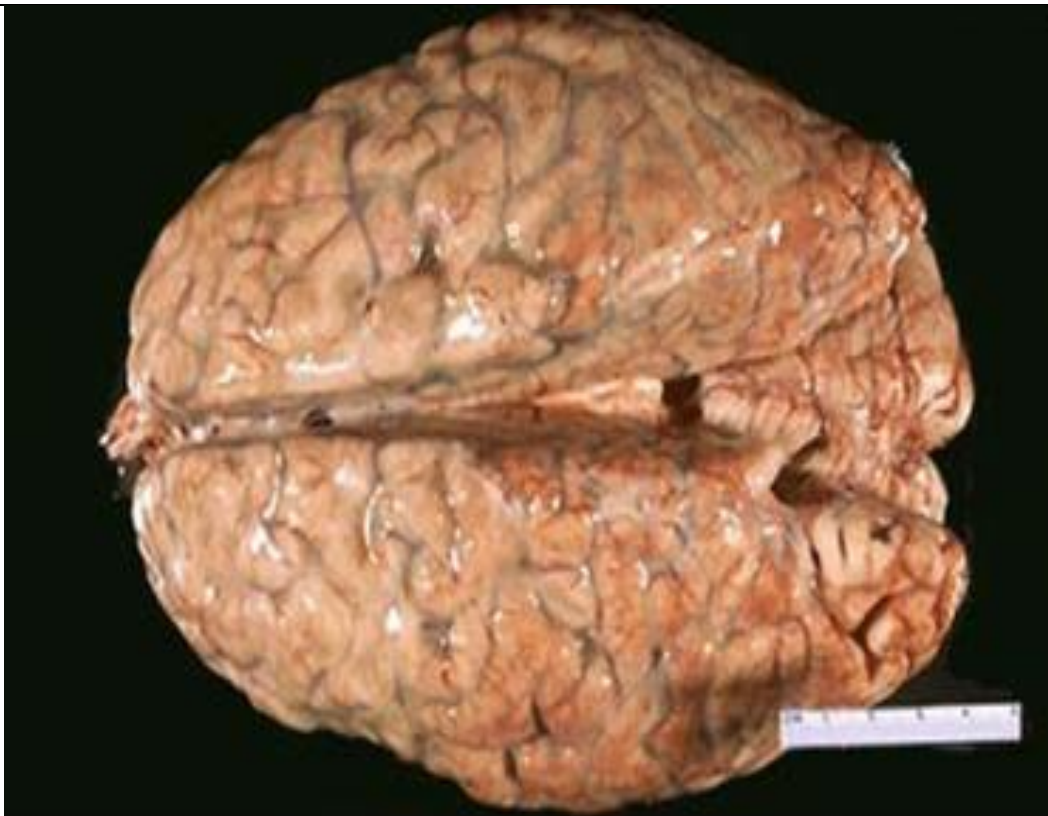Causes:

A. Infectious meningitis:

- Acute :
 - Pyogenic (usually bacterial).
 - Aseptic (usually viral).
- Chronic :
 - Tuberculous,
 - syphilitic
 - Cryptococcal.

B. Chemical meningitis:

- Due to a nonbacterial irritant introduced into the subarachnoid space.



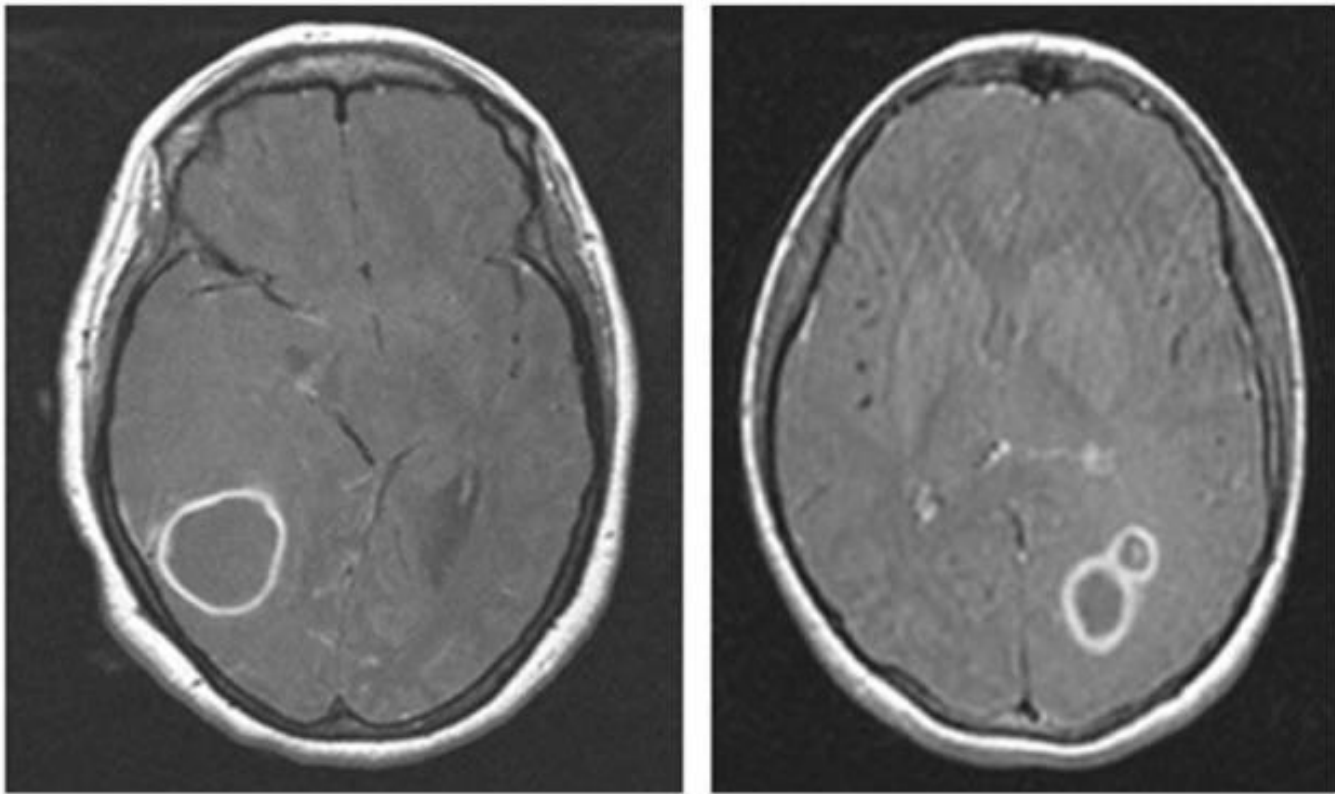
Slide 2: **Pyogenic meningitis**, post mortem exam of brain. Note the brain is edematous and covered by thin layer of exudate.

Complications of meningitis:

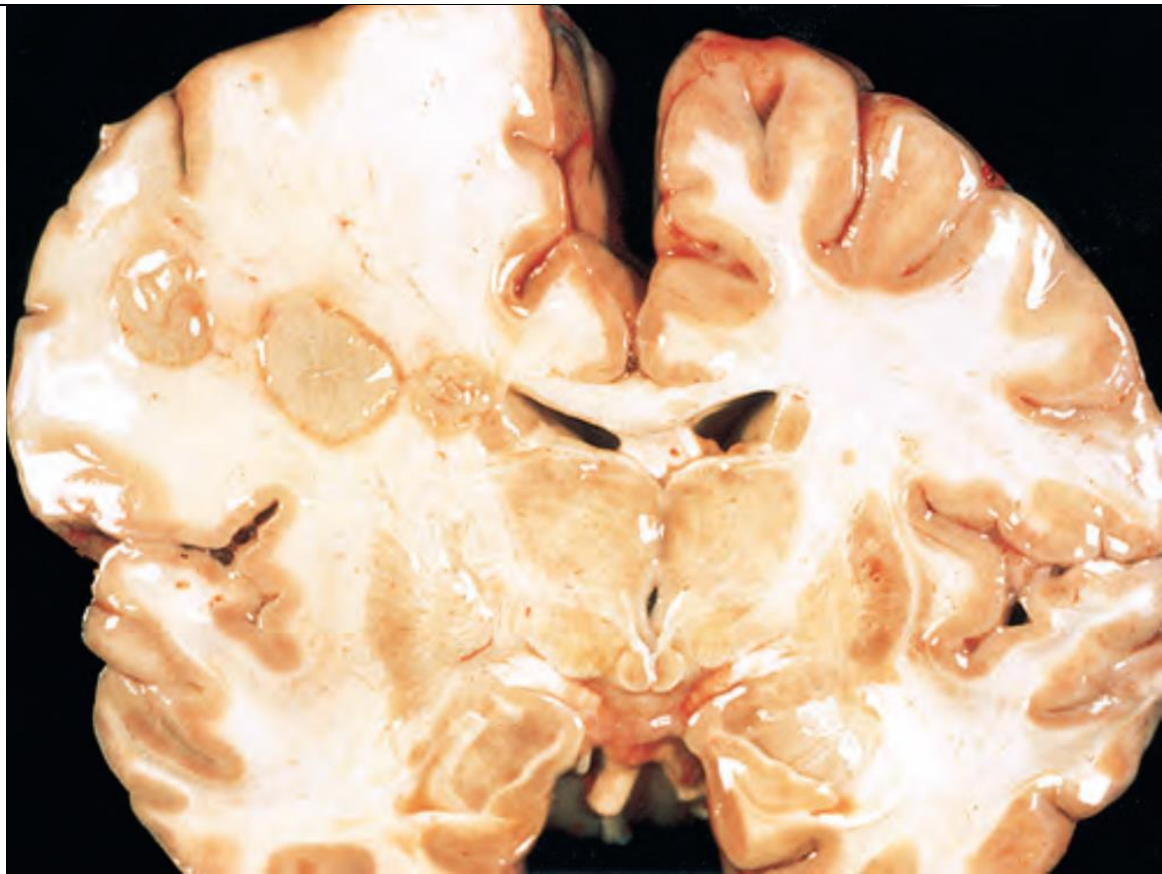
1. **Hydrocephalus.**
2. **Thrombophlebitis of leptomenigeal veins** □ **Venous thrombosis** □ **Cerebral infarction.**
3. **Focal infection of the underlying brain parenchyma & Cerebral abscess**
4. **Epilepsy.**
5. **Permanent neurological deficit.**
6. **Waterhouse-Friderichsen syndrome:**
 - It occurs most often with meningococcal and pneumococcal meningitis.
 - It results from meningitis-associated septicemia this will result in hypotension + DIC and cutaneous petechiae in addition to hemorrhagic infarction of the adrenal glands (adrenal insufficiency) and multi- organ failure.

Brain abscess

- A localized focus of necrosis of brain tissue with accompanying inflammation, usually caused by a bacterial infection.
- Brain abscesses are destructive lesions and patients often present with progressive focal neurologic deficits;



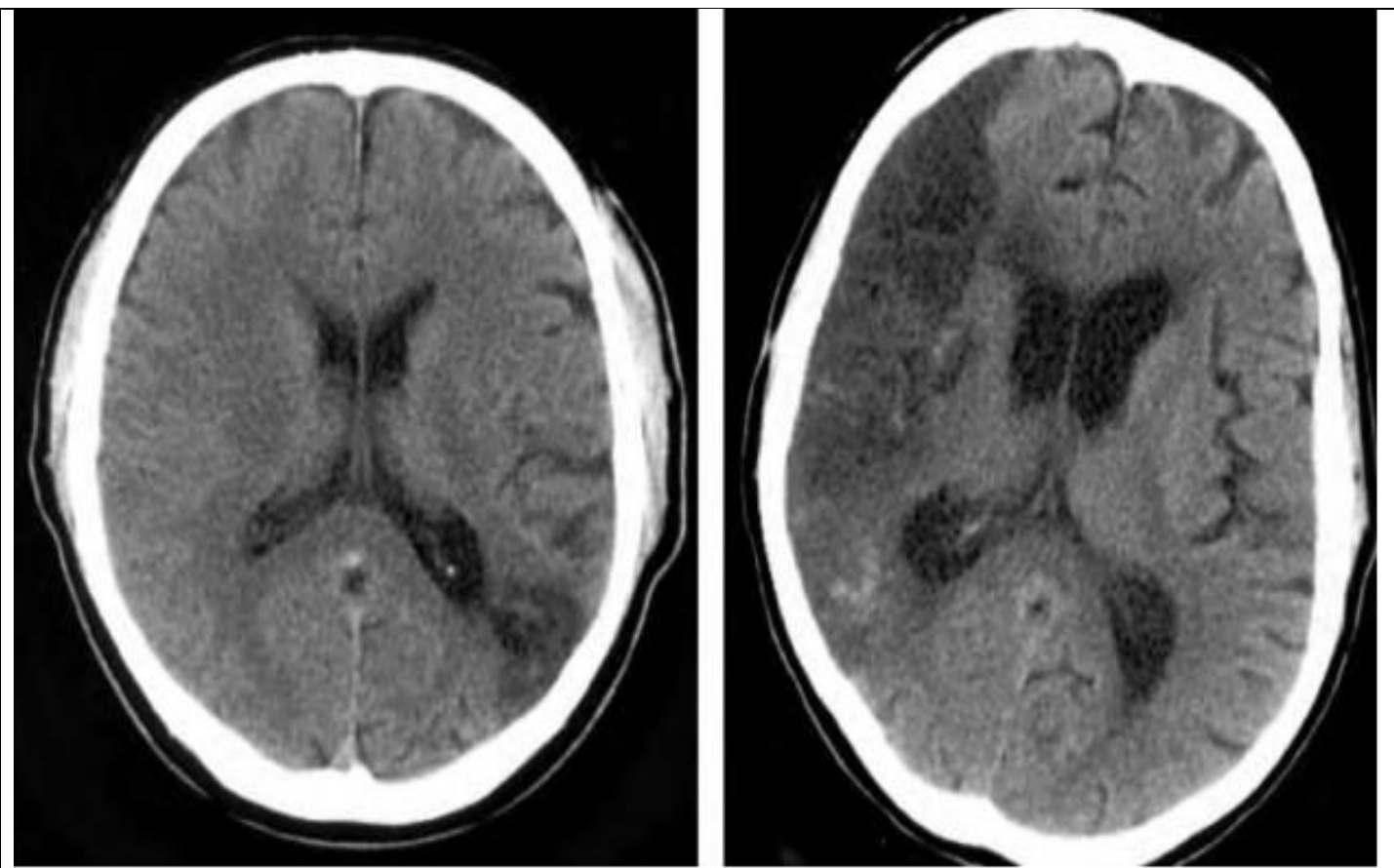
Slide 3a: CT with contrast of brain abscess, note the ring enhancement



Slide 3b: brain abscess

Stroke:

- It is sudden onset cerebrovascular disease that cause neurologic damage due to focal ischemia or hemorrhage.

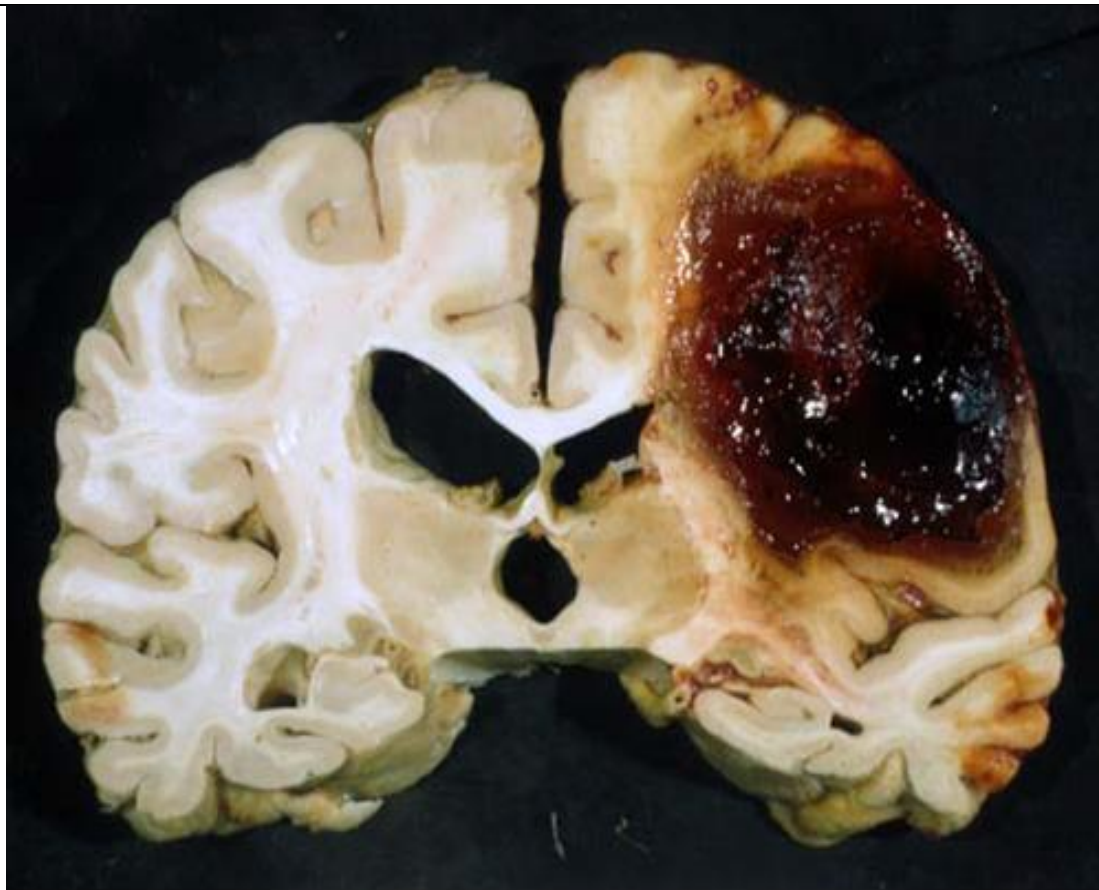


Slide 4: ischemic stroke

Intra cranial hemorrhage:

1- Intra parenchymal hemorrhage:

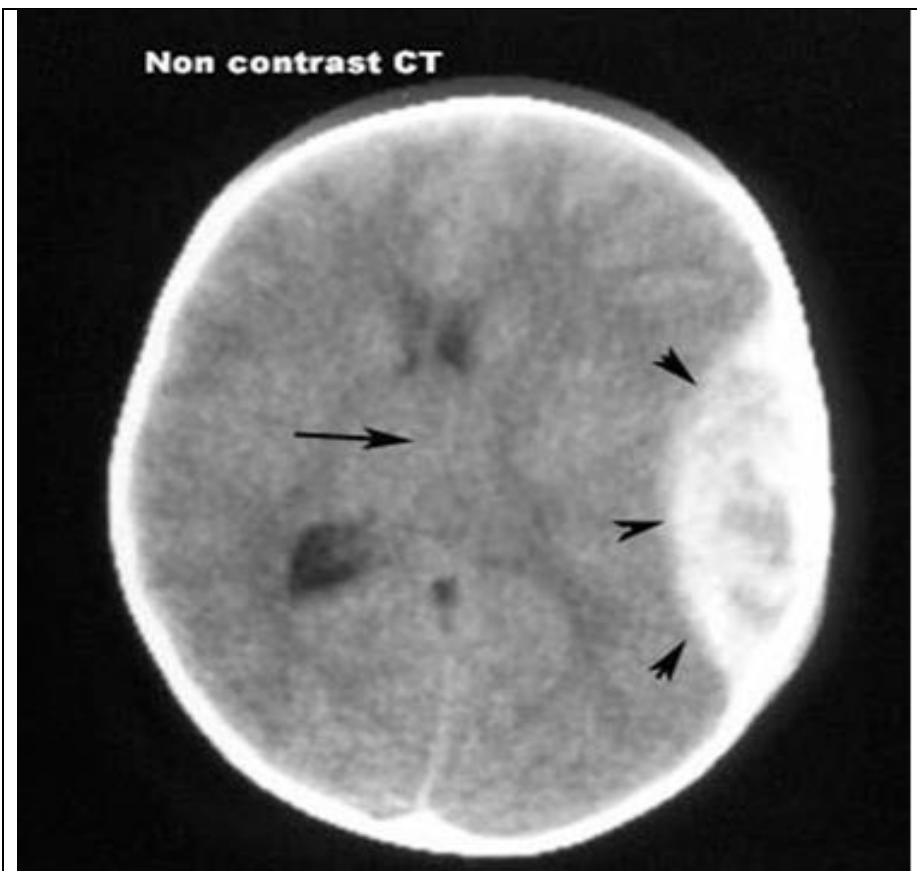
- Hemorrhage within the brain parenchyma.
- Occur in middle to late adult life (peak during 60 years of age).
- Clinical manifestation and the outcome depends on the size and location of hemorrhage.
- hematoma acts as a space-occupying lesion, causing increase in intracranial pressure if large intracranial herniation.



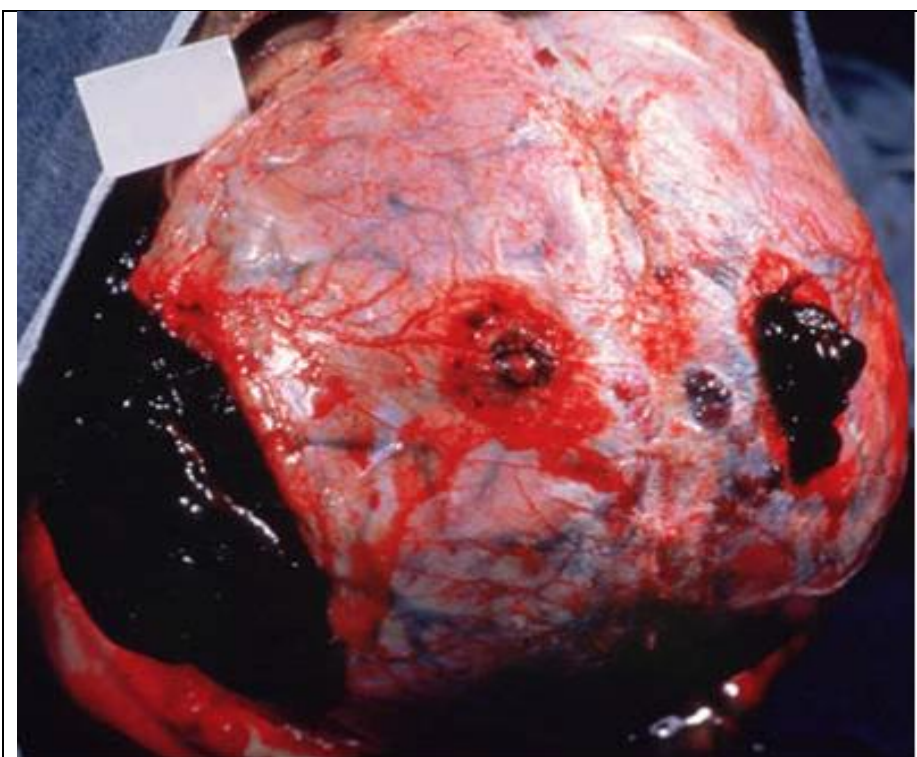
Slide 5: fatal hemorrhagic stroke

Epidural hemorrhage:

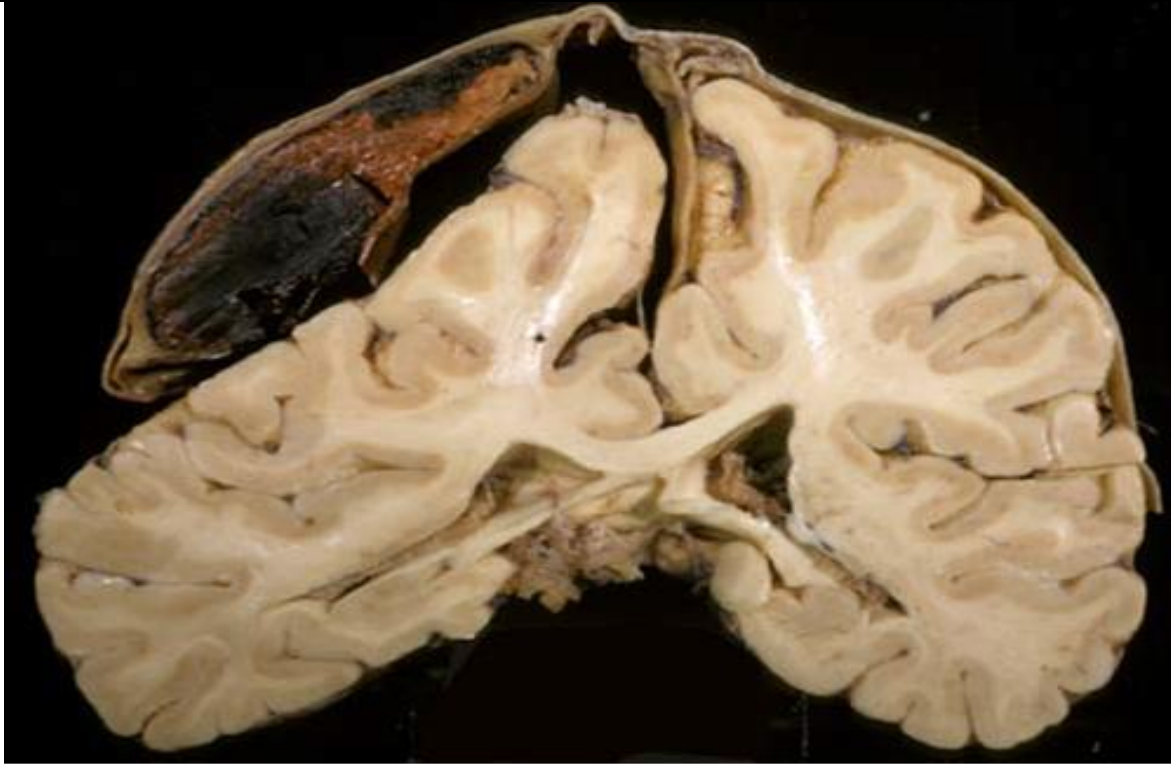- Accumulation of blood between skull bone and the dura matter.
- Usually results from direct trauma to skull with fracture of bones.
- Trauma will result in lacerations to branches of middle meningeal artery, blood will accumulate in extradural space, patients usually present with symptoms of space occupying lesion.
- It is progressive fatal condition unless diagnosed and treated early.



Slide 7: CT scan of brain showing epidural hematoma. Note the lens shape appearance.



Slide 8: Gross appearance of epidural hematoma



Slide 9: subdural hematoma

Sub arachnoid hemorrhage:

Accumulation of blood in the subarachnoid space, i.e. between the inner surface of the arachnoid and brain.

Causes:

4. Trauma.
5. Rupture of a saccular (berry) aneurysm.
6. Rupture of a hypertensive intracerebral hemorrhage into the ventricular system.
7. Hematologic disorders.
8. Vascular malformation
9. Tumors.

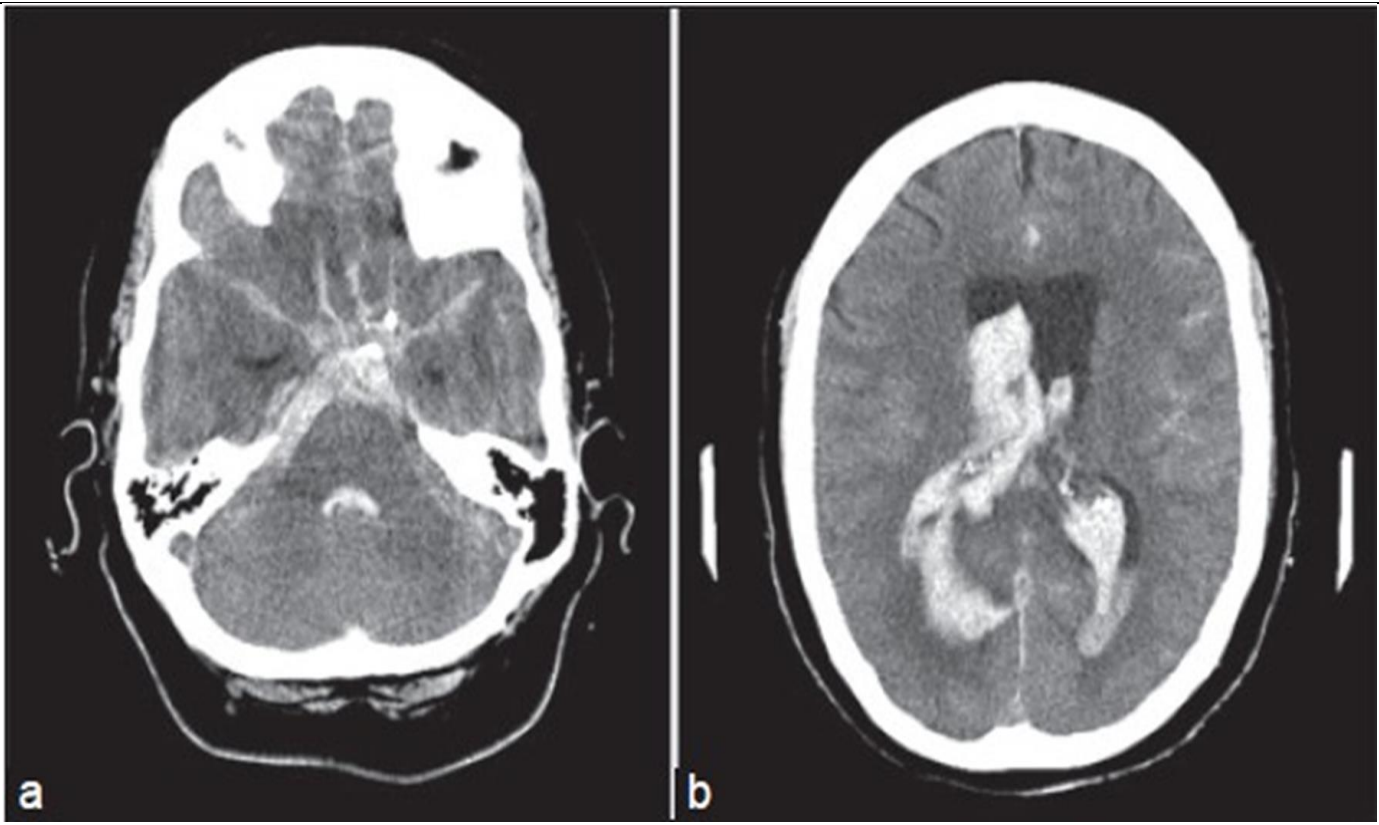
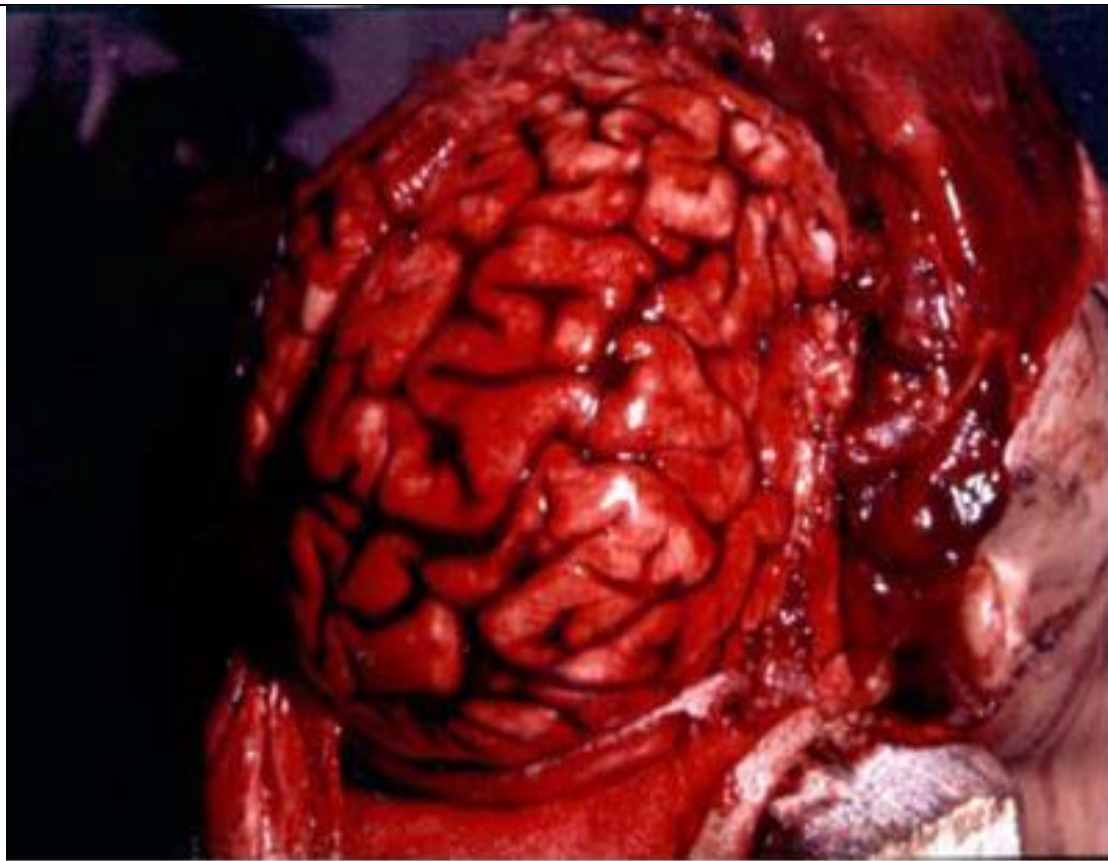


Figure: sub arachnoid hemorrhage, note the blood within the ventricles (b).



Slide 6: Gross appearance of subarachnoid hemorrhage

Hydrocephalous:

- Hydrocephalus is an abnormal increase in the intracranial volume of CSF associated with dilatation of all or some portion of the ventricular system.
- It occurs secondary to a dys-equilibrium between CSF formation and reabsorption.

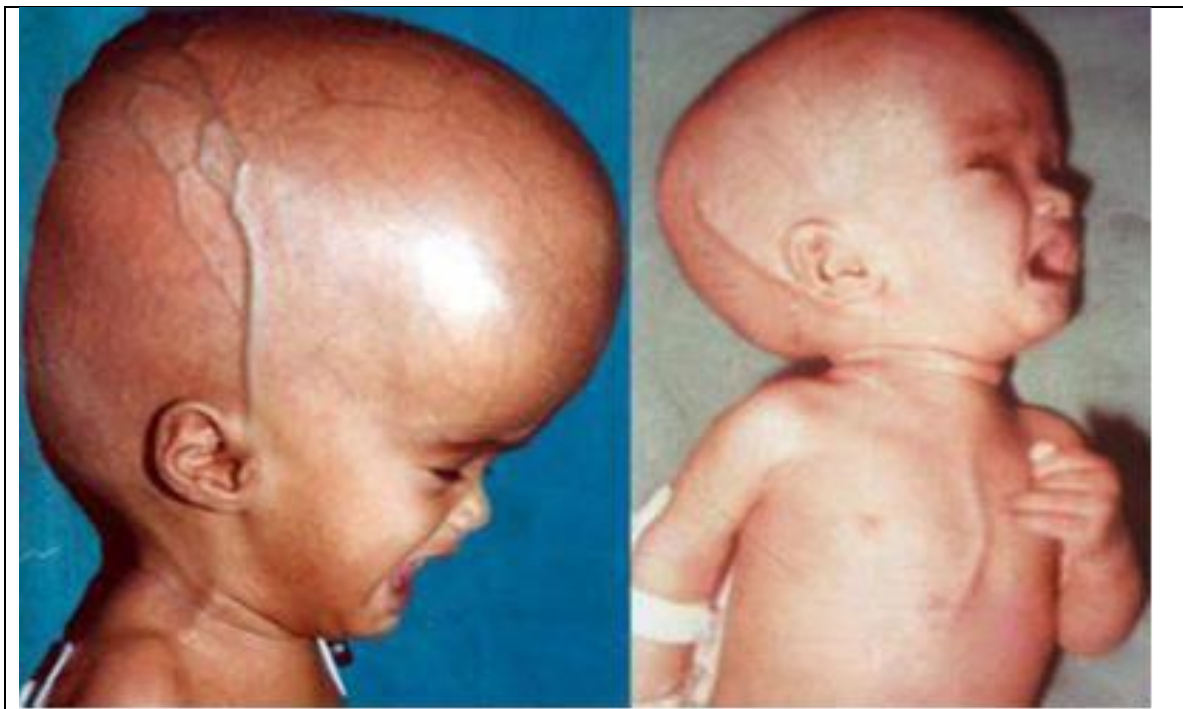Causes of hydrocephalus:

1- Obstruction to CSF circulation:

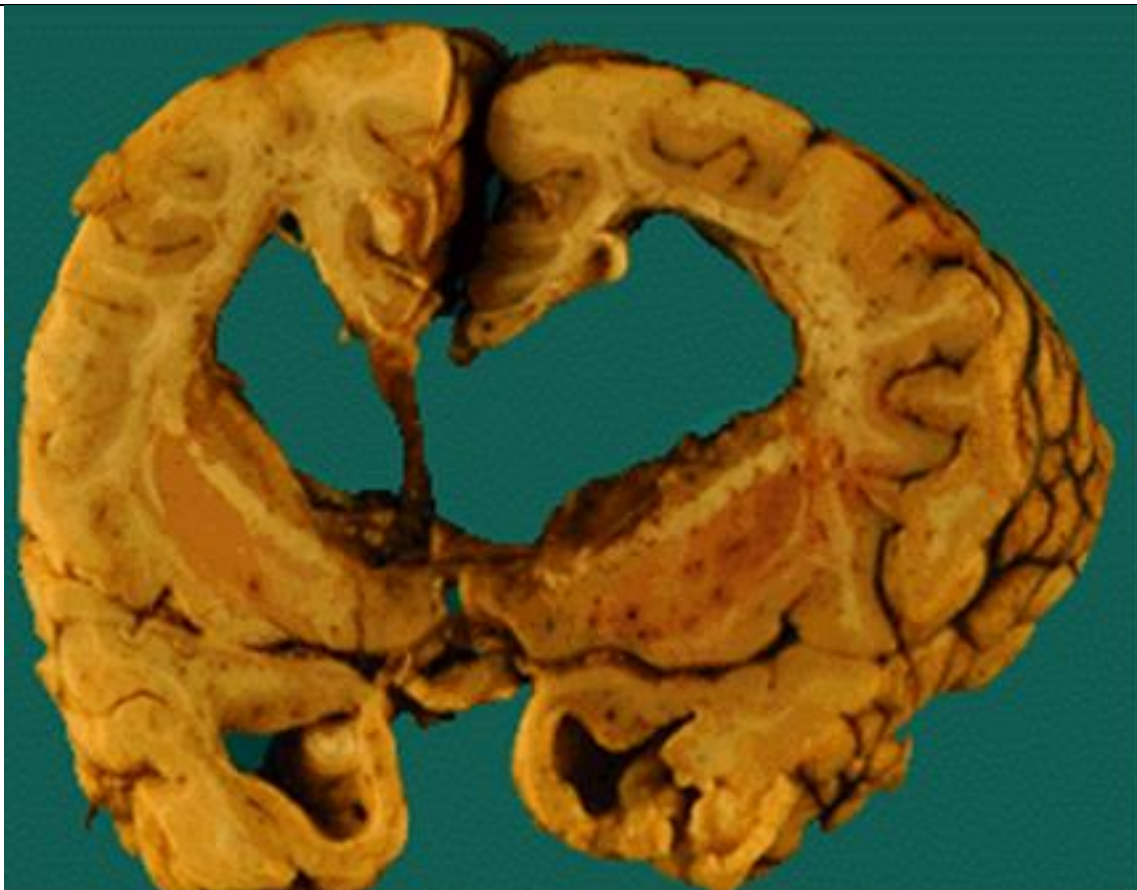
- It is the most common type.
- Obstruction to CSF circulation may occur within the ventricles or within the subarachnoid space.
- If the obstruction is within the ventricles, the hydrocephalus is non- communicating; that is, the ventricles do not communicate with the subarachnoid space.
- If the obstruction is within the subarachnoid space, the hydrocephalus is communicating.
- Common causes of obstructive hydrocephalus are congenital malformations and acquired pathologic lesions.

2- Overproduction of CSF: (e.g., choroid plexus papilloma).

3- Failure of CSF absorption at the arachnoid granulations.



Slide 10: hydrocephalus



Slide 11: hydrocephalus

Brain tumors:

- Primary brain tumors are those tumor that arise from cells that are intrinsic to CNS or its coverings.

Gliomas:

- The most common group of primary brain tumors.
 - 40-45% of brain tumors.
 - The tumors are classified histologically on the resemblance of cells to glial cells.
- Major tumors includes:
 - I. Astrocytomas: Astrocytoma is a glioma that show astrocytes differentiation.
 - II. Oligodendrogliomas.
 - III. Ependymomas.

Astrocytomas:

Most common glioma, it is classified in to two major categories

1. Pilocytic astrocytomas.

2. Diffuse astrocytoma:

- Diffuse infiltration of brain tissue.
- It includes:
 - a. Well-differentiated astrocytoma (WHO grade II)
 - b. Anaplastic astrocytoma (WHO grade III)
 - c. Glioblastoma (WHO grade IV).

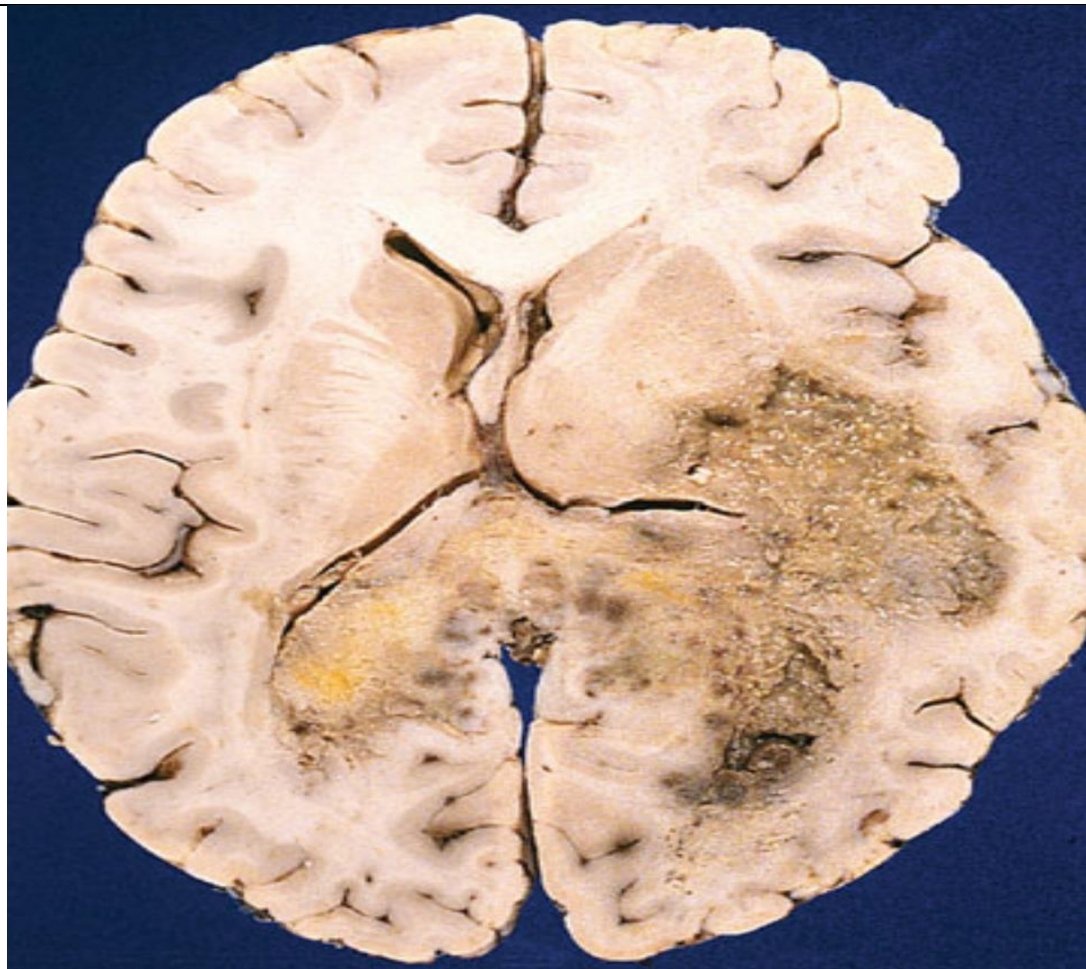


Figure G/A: glioblastoma multiforme, consistency and color varies. () Some areas are firm and white, others are soft and yellow due to necrosis or red due to hemorrhage. Show cystic degeneration.

Meningioma

- Arise from the pia-arachnoid tissue.
- The most frequent sites are in the front half of the head—lateral cerebral convexities, midline along the falx cerebri adjacent to the major venous sinuses parasagittally.



- G/a meningioma is well circumscribed, solid, spherical or hemispherical mass of variable size (1 to 10 cm in diameter). The tumor is generally firmly attached to the dura while the
- overlying bone may show hyperostosis.